



Contents lists available at ScienceDirect

## Asian Pacific Journal of Tropical Biomedicine

journal homepage: www.elsevier.com/locate/apjtb



Document heading doi:10.1016/S2221-1691(11)60110-X © 2011 by the Asian Pacific Journal of Tropical Biomedicine. All rights reserved.

# A clinical report of entangled neonates' umbilical cord with queen's fur in Persian cat

O Azari\*, B Akhtardanesh

Department of Clinical Sciences, Faculty of Veterinary Medicine, Shahid Bahonar University, Kerman, Iran

## ARTICLE INFO

## Article history:

Received 4 April 2011  
 Received in revised form 24 April 2011  
 Accepted 7 May 2011  
 Available online 20 May 2011

## Keywords:

Persian cat  
 Neonate  
 Umbilical cord  
 Queen's fur

## ABSTRACT

A 3-year-old Persian queen was referred to Teaching Veterinary Hospital while 3 neonates' umbilical cords were entangled with the queen's tail hair. Close inspection of the cat showed that the umbilical cords of 3 kittens had twisted around together and entangled with the mom's hairs in the base of tail region. Also this complex has been warped around the left tarsus of one of the involved kittens and caused swelling and skin darkness in the involved limb. Operation was carried out urgently. After cutting the queen's involved hairs the kittens were released. Then the twisted umbilical cords and the hairs were isolated from the umbilical cord and the involved leg was released from the umbilical cords and the twisted umbilical cords were separated from each other. During one week follow up, dry gangrene occurred in the distal extremity of the injured limb and consequently, amputation was performed on the distal part of tibia. Our clinical findings suggest that long hair coats of queens could be a maternal life threatening factor for neonates' life.

## 1. Introduction

Review literature showed that parturition problems are rare in cats and most queens will kitten with no difficulties and without any need for intervention. Expulsion of the kitten is usually rapid, with only a short interval between each birth, and parturition is usually completed within a few hours<sup>[1]</sup>. Normally the bitch or queen will break the membrane, lick the neonate intensively and sever the umbilical cord. Occasionally during delivery, the kittens come so fast and queen can't keep up with severing the umbilical cords and the kittens become entangled. Incidence of dystocia, or abnormal queening, is reported as 3% to 6% but with progression of selective breeding these problems are becoming more common<sup>[2]</sup>. Dystocia is most commonly seen in cats with extremes of head shape, particularly in Persian and Siamese cats. Persian kittens tend to be very large and have sizable heads that make delivery more difficult<sup>[3]</sup>. Related to this, the highest levels of kitten mortality are typically seen in Persian cats<sup>[3–5]</sup>. Stillborn kittens have been reported to account for

approximately 7%–10% of all cases of kitten mortality<sup>[6,7]</sup>. However, although the cat has a complete normal partition, there are still several post kittening problems which may affect the neonate<sup>[8,9]</sup>. It is estimated that 91% of the deaths occur within the first 3 days after birth<sup>[10]</sup>.

The Persian is perhaps the oldest recognized cat breed and has undergone selection for an extreme phenotype, which is likely involved in complex gene interaction. The early Persian cat may have in fact originated from ancient Persia<sup>[11]</sup>. Persian cats are a favorite breed in Iran and all around the world due to their beautiful long hair and docile temperament. Most Persians are healthy cats. However, they have several health risks<sup>[12,13]</sup>. Due to large, protruding eyes, they are susceptible to eye infections and corneal injuries and flat nature of their faces. Sometimes they are confronted with breathing problems or problems with clogged tear ducts. It seems that a brachycephalic facial conformation of Persian cats may be an important risk factor for the development of sino-nasal aspergillosis<sup>[14]</sup>. Furthermore, dental malocclusion and deafness in white Persians are reported commonly in this breed<sup>[15]</sup>. Long hair coat increase the incidence of hair ball formation in digestive system and Persian cats could be considered as major predisposing factor for skin diseases<sup>[12]</sup> such as dermatophytic mycetoma<sup>[16]</sup> and pseudomycetoma<sup>[17,18]</sup>, *Microsporum canis* dermatophytosis<sup>[19]</sup>, and some allergic skin diseases<sup>[20]</sup>.

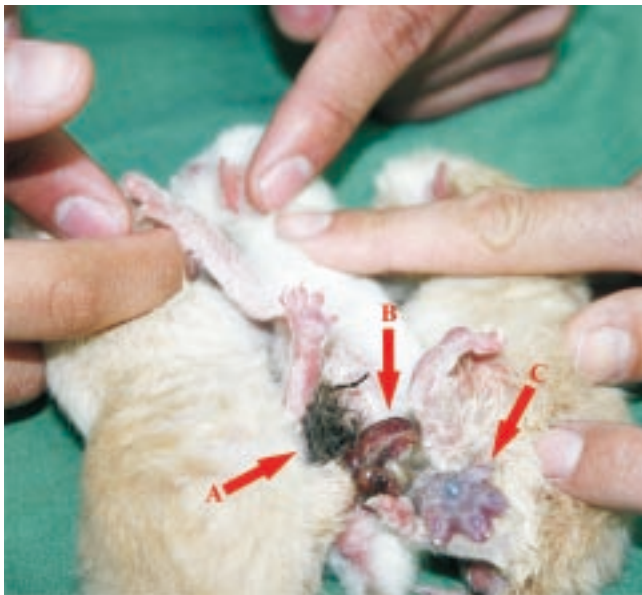\*Corresponding author: Omid Azari, Department of Clinical Sciences, Faculty of Veterinary Medicine, Shahid Bahonar University, Kerman, Iran.  
 E-mail: omidazari@mail.uk.ac.ir

Persian cats are predisposed to chronic and recurrent dermatophytosis, possibly due to ineffective grooming, the cutaneous microenvironment or immunological deficits[21]. Some non-infectious disorders such as polycystic kidney disease (PKD) and progressive retinal atrophy (PRA) are commonly reported in Persian cats[22, 23].

However, to the authors' knowledge, there is no documented data in the current veterinary literatures considering that long hair of Persian or other breeds can threaten the newborns lives. This article describes an interesting case of prenatal problem in a Persian kitten which is directly related to the long thick hair coat of this breed.

## 2. Case report

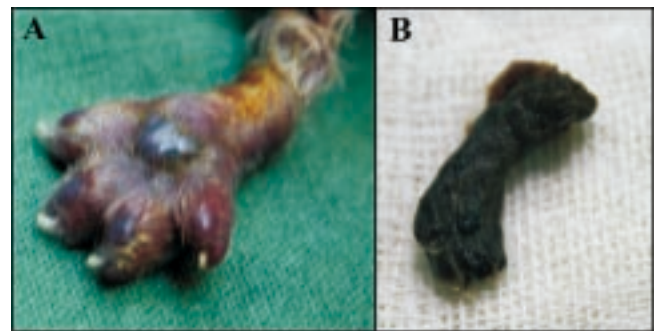
A 3-year old Persian queen was referred to Teaching Veterinary Hospital of Shahaid Bahaonar University of Kerman while 3 neonates' umbilical cords being entangled with the queen's tail hair. The queen had a normal parturition and delivered 4 neonates, 12 hours before the referring. Close inspection of the cat showed that the umbilical cord of 3 kittens have twisted around together and entangled with the moms' hairs in the base of tail region. Also this complex has been warped around the left tarsus of one of the involved kittens. Because of vascular obstruction in distal extremity of the involved hind limb, swelling and skin darkness were obvious (Figure 1 and 2A). In clinical examination, the queen and all kittens were alert and had normal clinical findings except the kitten with injured leg who was depressed.



**Figure 1.** The moms' hairs entangled with umbilical cord of 3 kittens. A: Umbilical cords twisted around together; B: This complex haing been warped around the left tarsus of one of the involved kittens; C: Soft tissue swelling and edema observed in distal limb.

The animals were referred to surgery ward urgently. At first, the queen's hairs that involved with the umbilical

cords were cut and the kittens were released from the queen's tail. Then the twisted umbilical cords were lavaged with 1% iodine solution and the hairs were isolated from the umbilical cord and after that the involved leg were released from the umbilical cords and the twisted umbilical cords were separated from each other. Finally, the umbilical cords of each neonate were tied off with vicryl 4/0 tightly. Amoxicillin clavulanic acid 15 mg/kg (Co-amoxyclav suspension, 312 mg, Kosar Co. Iran) and dexametason 0.1 mg/kg (Tab, 0.5 mg, Daroo-pakhsh. Co. Iran) were prescribed twice daily for the affected kitten. On the other hand, physiotherapy and daily massage of the injured leg with warm water were advised to the owner.



**Figure 2.** Distal extremity of involved hind limbs.

A: The limb just after being released; B: The amputated limb because of dry gangrene.

Unfortunately, during one week follow up, the recommended medications could not recover the injured tissue and gradually dry gangrene occurred in the distal extremity of the limb and consequently, amputation was performed on the distal part of tibia (Figure 2B). The owner reported no considerable post-surgical complications, and the animal continued to recover well during two weeks follow-up.

## 3. Discussion

The frequency of kitten death in the neonatal period is very high in catteries[24]. Fading kitten syndrome includes noninfectious and infectious causes for neonatal death and rates differ in different breeding systems[4,25]. Typical time periods of losses are at birth (still birth), and perinatal period. Perinatal death in the first two weeks is generally associated with neonatal isoerythrolysis (NI) emaciation and low birth weight, congenital abnormalities, hypoglycemia, hypothermia, ambient factors, maternal neglect, and neonatal infections[24,26,27]. The rate of stillbirths in cats ranges from 4.7% to 11.2%. Mortality rate is highest in the first 7 days of life, averaging 27.3% and predisposed breeds include Persians, Manx, and Himalayans[4].

The long and silky fur of Persian cats is one of its most attractive features in this breed. Persians have a double coat which is thick and plush near the skin. This thick layer of fur is covered by lighter, silky fur. A Persian's outer coat can be 6 to 8 inches (15 to 20 centimeters) long. Persian's fur

sometimes will clump together in a mat<sup>[12]</sup>. Though Persians are highly sought for their beauty, they suffer from some health issues related to the long silky double layered coat such as stomach's hair balls and skin problems<sup>[15]</sup>.

Extremely delicate skin of Persian cat is predisposed to several skin problems such as primary seborrhea, dermatophytosis and idiopathic facial dermatitis<sup>[28]</sup>. Scott *et al* reported that Himalayan and Persian cats accounted for 75% of cases of dermatophytosis seen at the University Clinic in Canada<sup>[29]</sup>.

There are several mother related factors for neonatal death including uterine inertia, inadequate size of the birth canal, queen obesity, abnormality of the pregnancy and savaging by the dam<sup>[4,10]</sup>. But there is no report in veterinary literatures that have introduced the long hair of the queen as a maternal life threatening factor for the neonates. Our clinical findings suggest that long hair coats of queens could be a maternal life threatening factor for neonates' life.

In conclusion, regular grooming of long haired cats is not only recommended to avoid tangled and matted fur and the skin problems but also is highly recommended in pregnant long-hair queens especially before the commencement of the parturition.

### Conflict of interest statement

We declare that we have no conflict of interest.

### References

- [1] Noakes DE, Parkinson TJ, England GCW. *Arthur's veterinary reproduction and obstetrics*. 8th ed. England: Sunders; 2008, p. 182.
- [2] England G, Heimendahl VA. *Manual of small animal reproduction and neonatology*. 2nd ed. Cheltenham: British Small Animal Veterinary Association; 2010, p. 127–142.
- [3] Gunn–Moore DA, Thrusfield MV. Feline dystocia: prevalence, and association with cranial conformation and breed. *Vet Rec* 1995; **136**: 350–353.
- [4] Root–Kustritz MV. *Clinical canine and feline reproduction: evidence–based answers*. USA: Willey–Blackwell; 2010, p. 239–240, 293, 305.
- [5] Ekstrand C, Linde–Forsberg C. Dystocia in the cat: a retrospective study of 155 cases. *J Small Anim Pract* 1994; **35**: 459–464.
- [6] Scott FW, Peltz R. Kitten mortality survey. *Feline Pract* 1978; **8**: 31–34.
- [7] Sparkes AH, Rogers K, Henley WE, Gunn–Moore DA, May JM, Gruffydd–Jones TJ, et al. A questionnaire–based study of gestation, parturition and neonatal mortality in pedigree breeding cats in the UK. *J Feline Med Surg* 2006; **8**: 145–157.
- [8] Lawler DF. Neonatal and pediatric care of the puppy and kitten. *Theriogenology* 2008; **70**: 384–392.
- [9] Moon PF, Massat BJ, Pascoe PJ. Neonatal critical care. *Vet Clin North Am Food Anim Pract* 2001; **31**: 343–365.
- [10] Lawler DF, Monti KL. Morbidity and mortality in neonatal kittens. *Am J Vet Res* 1984; **45**: 1455–1459.
- [11] Lipinski MJ, Froenicke L, Baysac KC, Billings NC, Leutenegger CM, Levy AM, et al. The ascent of cat breeds: genetic evaluations of breeds and worldwide random–bred populations. *Genomics* 2008; **91**: 12–21.
- [12] Matten J. *Persian cats*. USA: Capstone Press; 2011, p. 7–29.
- [13] Thompson W, Ruffe EW. *The complete persian*. 2nd ed. Cynthia Parzych Publishing Inc; 2002.
- [14] Barachetti L, Mortellaro CM, Giancamillo MD, Giudice C, Martino P, Travetti O, et al. Bilateral orbital and nasal aspergillosis in a cat. *Vet Ophthalmol* 2009; **12**: 176–182.
- [15] Muller U, Power C. *Persian cats (Complete pet owner's manual)*. Barron's Publishing; 2004, p. 65–80.
- [16] Chermette R, Ferreiro L, Guillot J. Dermatophytoses in animals. *Mycopathologia* 2008; **166**: 385–405.
- [17] Kano R, Edamura K, Yumikura H, Maruyama H, Asano K, Tanaka S, et al. Confirmed case of feline mycetoma due to *Microsporum canis*. *Mycoses* 2008; **52**: 80–83.
- [18] Thian A, Woodgyer AJ, Holloway SA. Dysgonic strain of *Microsporum canis* pseudomycetoma in a domestic long–hair cat. *Aust Vet J* 2008; **86**: 324–328.
- [19] Outerbridge CA. Mycologic disorders of the skin. *Clin Tech Small Anim Pract* 2006; **21**: 128–134.
- [20] Noliand C, Scarpella F. Prospective open pilot study on the use of ciclosporin for feline allergic skin disease. *J Small Anim Pract* 2006; **47**: 434–438.
- [21] Nuttall TJ, German AJ, Holden SL, Hopkinson C, McEwa NA. Successful resolution of dermatophyte mycetoma following terbinafine treatment in two cats. *Vet Dermatol* 2008; **19**: 405–410.
- [22] Hosseinijad M, Vajhi A, Marjanmehr H, Hosseini F. Polycystic kidney in an adult Persian cat: clinical, diagnostic imaging, pathologic, and clinical pathologic evaluations. *Comp Clin Path* 2009; **18**: 95–97.
- [23] Rah HC, Maggs DJ, Lyons LA. Lack of genetic association among coat colors, progressive retinal atrophy and polycystic kidney disease in Persian cats. *J Feline Med Surg* 2006; **8**: 357–360.
- [24] Bucheler J. Fading kitten syndrome and neonatal isoerythrolysis. *Vet Clin North Am Food Anim Pract* 1999; **29**: 853–870.
- [25] Cave TA, Thompson H, Reid SW, Hodgson DR, Addie DD. Kitten mortality in the United Kingdom: a retrospective analysis of 274 histopathological examinations (1986 to 2000). *Vet Rec* 2002; **151**: 497–501.
- [26] Roth JA. Possible association of thymus dysfunction with fading syndromes in puppies and kittens. *Vet Clin North Am Food Anim Pract* 1987; **17**: 603–616.
- [27] Silvestre–Ferreira AC, Pastor J. Feline neonatal isoerythrolysis and the importance of feline blood types. *Vet Med Int* 2010; **2010**: 1–8.
- [28] Paradis M, Scott DW. Hereditary primary seborrhea–oleosa in Persian cats. *Feline Pract* 1990; **18**: 17–20.
- [29] Scott DW, Paradis M. A survey of canine and feline skin disorders seen in a university practice: Small Animal Clinic, University of Montréal, Saint–Hyacinthe, Québec (1987–1988). *Can Vet J* 1990; **31**: 830–835.