



Document heading doi: 10.12980/APJTB.4.2014APJTB-2014-0236 © 2014 by the Asian Pacific Journal of Tropical Biomedicine. All rights reserved.

## Ameliorative effect of *Leucas cephalotes* extract on isoniazid and rifampicin induced hepatotoxicity

Bhini Bais\*, Payal Saiju

Ravishankar College of Pharmacy, Bhopal, (M.P.), India, 462010

### ARTICLE INFO

#### Article history:

Received 8 May 2014

Received in revised form 13 May 2014

Accepted 5 Jun 2014

Available online 28 Jun 2014

#### Keywords:

Leucas cephalotes

Isoniazid

Rifampicin

Hepatoprotective

Oxidative stress

### ABSTRACT

**Objective:** To investigate ameliorative effect of alcoholic extract of whole herb of *Lucas cephalotes* (*L. cephalotes*) on isoniazid and rifampicin induced hepatotoxicity.

**Methods:** Hepatoprotective potential of alcoholic extract of *L. cephalotes* was ascertained at 200 mg/kg and 400 mg/kg in Sprague Dawley rats. Animals were intoxicated with isoniazid and rifampicin (100 mg/kg each, *i.p.*) for 21 d. Assessment was done on the basis of liver function test (serum glutamic oxaloacetic transaminase, serum glutamic pyruvic transaminase, alkaline phosphatase and bilirubin); effect on enzymes involved in oxidative stress (lipid peroxidase, superoxide dismutase, glutathione and catalase) and histology of liver were assessed as well. Comparison among different treatment group was done using One way ANOVA followed by Benferroni's *t* test.

**Results:** It was observed that at both of the selected doses extract exhibited significant ameliorative effect. In animals treated with the extract at both doses, serum glutamic oxaloacetic transaminase, serum glutamic pyruvic transaminase, alkaline phosphatase, bilirubin and lipid peroxidase level was found to be significantly less ( $P < 0.01$ ) and superoxide dismutase, glutathione and catalase level was significantly high ( $P < 0.01$ ) as compared to intoxicated animals.

**Conclusions:** From the present study it can be concluded that alcoholic extract of *L. cephalotes* possesses significant hepatoprotective potential against isoniazid and rifampicin induced hepatotoxicity.

## 1. Introduction

Tuberculosis is considered to be one of the common problems in undeveloped and developing countries. Isoniazid and rifampicin are integral parts of various dosage regimens available for treatment of tuberculosis. Drug induced hepatotoxicity is a main side effect of tuberculosis management regimens consisting of isoniazid and rifampicin[1]. As contrast to western countries, danger of hepatotoxicity is higher in India. On the basis of some Indian studies it can be considered to be around 11.5%[2]. Mechanism responsible for hepatotoxicity due to antitubercular drug is not clearly understood till the date.

Isoniazid is reported for its hepatotoxicity potential. Hepatic toxicity and hepatitis are supposed to be increased with concomitant use of many medication including

rifampicin, and alcohol abuse. Elevated level of serum transaminase (aspartate transaminase and alanine transaminase), fatal hepatitis, bilirubinaemia, bilirubinuria, and jaundice, can occur with dosing schedule consisting of isoniazid and rifampicin. The common prodromal symptoms of hepatitis are anorexia, nausea, vomiting, fatigue, malaise, and weakness[3]. Isoniazid and rifampicin dosed simultaneously in rabbits caused an elevation in phospholipids and a reduction in phosphatidylcholine, cardiolipin and inorganic phosphates, possibly via a choline deficiency, which may lead to the observed liver toxicity. Isoniazid and rifampicin co-administration caused steatosis and increased apoptosis of the hepatocytes and hepatic oxidative stress[4,5].

From above part it is clear that human beings can't avoid taking drugs and some of these unavoidable drugs possess significant toxicity on liver. *Leucas cephalotes* (*L. cephalotes*) whole herb is used by tribal of India in treatment of various ailments. *L. cephalotes* is reported to possess potential in treatment of various diseases. It is reported to possess

\*Corresponding author: Bhini Bais, Ravishankar College of Pharmacy, Bhopal, (M.P.), India, 462010.

Tel: +91 8989875588

E-mail: bhini\_bais@rediffmail.com

hepatoprotective= activity against carbon tetrachloride induced hepatotoxicity in wistar rats[6]. It is also reported to possess antiprotozoal, antioxidant, antidiabetic and antimicrobial activity[7–9]. On the basis of reported scientific and traditional evidence for hepatoprotective potential, the present study was designed to investigate protective potential of alcoholic extract of *L. cephalotes* whole plant against isoniazid and rifampicin induced hepatotoxicity.

## 2. Materials and methods

### 2.1. Experimental animals

Sprague Dawley rats of either sex weighing (200±20) g were selected at random from animal house of Pinnacle Biomedical Research Institute, Bhopal. Animal were housed in propylene cage using sterile husk as bedding material. Animals were kept at (22±2) °C in 12:12 light–dark cycle. Animal housing conditions were maintained as per CPCSEA guidelines. Animals were sifted to experimental room one hour prior to commencement of experiment for acclimatization. All animal experiments were performed with prior permission from Institutional Animal Ethics Committee of Pinnacle Biomedical Research Institute, Bhopal (1283/c/09/CPCSEA).

### 2.2. Chemicals and instruments

All biochemical investigations were performed using semi automatic biochemical analyzer (Star 21) and UV–vis spectrophotometer (Systronic, 2202) was used in estimation of enzymes involved in oxidative stress. All kits for liver function test were procured from Span Diagnostics, India. All other chemicals were of analytical grade, procured from Sigma Aldrich, USA, Himedia, and Merck, India.

### 2.3. Collection of plant material and extraction

Whole plant of *L. cephalotes* was collected from Bhopal, Madhya Pradesh, India. Herbarium was prepared and submitted for authentication to Dr. Zia–ul Hasan, Department of Botany, Safia College of Science, Bhopal, Madhya Pradesh, India (Voucher specimen No. 162/Bot/Safia/10). Plant material was dried under shade and crushed using electrical grinder. Pulverized plant material was packed in Soxhlet apparatus and extracted with methanol at 40 °C, after defating with petroleum ether. Extract was dried under vacuum using rotary vacuum evaporator at 40 °C. Dried plant material was packed in air tight container at 4 °C for further use.

### 2.4. Acute oral toxicity

Extract was found to be freely soluble in distilled

water, hence extract was dissolved in water for further investigations. Acute oral toxicity was performed as per Organization for Economic Co–operation and Development 423 guidelines. Albino wistar rats were administered with 5 mg/kg, 50 mg/kg, 300 mg/kg and 2000 mg/kg of the extract. No mortality and no significant behavioural alteration were observed till 2000 mg/kg, accordingly 2000 mg/kg was considered to be no observed adverse effect level for present investigation. About 1/10 and 1/5 of 2000 mg/kg, *i.e.* 200 mg/kg and 400 mg/kg were selected as doses for further *in vivo* experiment.

### 2.5. Experimental design

All animals were divided into five groups with six animals in each group. Distilled water was used as vehicle as extract was soluble in distilled water. Group I was vehicle treated group, administered with distilled water (1 mL/kg, *p.o.*). Group II was toxic control group, administered with isoniazid and rifampicin (100 mg/kg each, *i.p.*) dissolved in water for 21 d[10]. Vehicle was administered one hour prior to isoniazid and rifampicin administration. Group III and IV were test groups, administered with extract of *L. cephalotes* at 200 mg/kg, *p.o.* and 400 mg/kg, *p.o.* respectively with isoniazid and rifampicin (100 mg/kg each, *i.p.*) for 21 d. Extract was administered one hour prior to isoniazid and rifampicin administration. Group V was standard drug group administered with Silymarin (200 mg/kg, *p.o.*) suspended in 0.1% carboxymethyl cellulose. Vehicle, extract and Silymarin were administered one hour prior to isoniazid and rifampicin administration each day for 21 d. Twenty–four hours after last dosing, blood sample was collected through retro–orbital puncture and animals were sacrificed by cervical dislocation under general anesthesia. Liver was collected for estimation of enzymes involved in oxidative stress and histopathological examination.

### 2.6. Biochemical investigation

Blood sample was centrifuged at 2000 r/min and blood serum was used for biochemical studies. Serum glutamic oxaloacetic transaminase (SGOT), serum glutamic pyruvic transaminase (SGPT), alkaline phosphatase (ALP) and bilirubin level in different treatment groups was ascertained using biochemical analyser with the help of diagnostic kits.

### 2.7. Estimation of enzymes involved in oxidative stress

Half of the liver was rinsed with ice cold normal saline followed by 0.15 mol/L Tris HCl (pH 7.4). For estimation of lipid peroxidase (LPO), 10% w/v tissue homogenate was prepared in 0.15 mol/L Tris HCl (pH 7.4); for glutathione (GSH), 10% w/v tissue homogenate was prepared in 0.1 mol/L phosphate buffer (pH 7.4); for catalase 10% w/v tissue homogenate was prepared in 0.15 mol/L Tris HCl/0.1 mol/L

L phosphate buffer (pH 7.4), centrifuged at 15000 r/min for 15 min at 4 °C, supernatant was used as sample and for superoxide dismutase (SOD), tissue homogenate was prepared same as to that for catalase estimation<sup>[11]</sup>.

### 2.7.1. Catalase estimation

About 2.9 mL of H<sub>2</sub>O<sub>2</sub> solution was taken and observed at 240 nm till absorbance became stable. About 2.9 mL of H<sub>2</sub>O<sub>2</sub> solution and 0.1 mL test sample was added, mixed by inversion and the time required for the absorbance at 240 nm to decrease from 0.45 to 0.40 absorbance units was recorded. One unit was considered to decompose 1.0 µmol of H<sub>2</sub>O<sub>2</sub> per minute at pH 7.0 at 25 °C, while the H<sub>2</sub>O<sub>2</sub> concentration falls from 10.3 mmol/L to 9.2 mmol/L. The rate of disappearance of H<sub>2</sub>O<sub>2</sub> is followed by observing the rate of decrease in the absorbance at 240 nm.

### 2.7.2. SOD estimation

About 10% w/v tissue homogenate in 0.15 mol/L Tris HCl was prepared, centrifuged at 15000 r/min for 15 min at 4 °C. Supernatant (0.1 mL) was taken and considered as sample. Briefly, 0.1 mL sample, 1.2 mL sodium pyrophosphate buffer (pH 8.3, 0.052 mol/L), 0.1 mL phenazine methosulphate (186 µmol/L), 0.3 mL of 300 µmol/L nitrobluetetrazolium, and 1 mL/kg reduced form of nicotinamide–adenine dinucleotid (750 µmol/L) was mixed and incubated at 30 °C for 90 seconds. About 0.1 mL glacial acetic acid was added, stirred with 4.0 mL *n*-butanol, then allowed to stand for 10 min. Butanol layer was centrifuged and separated. Optical density (OD) at 560 nm was observed. One unit of SOD is the amount of enzyme that inhibit the rate of reaction by 50%.

### 2.7.3. LPO estimation

About 10% w/v tissue homogenate in 0.15 mol/L Tris HCl buffer (pH 7.4) was prepared. Briefly, 1 mL/kg tissue homogenate, 1 mL/kg 8.1% sodium dodecyl sulfonate, 1.5 mL 20% acetic acid and 1.5 mL 8% TBA were mixed and made up volume upto 4 mL with distilled water. The mixture was heated on waterbath (95 °C) for 60 min using glass ball as condenser, and then cooled and volume was made upto 5 mL. A total of 5 mL of butanol: pyridine (15:1) was added and vortexed for 2 min, centrifuged at 3000 r/min (10 min). The upper organic layer was taken and OD was observed at 532 nm.

### 2.7.4. GSH estimation

Tissue homogenate (0.1 mol/L phosphate buffer 7.4 pH, 10%) was prepared. About 1 mL/kg of homogenate was taken and 20% trichloroacetic acid and 1 mmol/L ethylene diamine tetraacetic acid were added. The mixture was set aside for 5 min and centrifuged for 10 min at 2000 r/min. To the supernatant (200 µL), 1.8 mL of Ellman's reagent [5,5'-dithio bis-2-nitrobenzoic acid (0.1 mmol/L) prepared in 0.3 mol/L phosphate buffer, pH 7 with 1% sodium citrate solution] was added. Volume was adjusted upto 2 mL with distilled water. OD was noted at 412 nm.

### 2.8. Histological examination

Remaining part of liver was preserved in buffered formalin (10%) for histology. About 5 µm thick sections of liver were prepared using rotary microtome. Sections were stained with Hematoxylin and Eosin. Stained sections were observed under optical microscope at 40× magnification.

### 2.9. Biostatistical interpretation

All data are presented in mean±SD (*n*=6). Data were analyzed by One-way ANOVA followed by Benferroni's test. *P*<0.01 was considered as level of significance.

## 3. Results

### 3.1. Acute oral toxicity

Neither mortality nor any adverse effect was observed till 2000 mg/kg. Hence for present study 2000 mg/kg was selected as no observed adverse effect level for oral administration of methanolic extract of whole plant of *L. cephalotes*.

### 3.2. Hepatoprotective activity

Animals of toxic control group had significantly elevated (*P*<0.01) level of SGOT, SGPT, ALP and bilirubin as compared to vehicle treated animals (Table 1). This confirmed the toxic effect of isoniazid and rifampicin at selected doses on liver. In animals of test group at both doses (*i.e.* 200 mg/kg and 400 mg/kg) there was significant protection observed for liver. This was confirmed on the basis of significantly lower

**Table 1**

Effect of methanolic extract of *L. cephalotes* on liver function test in animals intoxicated with isoniazid and rifampicin.

Treatment group	SGOT (IU/L)	SGPT (IU/L)	ALP (IU/L)	Bilirubin (mg/dL)
Vehicle (1 mL/kg/d, <i>p.o.</i> )	58.21±4.66	45.23±2.84	102.00±5.02	0.280±0.031
Vehicle (1 mL/(kg·d), <i>p.o.</i> )+INH-RIF (100 mg/(kg·d) each <i>i.p.</i> )	136.44±9.24 <sup>a</sup>	86.63±6.42 <sup>a</sup>	202.57±8.55 <sup>a</sup>	0.860±0.052 <sup>a</sup>
Extract (200 mg/(kg·d), <i>p.o.</i> )+INH-RIF (100 mg/(kg·d) each <i>i.p.</i> )	76.64±5.83 <sup>b</sup>	62.66±4.67 <sup>b</sup>	132.21±8.75 <sup>b</sup>	0.450±0.021 <sup>b</sup>
Extract (400 mg/(kg·d), <i>p.o.</i> )+INH-RIF (100 mg/(kg·d) each <i>i.p.</i> )	69.32±4.76 <sup>b</sup>	54.82±3.56 <sup>b</sup>	121.05±10.67 <sup>b</sup>	0.410±0.035 <sup>b</sup>
Silymarin (200 mg/(kg·d), <i>p.o.</i> )+INH-RIF (100 mg/(kg·d) each <i>i.p.</i> )	61.35±5.21 <sup>b</sup>	49.67±3.98 <sup>b</sup>	118.63±7.83 <sup>b</sup>	0.350±0.022 <sup>b</sup>

All data presented in mean±SD (*n*=6).

<sup>a</sup> *P*<0.01 as compared to vehicle treated group, <sup>b</sup> *P*<0.01 as compared to toxic control group.

INH-RIF: isoniazid and rifampicin.

**Table 2**Effect of methanolic extract of *L. cephalotes* on enzymes involved in oxidative stress in animals intoxicated with isoniazid and rifampicin.

Treatment group	LPO (nmol MDA/g tissue)	SOD (IU/g tissue)	GSH ( $\mu\text{mol/g}$ tissue)	Catalase (IU/mg tissue)
Vehicle (1 mL/(kg·d), <i>p.o.</i> )	58.37 $\pm$ 4.21	38.67 $\pm$ 2.63	1.63 $\pm$ 0.09	5.02 $\pm$ 0.14
Vehicle (1 mL/(kg·d), <i>p.o.</i> )+INH–RIF (100 mg/(kg·d) each <i>i.p.</i> )	86.78 $\pm$ 5.64 <sup>a</sup>	19.21 $\pm$ 1.24 <sup>a</sup>	0.42 $\pm$ 0.02 <sup>a</sup>	1.68 $\pm$ 0.08 <sup>a</sup>
Extract (200 mg/(kg·d), <i>p.o.</i> )+INH–RIF (100 mg/(kg·d) each <i>i.p.</i> )	73.63 $\pm$ 5.23 <sup>b</sup>	29.67 $\pm$ 2.05 <sup>b</sup>	1.32 $\pm$ 0.08 <sup>b</sup>	3.85 $\pm$ 0.15 <sup>b</sup>
Extract (400 mg/(kg·d), <i>p.o.</i> )+INH–RIF (100 mg/(kg·d) each <i>i.p.</i> )	68.44 $\pm$ 4.67 <sup>b</sup>	31.24 $\pm$ 1.56 <sup>b</sup>	1.53 $\pm$ 0.1 <sup>b</sup>	4.06 $\pm$ 0.38 <sup>b</sup>
Silymarin (200 mg/(kg·d), <i>p.o.</i> )+INH–RIF (100 mg/(kg·d) each <i>i.p.</i> )	63.45 $\pm$ 3.98 <sup>b</sup>	35.06 $\pm$ 2.04 <sup>b</sup>	1.58 $\pm$ 0.09 <sup>b</sup>	4.88 $\pm$ 0.25 <sup>b</sup>

All data presented in mean $\pm$ SD ( $n=6$ ).<sup>a</sup>  $P<0.01$  as compared to vehicle treated group, <sup>b</sup>  $P<0.01$  as compared to toxic control group.

MDA: methane dicarboxylic aldehyde, INH–RIF: isoniazid and rifampicin.

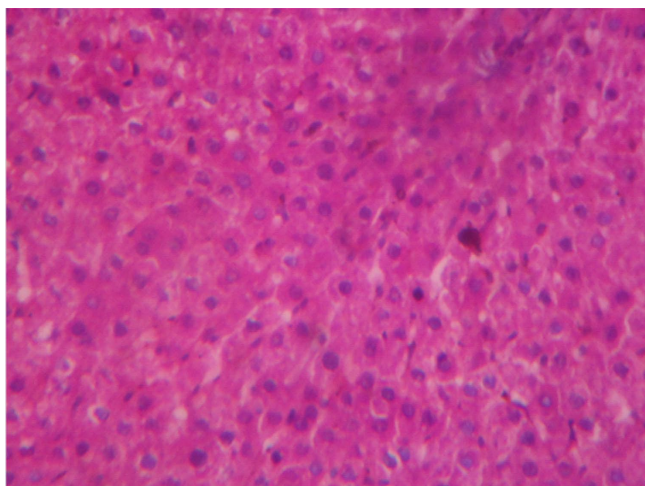
( $P<0.01$ ) level of SGOT, SGPT, ALP and bilirubin as compared to that of animals of toxic control group. Silymarin treated animals also had significantly lower ( $P<0.01$ ) level of SGOT, SGPT, ALP and bilirubin as compared to animals of toxic control group.

### 3.3. Effect on enzymes involved in oxidative stress

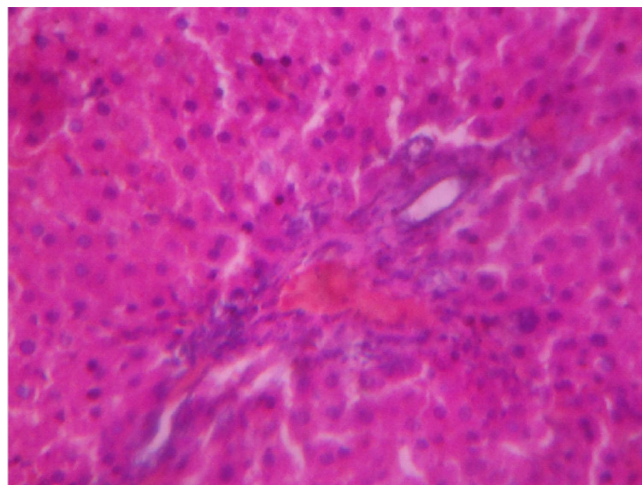
In animals of toxic control group level of LPO was found to be significantly higher ( $P<0.01$ ) as compared to vehicle treated animals. Level of SOD, GSH and catalase was found to be significantly lower ( $P<0.01$ ) as compared to vehicle treated animals. This confirmed that administration of isoniazid and rifampicin caused significant oxidative stress in liver of animals of toxic control group. In extract treated animals at both doses, level of LPO was found to be significantly lower ( $P<0.01$ ) as compared to toxic control group; level of SOD, GSH, and catalase was found to be significantly elevated ( $P<0.01$ ) as compared to toxic control group. Effect of Silymarin was also found to be significantly protective against oxidative stress induced by the antitubercular drugs (Table 2).

### 3.4. Histological examination

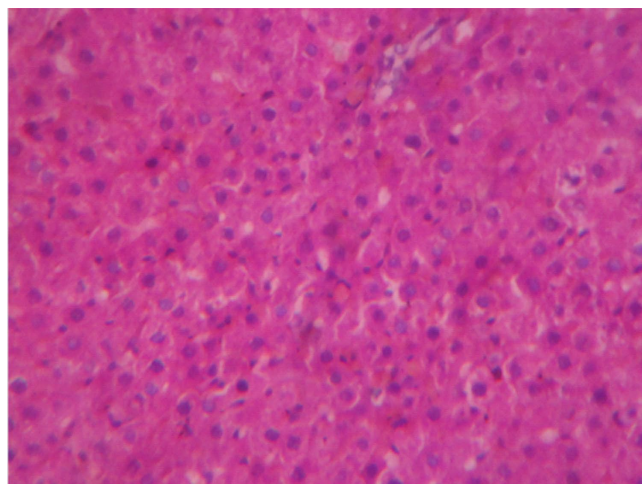
Histological examination of liver of vehicle treated animal revealed normal architecture (Figure 1). Central vein, portal triad, their respective vascular layer, sinusoids, and hepatocytes were found to be normal.

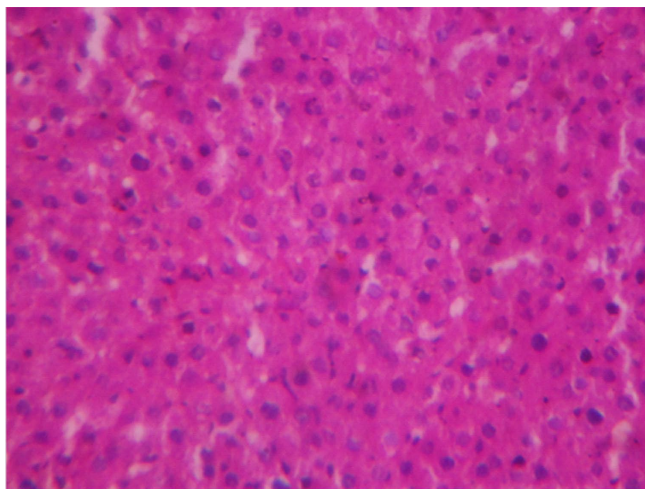
**Figure 1.** Histology of liver of vehicle treated animal (40X).

In animals of toxic control group, fatty degeneration (steatosis), inflammation, degenerated hepatocytes, distended sinusoids, necrosis, and hypertrophy in hepatocytes were observed (Figure 2).

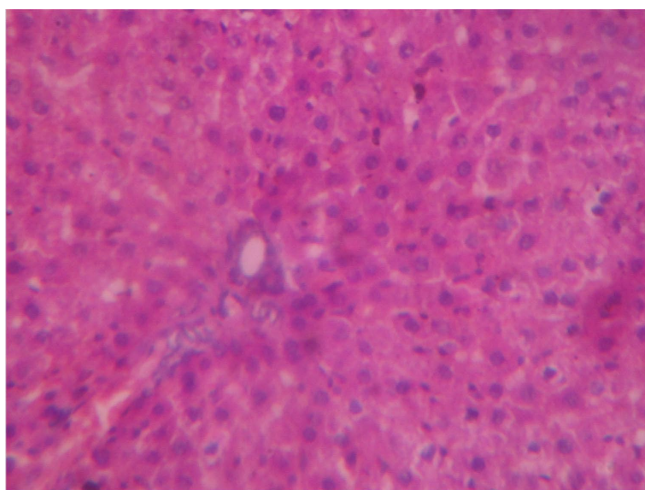
**Figure 2.** Histology of liver of isoniazid and rifampicin with vehicle treated animal (40X). Signs of inflammatory infiltration, steatosis, and vascular endothelial degeneration were observed.

In extract treated animals at 200 mg/kg, mild signs of inflammation were present (Figure 3), but at 400 mg/kg liver of animals were found to retain normal architecture (Figure 4). In Silymarin treated animals significant protection at histological level was also confirmed (Figure 5).

**Figure 3.** Histology of liver animal treated with isoniazid, rifampicin and extract at 200 mg/kg (40X). Significant protection with mild inflammation was observed.



**Figure 4.** Histology of liver of isoniazid and rifampicin with extract at 400 mg/kg treated animal (40X). Significant protection was observed.



**Figure 5.** Histology of liver of isoniazid and rifampicin with Silymarin at 200 mg/kg treated animal (40X). Significant protection was observed.

#### 4. Discussion

Since ancient time many medicinal plants have been used in traditional system of medicine for treatment of various ailments. Many of these medicinal plants are reported to have significant protection against disease associated with liver. Drug induced hepatotoxicity is one of the major problem associated with use of many medication. Treatment of tuberculosis in general requires chronic administration with isoniazid and rifamicin. Amongst the various adverse effects of this combination, hepatotoxicity is the most noticeable one. Many investigators reported protective potential of medicinal plants against isoniazid and rifampicin induced hepatotoxicity. *L. cephalotes* is used traditionally in treatment of various diseases including liver disorders. Hence present study was designed to investigate protective potential of whole plant extract of *L. cephalotes* against isoniazid and rifampicin induced hepatotoxicity.

Isoniazid is considered to be a highly effective drug in the

prophylaxis and treatment of tuberculosis. Sub chronic or chronic, daily administration of isoniazid is considered to be involved in mild elevations of enzymes in liver activities up to 20% of patients and significant hepatotoxicity in approximately one to two percentage of patients receiving the drug. If this liver toxicity is not recognized in early stage, it can be fatal. It has been reported that isoniazid induced liver injury cannot be easily differentiated from viral hepatic disorder<sup>[4]</sup>. Anti-tuberculosis drugs cause liver cells to produce drug inflammatory reactions, and hypomethylation of the genome and LINE-1 repetitive elements caused by the inflammatory reactions can activate the genome and produce some products that are found in the tumor cells, thus probably progressing the inflammation toward cancer<sup>[5]</sup>. Rifampin is another primary component for the treatment and prophylaxis of tuberculosis. Previously, it has been reported that the incidence of hepatotoxicity is approximately 2.6% with isoniazid-rifampin co-administration but only 1.6% with isoniazid treatment alone and 1.1% with rifampin alone, suggesting the higher incidence of severe hepatotoxicity in patients co-treated with these two drugs.

One possible mechanism for the additive or synergistic effects of rifampin on isoniazid hepatotoxicity may be through the induction of drug-metabolizing enzymes. Changes in lipids (both in serum and liver) are likely involved in the pathogenesis of isoniazid and rifampin induced hepatotoxicity in rats<sup>[12]</sup>. The common prodromal symptoms of hepatitis are anorexia nausea, vomiting, fatigue, malaise, and weakness. Mild hepatic dysfunction, evidenced by mild and transient elevation of serum transaminase levels, occurs in 10%–20% of patients taking antitubercular drugs<sup>[3]</sup>.

Elevated serum transaminase (SGOT, SGPT), bilirubinaemia, bilirubinuria, jaundice, and occasionally severe and sometimes fatal hepatitis can occur with normal dosing regimens of antitubercular drugs. SGPT (Alanine Aminotransferase) is an enzyme found mainly in the liver that is released into the bloodstream when the liver is inflamed. An elevated alanine transaminase level is indicative of hepatocellular necrosis and has been used as a surrogate marker of liver injury. SGOT (aspartate aminotransferase) is elevated when the aspartate transaminase, an enzyme found in the liver and some other body tissues is released into the bloodstream from the inflamed tissue. Low values are of no clinical interest and high values usually indicate hepatitis<sup>[13]</sup>. In present study it was observed that due to administration of isoniazid and rifampicin, significant elevation in SGOT and SGPT occurred. In extract treated animals at both doses these enzymes were found to be significantly less.

In liver, ALP is found histochemically in the microvilli of bile canaliculi and on the sinusoidal surface of hepatocytes. High values usually indicate that the bile is not flowing normally through the gall bladder and bile duct into the intestine, a condition called Astasis<sup>[13]</sup>. Bilirubin in body is a careful balance between production and removal of the

pigment in body. Hyperbilirubinemia seen in acute hepatitis is directly proportional to the degree of histological injury of hepatocytes and the longer course of the disease. In toxic control group, level of ALP and bilirubin was significantly higher as compared to vehicle treated animals. In extract treated animals at 200 mg/kg and 400 mg/kg, level of ALP and bilirubin was found to be significantly less as compared to toxic control group. This confirmed protective effect of *L. cephalotes* extract against isoniazid and rifampicin induced hepatotoxicity.

Involvement of oxidative stress in hepatotoxicity caused by combination of isoniazid and rifampicin is already established. Sodhi *et al.* reported that at 50 mg/(kg·d) each of isoniazid and rifampicin for two weeks, SOD, glutathione peroxidase, catalase and glutathione-S-transferases decreases significantly<sup>[14]</sup>. Enhanced oxidative stress in antitubercular drug treated animals was confirmed on the basis of altered profile of antioxidant enzymes and increased lipid peroxidation<sup>[14]</sup>.

SOD is a class of closely related enzymes that catalyze the breakdown of the superoxide anion into oxygen and hydrogen peroxide. Catalases are enzymes that catalyze the conversion of hydrogen peroxide to water and oxygen, using either an iron or manganese cofactor. Biochemical function of glutathione peroxidase is to reduce lipid hydroperoxides to their corresponding alcohols and to reduce free hydrogen peroxide to water. Increasing one's glutathione levels help the productivity of the glutathione peroxidase and vice versa. Lipid peroxidase is the enzyme involved in oxidative degradation of lipids. In the process free radicals steal electrons from the lipids in cell membranes, resulting in cell damage. This process proceeds by a free radical chain reaction mechanism. It most often affects polyunsaturated fatty acids, because they contain multiple double bonds in between which lie methylene groups that possess especially reactive hydrogen. In toxic control group level of SOD, GSH and catalase was significantly lower and LPO level was significantly higher. This confirmed the induction of oxidative stress due to administration of isoniazid and rifampicin in toxic control group. At both of the selected doses of extract, significant protection against oxidative stress was observed with increase in level of SOD, GSH and catalase and decrease in LPO level.

*L. cephalotes* is reported for its hepatoprotective activity against carbon tetrachloride<sup>[6]</sup>. It is also reported for its antioxidant potential. Besides, the plant is also reported to contain triterpenes, oleanolic acid, sterols and flavones. Other constituents such as luteolin 4'-O-beta-D-glucuronopyranoside, leucadins A, B and C, lauric acid, tridecanoic acid, leucastrins A and B, adipic acid, glutaric acid and labellic acid (seed oil) was also reported. Luteolin is considered to be hepatoprotective and antioxidant<sup>[15,16]</sup>. Thus from present investigation it can be concluded that methanolic extract of whole plant of *L. cephalotes* possesses significant hepatoprotective activity against isoniazid and rifampicin induced hepatotoxicity and this can be attributed

to presence of flavones in extract.

### Conflict of interest statement

We declare that we have no conflict of interest.

### References

- [1] Mahashur AA, Prabhudesai PP. Hepatitis and antitubercular therapy. *J Assoc Physicians India* 1991; **39**: 595–596.
- [2] Steele MA, Burk RF, Desprez RM. Toxic hepatitis with isoniazid and rifampicin. A meta-analysis. *Chest* 1991; **99**: 465–471.
- [3] Isoniazid. *Tuberculosis* 2008; **88**(2): 112–116.
- [4] Sarich TC, Zhou T, Adams SP, Bain AI, Wall RA, Wright JM. A model of isoniazid-induced hepatotoxicity in rabbits. *J Pharmacol Toxicol Methods* 1995; **34**: 109–116.
- [5] Zhang B, Sun S, Shen L, Zu X, Chen Y, Hao J, et al. DNA methylation in the rat livers induced by low dosage isoniazid treatment. *Environ Toxicol Pharmacol* 2011; **32**: 486–490.
- [6] Sofi G, Khan MY, Jafri MA. Hepatoprotective activity of Gumma (*Leucas cephalotes* Spreng.) against carbon tetrachloride induced hepatotoxicity in wistar rats. *Anc Sci Life* 2011; **31**(2): 44–48.
- [7] Dua VK, Verma G, Agarwal DD, Kaiser M, Brun R. Antiprotozoal activities of traditional medicinal plants from the Garhwal region of North West Himalaya, India. *J Ethnopharmacol* 2011; **136**(1): 123–128.
- [8] Bavarva JH, Narasimhacharya AV. *Leucas cephalotes* regulates carbohydrate and lipid metabolism and improves antioxidant status in IDDM and NIDDM rats. *J Ethnopharmacol* 2010; **127**(1): 98–102.
- [9] Madhukiran BL, Vijaya LK, Uma MD. Antibacterial properties of *Leucas cephalotes* (Roth) Spreng. Leaf. *Anc Sci Life* 2002; **21**(4): 244–247.
- [10] Thattakudian Sheik Uduman MS, Sundarapandian R, Muthumanikkam A, Kalimuthu G, Parameswari SA, Vasanthi Srinivas TR, et al. Protective effect of methanolic extract of *Annona squamosa* Linn in isoniazid-rifampicin induced hepatotoxicity in rats. *Pak J Pharm Sci* 2011; **24**(2): 129–134.
- [11] Sapakal VD, Shikalgar TS, Ghadge RV, Adnaik RS, Naikwade NS, Magdum CS. *In vivo* screening of antioxidant profile: a review. *J Herb Med Toxicol* 2008; **2**: 1–8.
- [12] Pal R, Rana SV, Vaiphei K, Singh K. Isoniazid-rifampicin induced lipid changes in rats. *Clin Chim Acta* 2008; **389**: 55–60.
- [13] Thapa BR, Walia A. Liver function tests and their interpretation. *Indian J Pediatr* 2007; **74**: 663–671.
- [14] Sodhi CP, Rana SV, Mehta SK, Vaiphei K, Attari S, Mehta S. Study of oxidative-stress in isoniazid-rifampicin induced hepatic injury in young rats. *Drug Chem Toxicol* 1997; **20**(3): 255–269.
- [15] López-Lázaro M. Distribution and biological activities of the flavonoid luteolin. *Mini Rev Med Chem* 2009; **9**: 31–59.
- [16] Domitrović R, Jakovac H, Milin C, Radosević-Stasić B. Dose- and time-dependent effects of luteolin on carbon tetrachloride-induced hepatotoxicity in mice. *Exp Toxicol Pathol* 2009; **61**(6): 581–589.