




Contents lists available at ScienceDirect

Asian Pacific Journal of Tropical Biomedicine

journal homepage: www.elsevier.com/locate/apjtb



Document heading doi:10.1016/S2221-1691(11)60023-3 © 2011 by the Asian Pacific Journal of Tropical Biomedicine. All rights reserved.

Histopathological studies of acute and chronic effects of *Calliandra portoricensis* leaf extract on the stomach and pancreas of adult Swiss albino mice

Ofusori David A^{1*}, Adejuwon Adebomi O²¹Department of Anatomy and Cell Biology, Faculty of Basic Medical Sciences, Obafemi Awolowo University, Ile-Ife, Osun State, Nigeria²Faculty of Pharmacy, Obafemi Awolowo University, Ile-Ife, Osun State, Nigeria

ARTICLE INFO

Article history:

Received 5 February 2011

Received in revised form 17 February 2011

Accepted 13 March 2011

Available online 30 March 2011

Keywords:

Calliandra portoricensis

Pancreas

Stomach

Histology

Disorganization

Degeneration

Langerans

ABSTRACT

Objective: To evaluate the consequence of oral administration of *Calliandra portoricensis* (*C. portoricensis*) leaf extract on the stomach and pancreas in Swiss albino mice. **Methods:** Three groups of mice (B, C and D) were treated with 4 mg/kg of *C. portoricensis* extract. Group A was the control and received an equivalent volume of distilled water. Group B received *C. portoricensis* leaf extract for 7 days, Group C received *C. portoricensis* leaf extract for 14 days, and Group D received *C. portoricensis* leaf extract for 28 days. At different stages in the study, the mice were sacrificed and the stomach and pancreas were excised and fixed in 10% formal saline for histological analysis. **Results:** The result showed a normal microstructural outline in groups B and C as compared with the control. However, animals in group D showed disorganization of the mucosa and discontinuation of epithelial lining of the stomach while the islets of Langerans in the pancreas were at various degree of degeneration as compared with the control mice. **Conclusions:** The present finding suggests that chronic administration (28 days as seen in this study) of *C. portoricensis* leaf extract may inhibit the proper function of the stomach and pancreas.

1. Introduction

Calliandra portoricensis (*C. portoricensis*) is also known as snowflake acacia or powder-puff. This shrub or little tree is native to Central America, and most precisely to Mexico, Panama, and to the West Indies. *C. portoricensis* can be grown in areas where frosts are brief and moderate, i.e. in USDA zones 10a or warmer. In other places, it should be protected and sparsely watered in winter[1]. This shrub has evergreen bipinnate small leaves with each leaflet being about 0.5 in (1.25 cm) long. It has white scented and globose flowers, which look like small snowballs. They last about one day. Fruits are pods, which are about 4 in (10 cm) long[1].

Diet rich in vegetables and fruit provides protection against diseases such as cardiovascular disease[2,3] and cancers[4]. The leaves of *C. portoricensis* plant are pharmacologically useful. The roots and the leaves' analgesic and anticonvulsant properties have been

investigated[5]. Both aqueous and alcoholic extracts of the leaves were reported to have anti-ulcerogenic effect[6]. Moharram *et al*[7] reported seventeen compounds from the genus *Calliandra*. They are gallic acid, methyl gallate, myricitrin, quercitrin, myricetin 3-O- β -D-4C1-lucopyranoside, afzelin, isoquercitrin, myricetin 3-O-(6''-O-galloyl)- β -D-glucopyranoside, myricitrin 2''-O-gallate, quercitrin 2''-O-gallate, afzelin 2''-O-gallate, myricitrin 3''-O-gallate, afzelin 3''-O-gallate, 1,2,3,4,6-penta-O-galloyl- β -D-4C1-glucopyranose, myricitrin 2'',3''-di-O-gallate, quercetin 3-O-methyl ether.

Orishadipe *et al*[1] also reported the presence of caffeic acid and betulinic acid. Compounds such as myricitrin, quercitrin, myricitrin 2''-O-gallate, quercitrin 2''-O-gallate, myricitrin 3''-O-gallate, and myricitrin 2'',3''-di-O-gallate, exhibited moderate to strong radical scavenging properties on lipid peroxidation, hydroxyl radical, superoxide anion[1].

The gas chromatography-mass spectrometry analysis results of the hexane fraction of the root of *C. portoricensis* indicated that the extract is rich in fatty acids/methyl esters which have been implicated in plant's antimicrobial activities[1].

*Corresponding author: Ofusori David A, Department of Anatomy and Cell Biology, Faculty of Basic Medical Sciences, Obafemi Awolowo University, Ile-Ife, Osun State, Nigeria.

Tel: +234-803-445-5715

E-mail: davidofus234@yahoo.com; david.anatomist@rocketmail.com

Despite all these beneficial effects of the plant, literature is scanty on the toxicological potentials on visceral organs in the body. We therefore set to determine the histological effects of acute and chronic administration of *C. portoricensis* leaf extract on the stomach and pancreas of Swiss albino mice.

2. Materials and methods

2.1. Collection of plant materials

Fresh but matured leaves of *C. portoricensis* were collected from Zoological Garden of the Obafemi Awolowo University, Ile-Ife, Nigeria. They were authenticated in the Botany Department of the same university. The leaves were rinsed severally with clean tap water to remove dust particles and debris and thereafter allowed to completely drain.

2.2. Preparation of the *C. portoricensis* extract

The ground dried *C. portoricensis* (100 g) was fluxed with distilled water (500 mL) and shaken at room temperature for 48 h. The extraction was performed twice. After extraction, the mixture was concentrated with rotary vacuum evaporator (EYELA, Japan). The yield was freeze dried, weighed, dissolved in normal saline and administered at a dose of 4 mg/kg.

2.3. Experimental design

A total of twenty-four Swiss albino mice were used for this study. Animals in the treated groups (B, C and D; $n=18$) were orally administered with 4 mg/kg of *C. portoricensis* extract. Group B received *C. portoricensis* leaf extract for

7 days, Group C received the same for 14 days, and Group D for 28 days. Group A ($n=6$) was the control and received an equivalent volume of normal saline. At different stages in the study, the mice were sacrificed and the stomach and pancreas were excised and fixed in 10% formol saline for histological analysis. Proper care of the animals was in accordance to the National Institute of Health (U.S. PHS policy) on humane care of laboratory animal.

2.4. Histological examination

The histological study of the stomach and pancreas adopted the method of carlton (1967). Samples of the corpus from the stomach and tail of the pancreas were excised and fixed in 10% formol saline and later processed by routine techniques prior to embedding in paraffin. Sections ($5 \mu\text{m}$ thick) were mounted on glass slides and stained with haematoxylin and eosin. Permanent photomicrograph was obtained using Olympus Research Microscope (model BX51).

3. Results

There was no mortality in all the mice administered with *C. portoricensis* (4 mg/kg) leaf extracts during the period of

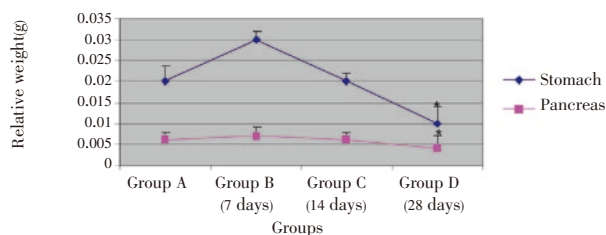


Figure 1. Relative organ weight of animals treated with *C. portoricensis*. $n=6$; * $P<0.05$ (significant) vs. control.

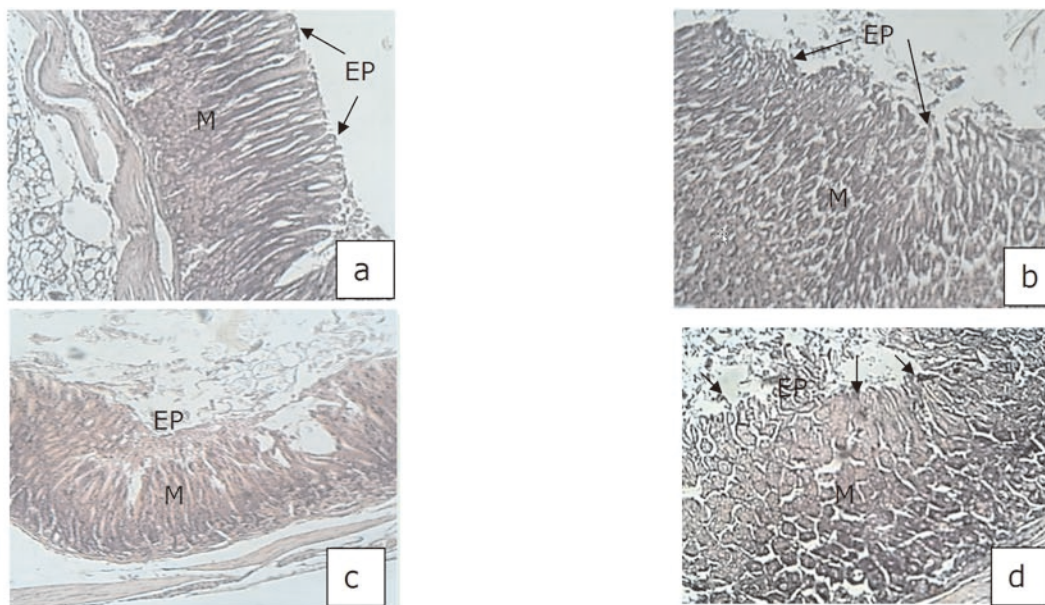


Figure 2. The photomicrograph of the stomach.

a: control note the musosa (M) and smooth epithelial lining (EP); b: group administered with 4 mg/kg of *C. portoricensis* for 7 days. Note the musosa (M) and epithelial lining (EP); c: group administered with 4 mg/kg of *C. portoricensis* for 14 days. Note the musosa (M) and epithelial lining (EP); d: group administered with 4 mg/kg of *C. portoricensis* for 28 days. Note the disorganization in the musosa (M) and discontinuity in the epithelial lining (EP) (black arrow) (400 \times).

study. However, animals in group D showed sign of ill health as evidenced in their activities which was characterized by sluggishness and reduction in food and water intake.

There was a statistically significant decrement ($P<0.05$) in the relative organ weights of animals in group D compared with control group (Figure 1).

Administration of *C. portoricensis* for 28 days resulted

in distorted arrangement and irregular appearance of the stomach mucosa. The gastric glands were disorganized with scanty parietal and zymogenic cells. This was also characterized by the erosions of the surface epithelium as compared with the control group and the groups in which *C. portoricensis* administration lasted for 7 (group B) and 14 days (group C). Sections of the pancreas for group D presented

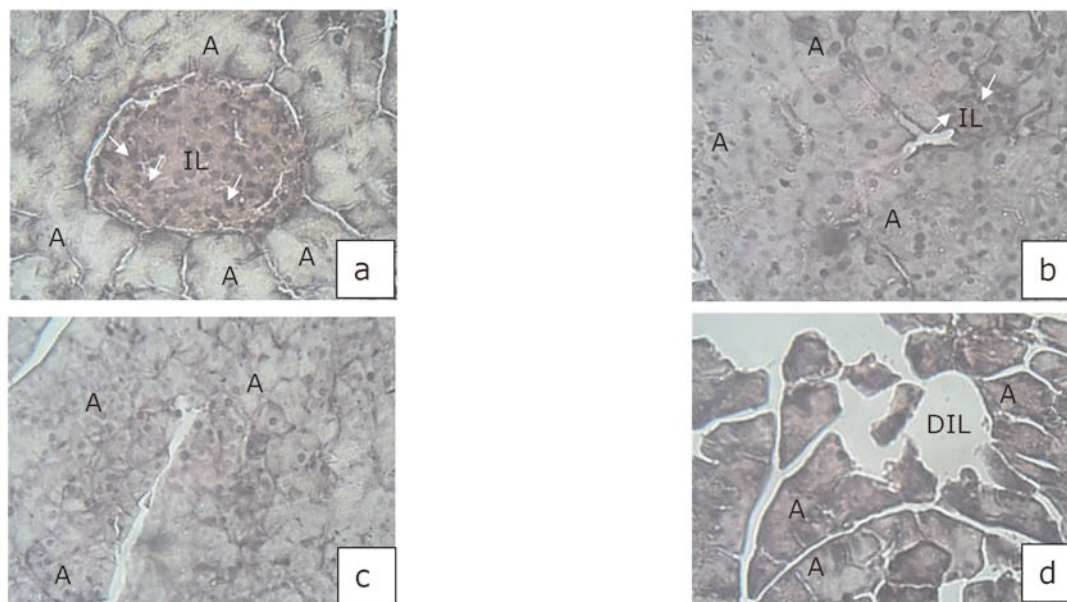


Figure 3. The photomicrograph of the pancreas.

a: control note the glandular acini (A), islet of Langerhans (IL), β -Cells (white arrow); b: group administered with 4 mg/kg of *C. portoricensis* for 7 days. Note the glandular acini (A), islet of Langerhans (IL), β -cells (white arrow); c: group administered with 4 mg/kg of *C. portoricensis* for 14 days. Note the glandular acini (A); d: group administered with 4 mg/kg of *C. portoricensis* for 28 days. Note the disorganization of glandular acini (A) and site of degenerated islet of Langerhans (DIL) (400 \times).

disorganization of glandular acini and degenerated islets of Langerhans as compared with the control mice (Figure 2, 3).

There were no significant differences between group B and C vis-à-vis the control group in terms of mucosa injury.

4. Discussion

This study histologically evaluated the acute and chronic effects of oral administration of *C. portoricensis* leaf extract on the stomach and pancreas in Swiss albino mice.

The significant difference ($P<0.05$) observed when the relative organ weight of the control (group A) was compared with group D implied that oxidative stress may have set in as a result of toxic effect of the extract on the stomach and pancreas. Oxidative stress is caused by an imbalance between the production of reactive oxygen and a biological system's ability to readily detoxify the reactive intermediates or easily repair the resulting damage^[8–13]. Normally, the body produces an armoury of antioxidants to defend itself^[14–22]. It's the job of antioxidants to neutralise or ' mop up ' free radicals that can harm our cells^[23,24]. In this study, the body's internal production of antioxidants may not have been adequate to neutralise all the free radicals generated

as a result of prolonged exposure to *C. portoricensis*, thus resulting in the drastic significant ($P<0.05$) reduction in the weight difference observed in group D.

Investigation has shown that both aqueous and ethanolic leaf extract of *C. portoricensis* inhibited the ulcerogenic effects of pylorus ligation and stress (cold-restraint) in rats at a dose of 50 mg/kg^[6]. Also, Akah and Nwaiwu^[5] reported the anticonvulsant effect. A dose-dependent analgesic activity of the roots and leaves of methanolic extract of *C. portoricensis* was investigated in mice and rats^[5]. Our observation from the photomicrograph showed that *C. portoricensis* when consumed repeatedly for a long time may, indeed, elicit toxicity in the stomach and pancreas. This was the case for animals in group D where administration went for 28 days. This observation corroborates the study of Ojiako and Nwanjo^[25]. The distorted arrangement of the gastric glands and the scanty nature of parietal and zymogenic cells may ultimately decrease the volume of gastric juice secretion, thus affecting the digestive processes. Sections of the pancreas which also presented degenerated islet of Langerhans and disorganization of glandular acini as compared with the control mice underscore the events going on microscopically. β cells constitute the majority of islet cells which produces insulin. Diminution of β

cells will consequently cause insulin insufficiency which will lead to hyperglycaemia as a result of disorder in carbohydrate, protein and fat metabolism. This means that if the consumption of *C. portoricensis* is grossly abused, the resultant effect may just be diabetes. Disorganization of the glandular acini noticed in Figure 3d will ultimately affect the secretion of pancreatic juice which contains digestive enzymes that pass to the small intestine. These enzymes which help to further break down the carbohydrates, proteins, and lipids (fats) in the chyme will be greatly hindered; thus resulting in digestive complications.

The exact mechanism by which this plant exhibited its “non toxic” effect in the stomach and pancreas of animals in groups B and C is yet to be known but it has been documented that *C. portoricensis* leaves contain saponins, tannins, flavonoids and glycosides[6]. This documentations coupled with the fact that the administration only proceeded for 7 and 14 days as against the toxic effect elicited when administration went for 28 days may also provide a reasonable explanation for the normal histoarchitectural observations in stomachs and pancreas of animals in groups B and C.

It is therefore worthwhile to conclude that though *C. portoricensis* is a very good and promising plant which can be of benefit to visceral organs such as the stomach and pancreas, its prolonged (chronic) consumption may be deleterious as seen in this investigation. We however, call for caution during the medicinal application of this plant.

Conflict of interest statement

We declare that we have no conflict of interest.

References

- [1] Orishadipe AT, Okogun JI, Mishelia E. Gas chromatography–mass spectrometry analysis of the hexane extract of *Calliandra portoricensis* and its antimicrobial activity. *Afr J Pure Appl Chem* 2010; **4**(7): 131–134.
- [2] Ness AR, Powles JW. Fruit and vegetables, and cardiovascular disease: a review. *Int J Epidemiol* 1997; **26**: 1–13.
- [3] Mahanta RK, Rout SD, Sahu HK. Ethnomedicinal plant resources of Similipal Biosphere Reserve, Orissa, India. *Zoos Print J* 2006; **21**(8): 2372–2374.
- [4] Steinmetz KA, Potter JD. Vegetables, fruit, and cancer prevention: a review. *J Am Diet Assoc* 1996; **96**: 1027–1039.
- [5] Akah PA, Nwaiwu JI. Anticonvulsant activity of root and stem extracts of *Calliandra portoricensis*. *J Ethnopharm* 1988; **22**(2): 205–210.
- [6] Aguwa CN, Lawal AM. Pharmacologic studies on the active principles of calliandra portoricensis leaf extract. *J Ethnopharmacol* 1988; **1**(22): 63–71.
- [7] Moharram FA, Marzouk MSA, Ibrahim MT, Marby TJ. Antioxidant galloylated flavanol glycosides from *Calliandra haematocephala*. *Nat Prod Res* 2006; **20**: 927–934.
- [8] Evans MD, Cooke MS. Factors contributing to the outcome of oxidative damage to nucleic acids. *Bioessays* 2004; **26**(5): 533–542.
- [9] Floriano–Sa´nchez E, Villanueva C, Medina–Campos ON, Rocha D, Sa´nchez–Gonz´alez DJ, Ca´rdenas–Rodr´iguez N, et al. Nordihydroguaiaretic acid is a potent *in vitro* scavenger of peroxynitrite, singlet oxygen, hydroxyl radical, superoxide anion, and hypochlorous acid and prevents *in vivo* tyrosine nitration in lung. *Free Radic Res* 2006; **40**: 523–533.
- [10] Gems D, Partridge L. Stress–response hormesis and aging: that which does not kill us makes us stronger. *Cell Metab* 2008; **7**(3): 200–203.
- [11] Ofusori DA, Adelakun AE, Ayoka AO, Oluwayinka OP, Omotoso EO, Odukoya SA, et al. Waterleaf (*Talinum triangulare*) enhances cerebral functions in Swiss albino mice. *J Neurol Sci Turk* 2008; **25**(4): 239–246.
- [12] de Diego–Otero Y, Romero–Zerbo Y, el Bekay R, Decara J, Sanchez L, Rodriguez–de Fonseca F, et al. Alpha–tocopherol protects against oxidative stress in the fragile X knockout mouse: an experimental therapeutic approach for the Fmr1 deficiency. *Neuropsychopharmacology* 2009; **34**(4): 1011–1026.
- [13] Thring TS, Hili P, Naughton DP. Anti–collagenase, anti–elastase and anti–oxidant activities of extracts from 21 plants. *BMC Complement Altern Med* 2009; **9**: 17–27.
- [14] Chen LH, Xi S, Cohen DA. Liver antioxidant defense in mice fed ethanol and the AIN–76A diet. *Alcohol* 1995; **12**: 453–457.
- [15] Somani SM. Exercise, drugs and tissue specific antioxidant system. In: Somani SM. (ed.) *Pharmacology in exercise and sports*. Boca Raton: CRC Press; 1996, p. 57–95.
- [16] Donald RB, Cristobal M. Antioxidant activities of flavonoids. *J Agric* 2006; **52**: 125–757.
- [17] Ricci D, Giamperi L, Bucchini A. Antioxidant activity of *Punica granatum* fruits. *Fitoterapia* 2006; **77**: 310–312.
- [18] Aqil F, Ahmad I, Mehmood Z. Antioxidant and free radical scavenging properties of twelve traditionally used Indian medicinal plants. *Turk J Biol* 2006; **30**: 177–183.
- [19] Kamuren Z, Sanders R, Watkins JB. Low–carbohydrate diet and oxidative stress in diabetic and nondiabetic rats. *J Biochem Mol Toxicol* 2006; **20**: 259–269.
- [20] Cipriani T, Mellinger C, de Souza L, Baggio C, Freitas C, Marques M, et al. Acidic heteroxylans from medicinal plants and their anti–ulcer activity. *Carbohydr Polym* 2008; **74**: 274–278.
- [21] Yazdanparast R, Bahramikias S, Ardestani A. *Nasturtium officinale* reduces oxidative stress and enhances antioxidant capacity in hypercholesterolaemic rats. *Chem Biol Interact* 2008; **172**: 176–184.
- [22] Hussein MA, Othman SM. Structure antioxidant activity relationship and free radical scavenging capacity of hesperidin. *IJPP's J Med Chem* 2010; **10**: 1–14.
- [23] Mahapatra SK, Das S, Bhattacharjee S, Gautam N, Majumdar S, Roy S. *In vitro* nicotine–induced oxidative stress in mice peritoneal macrophages: a dose–dependent approach. *Toxicol Mech MethodS* 2009; **19**: 100–108.
- [24] Chandran K, Venugopal PM. Modulatory effects of curcumin on lipid peroxidation and antioxidant status during nicotine induced toxicity. *Pol J Pharmacol* 2004; **56**: 581–586.
- [25] Ojiako OA, Nwanjo HU. Is *Vernonia amygdalina* hepatotoxic or hepatoprotective? Response from biochemical and toxicity studies in rats. *Afr J Biotechnol* 2006; **5**(18): 1648–1651.