




Contents lists available at ScienceDirect

Asian Pacific Journal of Tropical Biomedicine

journal homepage: www.elsevier.com/locate/apjtb



Document heading doi:10.1016/S2221-1691(11)60013-0 © 2011 by the Asian Pacific Journal of Tropical Biomedicine. All rights reserved.

Hepatoprotective activity of Hepax–A polyherbal formulation

VC Devaraj^{1*}, B Gopala Krishna², GL Viswanatha³, Jagadish V Kamath¹, Sanjay Kumar¹¹Department of Pharmacology, Krupanidhi College of Pharmacy, Bangalore, India²Department of Pharmacognosy, RR College of Pharmacy, Bangalore, India³Department of Pharmacology, PES College of Pharmacy, Bangalore, India

ARTICLE INFO

Article history:

Received 15 February 2011

Received in revised form 27 February 2011

Accepted 20 March 2011

Available online 1 April 2011

Keywords:

Hepax

Paracetamol

CCl₄

Thiocetamide

Hepatotoxicity

ABSTRACT

Objective: To evaluate the hepatoprotective potential of Hepax, a polyherbal formulation, against three experimentally induced hepatotoxicity models in rats. **Methods:** Hepatoprotective activity of Hepax was studied against three experimentally induced hepatotoxicity models, namely, carbon tetrachloride (CCl₄), paracetamol and thiocetamide induced hepatotoxicity in rats. **Results:** Administration of hepatotoxins (CCl₄, paracetamol and thiocetamide) showed significant morphological, biochemical and histological deteriorations in the liver of experimental animals. Pretreatment with Hepax had significant protection against hepatic damage by maintaining the morphological parameters (liver weight and liver weight to organ weight ratio) within normal range and normalizing the elevated levels of biochemical parameters (SGPT, SGOT, ALP and total bilirubin), which were evidently showed in histopathological study. **Conclusions:** The Hepax has highly significant hepatoprotective effect at 100 and 200 mg/kg, *p.o.* on the liver of all the three experimental animal models.

1. Introduction

Liver is an organ of paramount importance, which plays a pivotal role in regulating various physiological processes in the body, such as metabolism, secretion and storage. It has great capacity to detoxify toxic substances and synthesize useful principles. The damage to the liver caused by hepatotoxic agents is of grave consequences^[1]. In spite of tremendous scientific advancement in the field of hepatology in recent years, liver problems are in rise. Jaundice and hepatitis are two major hepatic disorders that account for the high death rate^[2].

There are potent indigenous herbal medicines available for the treatment of liver disorders in various parts of the world and most of them have not yet scientifically been validated. If they are conducted, it could lead to the development of cost effective drugs^[3]. In absence of a reliable liver protective drug in the modern system of medicine, a number of medicinal preparations in ayurveda are recommended for the treatment of liver disorders^[4]. Natural remedies from medicinal plants are considered to be effective and safe alternative treatment for liver diseases.

At present there are various polyherbal formulations available in the market for the treatment of liver diseases, such as Liv-42, Liver cure, Livol, Hepatomed, Jigrine, Tefroli, Stimuliv, Liv-52, Livfit, Livomyn, Silybon and Livogen^[5]. Hepax is one of such polyherbal formulation that consists of *Plumbago zeylanica* (Chitraka), *Picrorrhiza kurroa* (Katuka), *Piper nigrum* (Maricha), *Zingiber officinale* (Ardra), *Sodii carbonas impura* (Sajjakshara), *Phyllanthus emblica* (Amalaki), *Terminalia chebula* (Haritaki), *Calcii oxidum* (Chuna) and *Potassii carbonas impura* (Yavakshara). It is used as hepatostimulant, hepatoprotective, hepatoregenerative and offers a comprehensive coverage for the treatment of virtually every manifestation of liver dysfunction. But there is no scientific evidence for its hepatoprotective activity. Hence the present study was undertaken to explore the key behind the use of Hepax as a hepatoprotective formulation against various experimentally induced hepatotoxicity models.

2. Materials and methods

2.1. Drugs and chemicals

Silymarin were from Micro labs, Bangalore and Hepax tablets were from Anglo–French Drug Industries Ltd, Bangalore. All biochemical kits were purchased from

*Corresponding author: VC Devaraj, Department of Pharmacology, Krupanidhi College of Pharmacy, Bangalore–560035 Karnataka, India.
Tel: +919900774992; +919844492334
E-mail: devcolgy@yahoo.com; glv_000@yahoo.com

span diagnostics Ltd Surat, India. All other chemicals and reagents were of analytical grade and purchased from local firms.

2.2. Formulation of Hepax

Each tablet of Hepax contains 325mg of active ingredients. It was powdered and suspended in 0.5% Corboxy methyl cellulose (CMC) in distilled water, and then administered to animals with the help of rat oral gavaging needle.

2.3. Experimental animals

Male wistar albino rats of 200–230 g were acclimatized for 7 days under standard husbandry conditions, *i.e.*, room temperature of (26±10) °C, relative humidity of 45%–55% and light: dark cycle of 12:12 h. All the experimental protocols were approved by the Institutional Animal Ethics Committee (IAEC) of Krupanidhi College of Pharmacy, Bangalore, and conducted according to the Committee for the Purpose of the Control and Supervision of Experiments on Animals (CPCSEA) guidelines.

2.4. Hepatoprotective activity

Hepatoprotective effect of the Hepax was demonstrated by using three experimentally induced hepatotoxicity models.

2.4.1. Carbon tetrachloride (CCl₄) induced acute hepatotoxicity in rats

Wistar rats of 200–230 g were divided in to five groups with six animals each (*n*=6). Group-1 and group-2 were served as normal control and disease control respectively. Group-3, 4 and 5 corresponded to reference standard (Silymarin –100 mg/kg/day, *p.o.*, Hepax-100 mg/kg and Hepax-200mg/kg respectively). The treatment lasted for 7 days and on the seventh day's night all the animals were fasted for 12 hrs. Then all the animals except those in group-1 were treated with 1 mL of CCl₄ in liquid paraffin (1:1). 24 hrs after CCl₄ administration, body weight was recorded and blood samples were collected for the estimation of biochemical parameters, namely, SGPT, SGOT, ALP and total bilirubin. All the animals were sacrificed and the liver weight was recorded. Liver tissues collected were subjected to histopathology^[6].

2.4.2. Paracetamol induced hepatotoxicity in rats

Wistar rats of 200–230 g were divided into five groups with six each (*n*=6). Group 1 and group 2 were served as normal control and disease control respectively. Group 3, 4 and 5 corresponded to reference standard (Silymarin –100mg/kg/day, *p.o.*, Hepax-100 mg/kg and Hepax-200mg/kg respectively). The treatment was carried out for 7 days and on seventh day's night all the animals were fasted for 12 hrs and all the animals except those in group 1 were treated with paracetamol (2 g/kg, *p.o.*) in sucrose solution (40% v/v) in three divided doses. 48 hrs after paracetamol administration, body weight was documented and blood samples were collected for the estimation of biochemical parameters, namely, SGPT, SGOT, ALP and total bilirubin. All the animals

were sacrificed and the liver weight was recorded. Liver tissues collected were subjected to histopathology^[6].

2.4.3. Thiocetamide induced hepatotoxicity in rats

Wistar rats of 200–230 g were divided into five groups with six each (*n*=6). Group 1 and group 2 were served as normal control and disease control respectively. Group 3,4 and 5 were respectively as reference standard (Silymarin –100mg/kg/day, *p.o.*), Hepax-100 mg/kg and Hepax-200mg/kg. The treatment lasted for 7 days and on seventh day's night all the animals were fasted for 12 hrs and all the animals except those in group 1 were treated with thiocetamide (100 mg/kg, *s.c.*) in double distilled water. 48 hrs after thiocetamide administration, body weight was documented and blood samples were collected for the estimation of biochemical parameters, namely, SGPT, SGOT, ALP and total bilirubin. All the animals were sacrificed and the liver weight was documented. Liver tissues collected were subjected to histopathology^[6].

2.5. Statistical analysis

Values were expressed as mean±SEM. Statistical difference in mean was analyzed using one way ANOVA and followed by Turkey's multiple comparison tests. *P*< 0.05 were considered statically significant.

3. Results

3.1. Effect of Hepax against CCl₄- induced hepatotoxicity in rats

CCl₄ *per se* treated animals showed significant elevation of serum biochemical parameters, such as SGPT, SGOT, ALP and total bilirubin. The liver weight and the ratio of liver weight to body weight were increased compared with normal control group, and the pathological lesions of the liver were evident. Pretreatment with Silymarin (100 mg/kg, *p.o.*) and Hepax at 100 and 200 mg/kg, *p.o.* for 7 days, had produced significant protective effect on CCl₄-induced hepatic damage by maintaining the morphological changes (liver weight and liver to body weight ratio) and normalizing the elevation of serum biochemical parameters (SGPT, SGOT, ALP and total bilirubin), and therefore inhibited the histopathological abnormalities caused by CCl₄. Hepax showed dose dependent protection against CCl₄ induced hepatic damage (Table 1 & Figure 1).

3.2. Effect of Hepax against paracetamol – induced hepatotoxicity in rats

Administration of paracetamol *per se* at a dose of 2 g/kg, *p.o.* showed cetrilobular necrosis in histopathological studies in animals and its association with elevation of serum biomarkers for liver functions, such as SGPT, SGOT, ALP and total bilirubin. The liver weight and the ratio of liver weight to body weight were increased. Pretreatment with Hepax at 100 mg/kg and 200 mg/kg, *p.o.* for 7 days offered

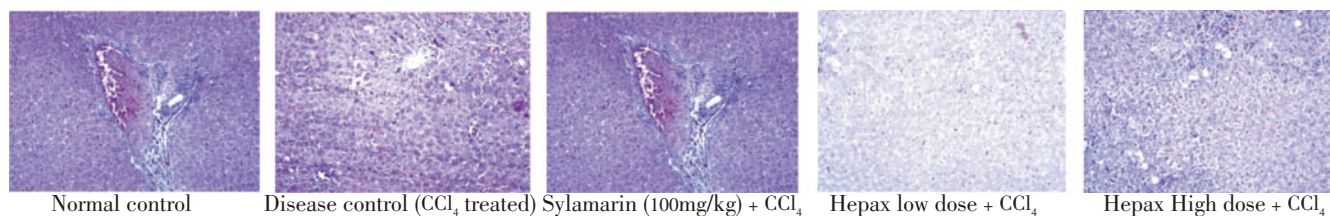


Figure 1. Effect of Hepax on CCl₄ – induced hepatotoxicity in rats (histopathology).

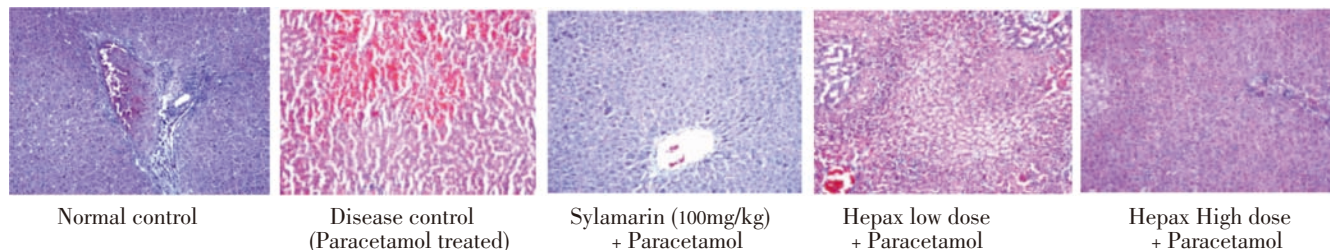


Figure 2. Effect of hepax on paracetamol – induced hepatotoxicity in rats (histopathology).




Figure 3. Effect of Hepax on thiocetamide–induced hepatotoxicity in rats (histopathology).

Table 1
Effect of Hepax on CCl₄ – induced hepatotoxicity in rats.

Group	Body weight		Liver weight(g)	Liver weight to body weight ratio (%)	Serum biochemical parameters			
	Initial	Before acrifice			SGPT	SGOT	ALP	Bilirubin
G1	218.33±13.2	222.17±14.3	6.78±0.07	3.05±0.05	53.52±1.3	160.3±19.10	430.5±41.4	0.28±0.02
G2	217.17±15.3	220.50±12.7 ^{ns}	8.87±0.18 ^ε	4.02±0.09 ^ε	636.0±24.5 [*]	358.5±21.46 [*]	668.2±18.6 [*]	0.63±0.04 [*]
G3	216.33±14.7	218.36±12.8 ^{ns}	6.80±0.18 ^b	3.11±0.09 ^b	192.2±14.6 ^{ε,b}	587.0±17.76 ^{ε,b}	501.0±47.8 ^a	0.60±0.062 [*]
G4	217.50±17.3	220.50±16.9 ^{ns}	7.20±0.26 ^b	3.27±0.12 ^b	331.5±9.9 ^{ε,b,ψ}	563.5±17.81 ^{ε,b,ψ}	393.0±18.3 ^b	0.70±0.05 [*]
G5	218.00±15.3	229.50±15.4 ^{ns}	7.12±0.21 ^b	3.23±0.08 ^b	71.5±3.1 ^{b,ψ}	149.2±17.83 ^{b,ψ}	438.0±42.6 ^a	0.67±0.03 [*]

G1: Normal Control, G2: Disease control (CCl₄), G3: Sylamarin (100 mg/kg, *p.o.*) + CCl₄, G4: Hepax (100 mg/kg, *p.o.*) + CCl₄, G5: Hepax (200 mg/kg, *p.o.*) + CCl₄. All values are Mean ± SEM, n = 6. * P < 0.05 when compared with normal group. ε P < 0.01 when compared with normal control group, a P < 0.05 when compared with disease control group and b P < 0.01 when compared with disease control group, ψ P < 0.01 when compared with Sylamarin treated group.

Table 2
Effect of hepax on paracetamol – induced hepatotoxicity in rats.

Group	Body weight		Liver weight(g)	Liver weight to body weight ratio (%)	Serum biochemical parameters			
	Initial	Before acrifice			SGPT	SGOT	ALP	Bilirubin
G1	219.00±13.8	223.00±13.8	6.78±0.07	3.04±0.06	53.52±1.30	160.3±19.10	430.5±41.40	0.28±0.02
G2	212.00±14.1	215.17±13.3 ^{ns}	8.32±0.13 ^ε	3.87±0.11 ^ε	383.3±20.40 ^ε	648.5±26.09 ^ε	768.0±34.86 ^ε	1.7±0.21 ^ε
G3	215.33±12.5	219.00±12.3 ^{ns}	6.29±0.12 ^b	2.98±0.04 ^b	76.5±5.25 ^b	188.2±8.40 ^b	435.3±8.21 ^b	0.24±0.05 ^b
G4	218.00±14.16	222.10±12.9 ^{ns}	7.39±0.14 ^b	3.33±0.09 ^b	116.5±11.27 ^a	238.2±17.40 ^a	573.0±20.48 ^a	0.60±0.03 ^b
G5	209.83±13.7	213.50±13.4 ^{ns}	6.77±0.16 ^b	3.18±0.10 ^b	68.03±3.40 ^{b,ψ}	170.3±21.8 ^{b,ψ}	411.3±10.21 ^b	0.49±0.02 ^b

G1: Normal Control, G2: Disease control (CCl₄), G3: Sylamarin (100 mg/kg, *p.o.*) + CCl₄, G4: Hepax (100 mg/kg, *p.o.*) + CCl₄, G5: Hepax (200 mg/kg, *p.o.*) + CCl₄. All values are Mean ± SEM, n = 6. * P < 0.05 when compared to Normal group. ε P < 0.01 when compared to normal control group, a P < 0.05 when compared with disease control group and b P < 0.01 when compared with disease control group, ψ P < 0.01 when compared with Sylamarin treated group.

Table 3

Effect of hepax on thiocetamide – induced hepatotoxicity in rats.

Group	Body weight		Liver weight(g)	Liver weight to Body weight ratio(%)	Serum biochemical parameters			
	Initial	Before acrifice			SGPT	SGOT	ALP	Bilirubin
G1	216.13±12.5	218.86±12.3	6.78±0.07	3.10±0.05	53.52±1.3	160.3±19.10	430.5±41.4	0.28±0.02
G2	218.35±14.1	220.83±13.9 ^{ns}	8.82±0.17 ^ε	3.99±0.01 ^ε	354.01±20.01 ^ε	438.3±10.80 ^ε	774.0±26.12 ^ε	0.86±0.08 ^ε
G3	217.83±12.6	221.42±12.1 ^{ns}	6.62±0.15 ^b	3.00±0.04 ^b	186.41±4.06 ^b	179.2±6.51 ^b	417.62±5.94 ^b	0.23±0.08 ^b
G4	221.10±13.2	224.32±13.6 ^{ns}	6.88±0.14 ^b	3.07±0.03 ^{b,Ψ}	271.67±15.71 ^a	346.03±17.83 ^a	631.02±12.26 ^a	0.59±0.02 ^a
G5	216.52±11.5	213.83±12.8 ^{ns}	6.21±0.13 ^b	3.00±0.05 ^{b,Ψ}	206.80±20.16 ^b	290.3±15.97 ^b	493.5±19.69 ^b	0.42±0.03 ^b

G1: Normal Control, G2: Disease control (CCl₄), G3: Sylmarin (100 mg/kg, *p.o.*) + CCl₄, G4: Hepax (100 mg/kg, *p.o.*) + CCl₄, G5: Hepax (200 mg/kg, *p.o.*) + CCl₄, ns: not significant.

All values are Mean±SEM, *n* = 6. * *P* < 0.05 when compared with normal group, ^ε *P* < 0.01 when compared with normal control group, ^a *P* < 0.05 when compared with disease control group and ^b *P* < 0.01 when compared with disease control group, ^Ψ *P* < 0.01 when compared with Sylmarin treated group.

significant protection against paracetamol–induced hepatic damage by inhibiting the morphological changes (liver weight and liver to body weight ratio) and maintaining the serum biochemical parameters (SGPT, SGOT, ALP and total bilirubin). Histopathological analysis demonstrated that the pathological lesions caused by paracetamol were very minimal in Hepax pretreated groups. Hepax showed dose dependent protection against paracetamol–induced hepatic damage and the protective effect of Hepax–200 mg/kg, *p.o.* was comparable with sylmarin–100 mg/kg, *p.o.* (Table 2 & Figure 2).

3.3. Effect of Hepax against thiocetamide – induced hepatotoxicity in rats

Thiocetamide–induced hepatotoxicity is a well established animal model for studying the hepatoprotective property. 48 hrs after the administration of thiocetamide at 100 mg/kg, *s.c.* showed significant elevation of serum biochemical parameters, such as SGPT, SGOT, ALP and total bilirubin. The liver weight and the ratio of liver weight to body weight were increased compared with normal control group and the pathological lesions of the liver were evident. Pretreatment with Sylmarin (100 mg/kg, *p.o.*) and Hepax at 100 and 200 mg/kg, *p.o.* for 7 days, offered significant protection against thiocetamide–induced hepatic damage by inhibiting the morphological changes (liver weight and liver to body weight ratio) and maintaining serum biochemical parameters (SGPT, SGOT, ALP and total bilirubin). Thus it significantly inhibited the histopathological abnormalities caused by thiocetamide. Hepax showed dose dependent protection against thiocetamide– induced hepatic damage (Table 3 & Figure 3).

4. Discussion

Liver is one of the vital organs of the animal body and plays a central role in transforming and clearing the chemicals, but it is susceptible to the toxicity from these agents. Certain medicinal agents, like paracetamol, when taken in overdoses or sometimes even within therapeutic ranges, may damage the liver. Other chemical agents, such as those used in laboratories and industries, natural chemicals (*e.g.* microcystins) and herbal remedies can also induce hepatotoxicity. Chemicals that cause liver injury are called hepatotoxins[7]. More than 900 drugs have been implicated in causing liver injury[7] and it is one of the

most common reasons for a drug to be withdrawn from the market[8].

Several mechanisms are responsible for either inducing hepatic injury or worsening the damage process. About 75%–80% of blood coming to the liver arrives directly from gastrointestinal organs and then spleen via portal veins which bring drugs and xenobiotics in concentrated form[9]. Many chemicals damage mitochondria, an intracellular organelle that produces energy. Its dysfunction releases excessive amount of oxidants which in turn damage hepatic cells. Activation of some enzymes in the cytochrome P–450 system, such as CYP2E1, also leads to oxidative stress[10]. Injury to hepatocyte and bile duct cells leads to accumulation of bile acid inside the liver, which promotes further liver damage[11]. Non–parenchymal cells, such as Kupffer cells, fat storing stellate cells and leukocytes (*i.e.* neutrophil and monocyte) also have roles in the mechanism. In present study the hepatoprotective effect of Hepax –a polyherbal formulation, was evaluated against CCl₄, paracetamol and thiocetamide induced hepatotoxicity models in rats.

In CCl₄–induced hepatotoxicity model, upon administration of CCl₄ to animals, it undergoes enzymatic activation, majorly by CYP2E1, into the trichloromethyl free radical (CCl₃) within the membrane of the endoplasmic reticulum. This is followed by chloromethylation, saturation, peroxidation and progressive destruction of the unsaturated fatty acid of the endoplasmic reticulum membrane phospholipids[12]. These processes are known as lipid peroxidation, leading to functional and structural disruption of hepatocytes[13].

During hepatic damage, cellular enzyme like SGPT, SGOT, ALP, bilirubin (Direct & Total) will leak into the serum resulting in elevation of their serum concentrations, the increase of liver weight and volume. Histopathology of the damaged liver showed histological changes, such as steatosis (fatty changes in hepatocytes) and perivenular fibrosis was observed[14].

Pretreatment with sylmarin (100mg/kg, *p.o.*) Hepax (100 and 200 mg/kg) for 7 days offered significant protection against the CCl₄ –induced hepatic damage. Both the doses of Hepax prevented the histological changes caused by CCl₄, which further confirmed its hepatoprotective activity against CCl₄ – induced hepatic damage. The possible mechanism of action may be associated with inhibition of CYP2E1 activity or scavenging of free radicals responsible for CCl₄ toxicity. Paracetamol induced hepatotoxicity is one of the well known and commonly used animal model for studying the hepatoprotective property of drugs. Administration

of paracetamol at a dose of 1–3 gm/kg/day/*p.o.* results in hepatic damage. The toxic metabolite *N*-acetyl-*p*-benzoquinimine is an oxidative product of paracetamol formed by the action of cytochrome P-450 and it reacts with reduced glutathione (GSH) to yield non-toxic 3-GS-yl-paracetamol. Depletion of GSH causes the remaining quinone to undergo covalent bonding with cellular macromolecules (sulphydryl groups of protein) and leads to cell death. Histopathology of the liver shows necrosis of the centrilobular hepatocytes characterized by nuclear pyknosis, eosinophilic cytoplasm and large excessive hepatic lesions^[15].

Pretreatment with Sylimarin (100 mg/kg, *p.o.*) and hepax (100 and 200 mg/kg, *p.o.*) for 7 days had significant protection against the paracetamol induced hepatic damage. The possible mechanism of action behind the hepatoprotective activity of Hepax in this model may be associated with the antioxidant property.

Administration of thioacetamide at 100–300 mg/kg, *i.p.* results in the hepatic damage in animals^[16,17]. The mechanism behind its toxicity is thought to be associated with its toxic metabolite (s-oxide). It interferes with the movement of RNA from the nucleus to cytoplasm which may cause membrane injury. It reduces the number of viable hepatocytes as well as rate of oxygen consumption and also decreases the volume of bile and its content, *i.e.*, bile salts, cholic acid and deoxycholic acid^[16].

The whole organ and the sections from the thioacetamide treated group showed characteristic nodules on the liver. The texture of the liver in the Sylimarin (100 mg/kg, *p.o.* for 7 days) and hepax (100 and 200mg/kg, *p.o.* for 7 days) pretreated groups was almost similar in comparison with the normal control. The serum biochemical levels and physical parameters were also found to be significantly low compared with disease control group, which indicates the hepatoprotective effect of the Sylimarin (100 mg/kg, *p.o.*) and Hepax(100 and 200 mg/kg, *p.o.*).

These results showed that Hepax at 100 mg/kg and 200 mg/kg dose levels offered significant dose dependent protection against experimentally induced hepatotoxic models. The possible mechanism behind the hepatoprotective property of Hepax may be associated with stimulation of antioxidant defence mechanism against the free radicals generated by CCl₄, paracetamol and thioacetamide or by the inhibition of cytochrome P-450 enzyme system responsible for the generation of the toxic free radicals from these chemicals.

Conflict of interest statement

We declare that we have no conflict of interest.

Acknowledgements

The authors are thankful to Prof. Suresh Nagpal, Chairman, Krupanidhi Educational Trust, Bangalore, India, Dr. Amit Kumar Das, Principal, Krupanidhi College of Pharmacy, Bangalore, India, and for their help.

References

- [1] Shanmugasundaram P, Venkataraman S. Hepatoprotective and antioxidant effects of *Hygrophila auriculata* (K. Schum) Heine Acanthaceae root extract. *J Ethnopharmacol* 2006; **104**: 124–128.
- [2] Nazeema TH, Brindha V. Antihepatotoxic and antioxidant defense potential of *Mimosapudica*. *Inter J Drug Discovery* 2009; **1**: 1–4.
- [3] Jamal AK, Yaacob WA, Laily BD. A chemical study on *Phyllanthus Columnaris*. *Eur J Scientific Research* 2009; **28**: 76–81.
- [4] Karthikeyan, Deepa K. Hepatoprotective effect of *Premna corymbosa* (Burm. f.) Rottl. & Willd. leaves extract on CCl₄ induced hepatic damage in Wistar albino rats. *Asian Pac J Trop Med* 2010; **3**(1): 17–20.
- [5] Sapakal VD, Ghadge RV, Adnaik RS, Naikwade NS, Magdum CS. Comparative hepatoprotective activity of Liv-52 and livomyn against carbon tetrachloride induced hepatic injury in rats. *Inter J Green Pharma* 2008; **2**: 79–82.
- [6] Chanchal KR, Jagadish VK, Mohammed A. Hepatoprotective activity of *Psidium guajava* Linn. Leaf extract. *Ind J Exp Biol* 2006; **44**: 305–311.
- [7] Friedman SE, Grendell JH, McQuaid KR. *Current diagnosis & treatment in gastroenterology*. New York: Lang Medical Books/McGraw–Hill; 2003.
- [8] Rajamani K, Somasundaram ST, Manivasagam T, Balasubramanian T, Anantharaman P. Hepatoprotective activity of brown alga *Padina boergesenii* against CCl₄ induced oxidative damage in Wistar rats. *Asian Pac J Trop Med* 2010; **3**(9): 696–701.
- [9] Vikramjit M, Metcalf J. Functional anatomy and blood supply of the liver. *Anaesthesia & Intensive Care Medicine* 2009; **10**: 332–333.
- [10] Jaeschke H, Gores GJ, Cederbaum AI, Hinson JA, Pessayre D, Lemasters JJ. Mechanisms of hepatotoxicity. *Toxicol Sci* 2002; **65**: 166–176.
- [11] Isabel F. Dysregulation of apoptosis in hepatocellular carcinoma cells. *World J Gastroenterol* 2009; **15**: 513–520.
- [12] Peng C, Chunying L, Wenqiang P, Yue Z, Wei D, Shiming W, et al. The protective role of *per2* against carbon tetrachloride–induced hepatotoxicity. *American J Pathol* 2009; **174**: 63–70.
- [13] Hogade MG, Patil KS, Wadkar GH, Mathapati SS, Dhupal PB. Hepatoprotective activity of *Morus alba* (Linn.) leaves extract against carbon tetrachloride induced hepatotoxicity in rats. *African J Pharma Pharmacol* 2010; **4**: 731–734.
- [14] Rajib AM, Monirul IK, Jahan BI, Ashik MM, Ekramul H. Hepatoprotective activity of methanol extract of some medicinal plants against carbon tetrachloride–induced hepatotoxicity in rats. *Eur J Scientific Res* 2009; **37**: 302–310.
- [15] Maiti K, Mukherjee K, Murugan V, Saha BP, Mukherjee PK. Enhancing bioavailability and hepatoprotective activity of andrographolide from *Andrographis paniculata*, a well-known medicinal food, through its herbosome. *J Sci Food Agric* 2010; **90**: 43–51.
- [16] Shyamal S, Latha PG, Suja SR, Shine VJ, Anuja GI, Sini S, et al. Hepatoprotective effect of three herbal extracts on aflatoxin B1–intoxicated rat Liver. *Singapore Med J* 2010; **51**: 326–331.
- [17] Shapiro H, Ashkenazi M, Weizman N, Shahmurov M, Aeed H, Bruck R. Curcumin ameliorates acute thioacetamide–induced hepatotoxicity. *J Gastroenterol Hepatol* 2006; **21**: 358–366.