



Contents lists available at ScienceDirect

Asian Pacific Journal of Tropical Biomedicine

journal homepage: www.elsevier.com/locate/apjtb



Document heading doi:10.1016/S2221-1691(12)60022-7 © 2012 by the Asian Pacific Journal of Tropical Biomedicine. All rights reserved.

Enhancement of wound healing with roots of *Ficus racemosa* L. in albino rats

Krishna Murti^{1*}, Upendra Kumar²¹Singhania University, Jhunjhunu, Rajasthan, India²College of Pharmacy, Azamgarh, Uttar Pradesh, India

ARTICLE INFO

Article history:

Received 15 October 2011

Received in revised form 10 November 2011

Accepted 3 December 2011

Available online 28 April 2012

Keywords:

Ficus racemosa

Incision

Excision

Phytochemical analysis

Povidone iodine

ABSTRACT

Objective: To establish the wound healing activity of aqueous and ethanolic extract of roots of *Ficus racemosa* (*F. racemosa*). **Methods:** Two models were performed to evaluate the wound healing activity *i.e.* incision and excision models. In incision model the parameter which was carried out was breaking strength of wounded skin. In excision model percentage wound contraction and period of epithelialization were established for both the extracts. Reference standard drug was povidone iodine ointment for comparison with other groups. **Results:** From the observation in both two models, aqueous extract of *F. racemosa* was found to have greater wound healing activity in terms of breaking strength in incision model and percentage wound contraction, period of epithelialization in excision model than that of other groups. **Conclusions:** In conclusion, our findings suggest that aqueous extract of *F. racemosa* possesses better wound healing ability than the ethanolic extract.

1. Introduction

The wound repair process has three orderly but temporally overlaid stages *i.e.* inflammation, cell proliferation and tissue regeneration[1]. Wound healing is a process which is fundamentally a connective tissue response. Initial stage of this process involves an acute inflammatory phases followed by synthesis of collagen and other extracellular macromolecules which are later remolded to form scars[2]. Therefore, tissue repair and wound healing are the complex processes that involve a series of biochemical and cellular reactions[3–5]. There are several reports stating that the extracts of several plants have wound healing properties[3,6,7].

Some plants possessing prohealing activity have been scientifically analyzed. *Tridax procumbens*, *Trigonella foenumgraecum*, *Leucas lavandulaefolia* and *Aloe vera* have shown promising wound healing activity[8].

Ficus racemosa (*F. racemosa*) Linn (Moraceae) is an

evergreen, moderate to large sized spreading, lactiferous, deciduous tree, without much prominent aerial roots found throughout greater part of India in moist localities and is often cultivated in villages for its edible fruit. The astringent nature of the bark has been employed as a mouth wash in spongy gum and also internally in dysentery, menorrhagia and haemoptysis. All parts of this plant (leaves, fruits, bark, latex, and sap of the root) are medicinally important in the traditional system of medicine in India. The leaves powdered and mixed with honey are given in bilious infections. The bark is antiseptic, antipyretic and vermifugal, and the decoction of bark is used in the treatment of various skin diseases, ulcers and diabetes. It is also used as a poultice in inflammatory swellings/boils and is regarded to be effective in the treatment of piles, dysentery, asthma, gonorrhoea, gleet, leucorrhoea and urinary diseases[9]. Very little phytochemical work has been carried out on *F. racemosa*. Many bioactive compounds have been isolated from *F. racemosa*, *e.g.*, campesterol, hentriacontane, hentriacontanol, kaempferol, stigmaterol, methyl ellagic acid from stems, tetra triterpene, glauanol acetate, racemosic acid from leaves, glauanol, hentriacontane, β -sitosterol, glauanolacetate, glucose, tiglic acid, esters of taraxasterol, lupeolacetate, friedelin, higher hydrocarbons

*Corresponding author: Krishna Murti, Research Scholar, Singhania University, Jhunjhunu, Rajasthan, India.

Tel: +91-9050005154

E-mail: krishnamurti74@yahoo.co.in

Foundation Project: This work was financially supported by Vidyabharti Trust College of Pharmacy, Surat, India (grant No. VBT/IAEC/11/05/45).

and other phytosterol from fruit, cycloartenol, euphorbol and its hexacosanoate, taraxerone, tinyatoxin from root, euphorbol and its hexacosanoate, ingenol and its triacetate, taraxerone from bark^[10,11]. The scientific study of the roots of *F. racemosa* in wound healing has not been investigated so far. Therefore, the present study was designed to determine the healing activity of roots in the wound model in rats.

2. Materials and methods

2.1. Plant collection

Roots of *F. racemosa* L. growing in natural habitat in Modasa, Gujarat, India, were collected in October, 2010 and identified by associate professor Dr. MS Jangid, Department of Botany, Modasa, Hemchandra Gujarat University by carrying out macroscopic and microscopic evaluation and were submitted to the institute for future reference purpose.

2.2. Preparation of the root extract

Dried and coarsely (500 g) powdered roots of *F. racemosa* were extracted with 90% (v/v) ethanol in Soxhlet apparatus for 36 h and aqueous extract was prepared by using maceration technique of extraction. The filtrate was filtered and concentrated on water bath using petridish. The temperature was maintained at 55 °C. The powdered extract was dried and weighed^[12].

2.3. Preliminary phytochemical analysis

Preliminary phytochemical studies were performed for testing different chemical groups present in ethanolic and aqueous extracts^[13–15].

2.4. High performance thin layer chromatography (HPTLC) profile

Chromatography was performed on (3 cm × 10 cm) HPTLC plates coated with 0.25 mm layer of silica gel 60 F254 (Merck, Germany). Before using, the plates were washed with methanol and activated at 110 °C for 5 min. Samples were applied as 4 mm wide bands and 6 mm apart by using a Camag (Muttentz, Switzerland) Linomat IV sample applicator equipped with 100 µL syringe. A constant application rate of 5 µL/sec was used.

2.5. Animals

Wistar albino rats of either sex weighing between (180–200 g) were obtained from Jai Foundation Research, Vapi (Gujarat). The study was approved by the Institutional Ethics Committee for animal experimentation, Vidyabharti Trust College of Pharmacy, Umrah, Gujarat (VBT/IAEC/11/05/45) and all the procedures on animals were carried out as per CPCSEA guidelines, India. These animals were used for the wound healing activity studies. The animals were stabilized for 1 week. They were maintained

in standard conditions at room temperature, (60±5)% relative humidity and 12 h light dark cycle. They were given standard pellet diet and water *ad libitum* throughout the course of the study. The ethanolic and aqueous extracts of *F. racemosa* were administered topically to all groups of animals.

2.6. Incision wound model

The rats were anesthetized by administering ketamine (0.5 mL/kg b.w. i.p.). Incision wounds of about 6 cm in length and 2 mm in depth were made with sterile scalpel on the shaved back of the rats 30 min after the administration of ketamine injection. The parted skin was kept together and stitched with black silk at 0.5 cm intervals. Surgical thread (no. 000) and a curved needle (no. 9) were used for stitching. The continuous thread on both wound edges was tightened for good closure of the wounds. The wounds of animals in the different groups were treated with drug topically for a period of 10 days. Rats were divided into four groups with 6 in each group. Rats in group 1 were topically treated with simple ointment and served as control; rats in group 2 were topically treated with povidone iodine ointment; and rats in group 3 and 4 were topically treated with aqueous and ethanolic extract of *F. racemosa*, respectively. The wounding day was considered as day 0. When wounds were cured thoroughly, the sutures were removed on the 8th post-wounding day and the tensile strength of the skin that is the weight in grams required to break open the wound/skin was measured by tensiometer on the 10th day^[16–20].

2.7. Excision wound model

A standard wound of uniform 2 cm diameter was formed with the aid of a round seal^[21–24]. The treatment to the excision wounds of the rats was the same as described above. The percentage wound closure, epithelization time and scar area on complete epithelization were measured.

2.8. Histopathological examinations

Specimen samples of skin tissues from control, standard and treated groups were taken out from the healed wounds of the animals in excision and incision wound models for histopathological examinations. The thin sections were cut and stained with haematoxylin and eosin^[25–27] and observed under microscope for the histopathological changes such as fibroblast proliferation, collagen formation.

2.9. Statistical analysis

The mean value ± SEM was calculated for each parameter. Results were statistically analyzed by one-way-analysis of variance (ANOVA) followed by *post hoc* Dunnett's test. $P < 0.05$ was considered as significant.

3. Results

Table 1

Percentage wound contraction and period of epithelialization in excision wound model (mean±SE) (n=6).

Groups	% Wound contraction in days					Period of epithelialization (days)
	Day 2	Day 4	Day 8	Day 12	Day 16	
Control (simple ointment) (topically)	4.16±3.87	11.83±2.24	30.00±1.23	50.00±2.54	60.00±1.32	21.00±0.37
Povidone iodine (topically)	5.08±1.23	24.16±1.54*	53.33±3.67*	69.16±3.30*	80.83±1.23*	17.00±0.37*
<i>F. racemosa</i> aqueous extract (topically)	7.50±0.14	30.83±0.23*	63.33±0.64*	92.50±0.12*	100.00±0.00*	12.00±0.26*
<i>F. racemosa</i> ethanolic extract (topically)	5.90±0.13	27.00±2.31*	59.00±1.23*	75.00±0.32*	98.33±1.32*	15.00±0.26*

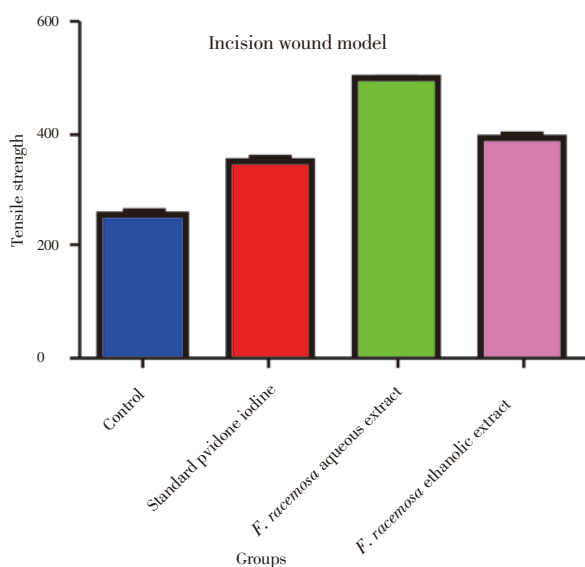
*: $P < 0.05$ when compared with control group.

3.1. Phytochemical analysis

Preliminary phytochemical screening of the extract showed that the roots of *F. racemosa* L. contain saponins, tannins, alkaloids and flavanoids while other constituents like amino acids, carbohydrate are absent. Further the presence of these chemical constituents was confirmed by HPTLC fingerprinting.

3.2. Incision wound model

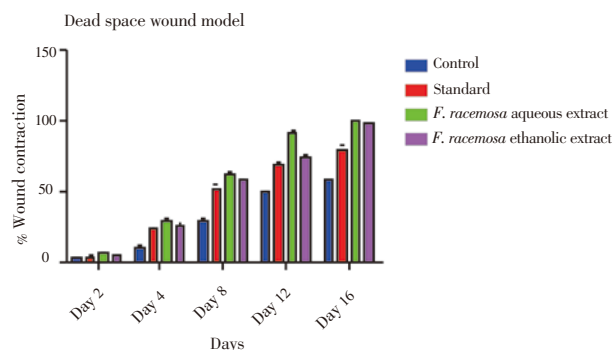
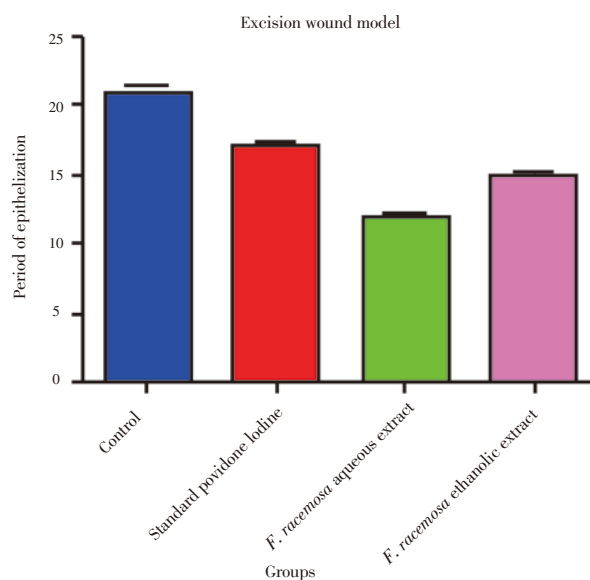
The breaking strength of the incision wounds was increased in drug treated groups to significant extent, *i.e.* (257.50±2.81) in control was increased up to (497.20±3.03) with *F. racemosa* aqueous extract, (394.70±6.61) with *F. racemosa* ethanolic extract. The results were also comparable to standard drug *i.e.* povidone iodine, with breaking strength of (352.00±2.83). The difference between rats treated with drugs and control was statistically significant ($P < 0.05$). Measurement of breaking strength in incision model was shown in Figure 1.

**Figure 1.** Measurement of breaking strength in incision model.

3.3. Excision wound model

The results of the progress of the wound healing induced by *F. racemosa* extract ointments (aqueous and ethanolic), simple ointment and povidone iodine (standard drug) were shown in Table 1, Figure 2 and 3. It was observed that the

wound contracting ability of both extracts was significantly greater than that of the control (*i.e.* simple ointment treated group). The aqueous extract ointment treated groups showed significant wound healing from the fourth day onwards, which was comparable to that of the standard drug, *i.e.* povidone iodine ointment. The wound closure time was lesser, as well as the percentage of wound contraction was much more with the aqueous extract ointment treated group [12 days for 100% contraction which was almost better than that of the povidone iodine (17 days) treated group]. Ethanolic extract ointment treated animals showed significant wound contraction from the fourth day onwards and achieved 100% contraction with the wound closure time of 14.17 days.

**Figure 2.** Measurement of percentage wound contraction in excision model.**Figure 3.** Measurement of period of epithelialization in excision model.

3.4 Histopathological examinations

In standard drug and *F. racemosa* extracts treated albino rats, excision and incision type of wounds showed significant healing as in fibroblasts cells, collagen fibres and new blood vesicles in Figure 4 and 5 while in control rats wounds showed incomplete healing in Figure 6. Control group showed the slightest wound healing ability when compared to extracts and reference ointment treated groups. Fibroblast cells, collagen fibres and blood vessels are prominently present in standard and extracts treated group as compared to control.

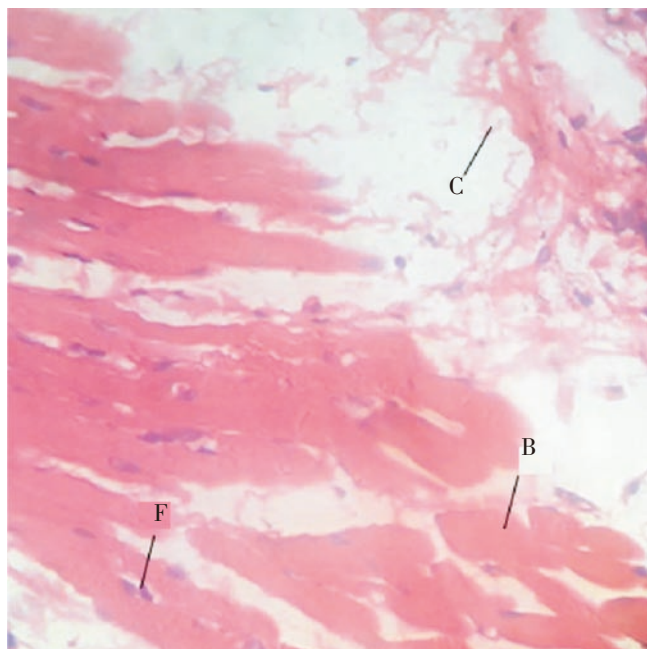


Figure 4. Histopathological characteristics of healed tissue on the 10th day by treatment with standard ointment. Figure shows increased fibroblasts cells (F), collagen fibres (C) and blood vesicles (B) in incision wound.

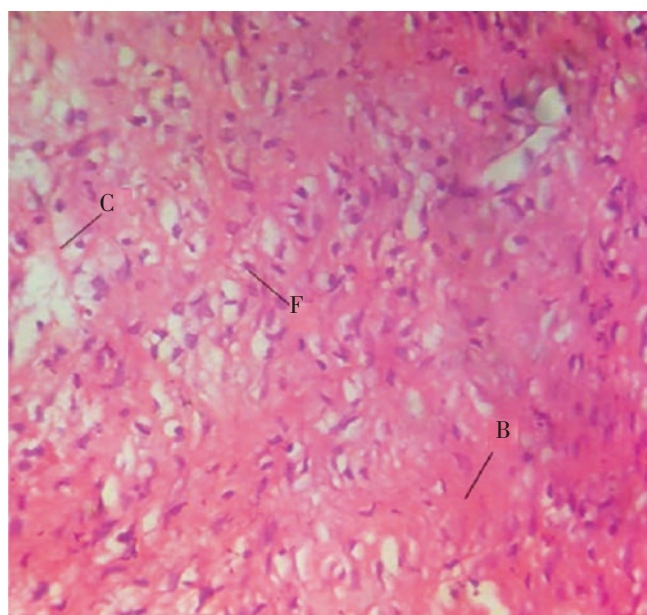


Figure 5. Histopathological characteristics of rat skin on the 10th day by treatment with *F. racemosa* extracts. Figure shows increased fibroblast cells (F), collagen fibres (C) and blood vesicles (B) in incision wound.

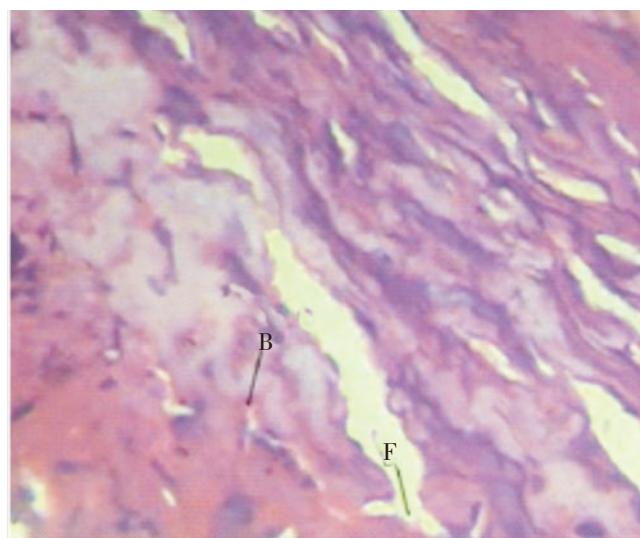


Figure 6. Histopathological characteristics of rat skin on the 10th day by treatment with ointment base. Figure shows poor fibroblast cells (F) and blood vessels (B) in incision wound.

4. Discussion

Wound healing is stepwise process, which consists of different phases such as hemostasis, inflammation, proliferative and remodeling or maturation. The genetic response regulating the body's own cellular resistance mechanisms contributes to the wound and its repair[28]. Therefore, in this study two different models were used to establish the healing potentials of aqueous and ethanolic extracts of *F. racemosa* on various phases.

In incision wound, the increase in tensile strength of treated wounds may be due to the increase in collagen concentration and stabilization of the fibres. A healing tissue synthesizes collagen, which is a constituent of growing cell[29]. Increase in blood vessels and role of antioxidants were experimentally proved[30].

From the observations, it was evident that *F. racemosa* possesses a definite potential healing action. The breaking strength of the incision wounds was increased in aqueous and ethanolic extract treated groups.

In excision wound healing model the aqueous and ethanolic extract of the root of the plant *F. racemosa* showed significant increase in percentage closure by enhanced epithelialization. This enhanced epithelialization may be due to the effect of *F. racemosa* extracts on enhanced collagen synthesis. The higher breaking strength indicates better healing of wounds. Thus it supports the wound healing activity of *F. racemosa*.

Recent studies with other plant extracts have shown that phytochemical constituents like flavanoids, alkaloids, saponins and tannins[31] are known to promote the wound-healing process. The study reveals that both aqueous and ethanolic extracts treated groups possess good wound

healing properties which may be attributed to the individual or combined action of phytoconstituents like, flavanoids, alkaloids, saponins and tannins present in it.

Conflict of interest statement

We declare that we have no conflict of interest.

Acknowledgements

The authors are thankful to the Managing Trustee and Vidyabharti Trust College of Pharmacy, Surat, India for providing financial support and facility to carry out this research.

References

- [1] Murti K, Lambole V, Panchal M, Shah M. Healing promoting potentials of roots of *Scoparia dulcis* in albino rats. *Pharmacologia* 2011; **2**(12): 369–373.
- [2] Charde RM, Dhongade HJ, Charde MS, Kasture AV. Evaluation of antioxidant, wound healing and anti-inflammatory activity of ethanolic extract of leaves of *Ficus religiosa*. *Int J Pharm Sci Res* 2010; **19**(5): 73–82.
- [3] Sadaf F, Saleem R, Ahmed M. Healing potential of cream containing extract of *Sphaeranthus indicus* on dermal wounds in Guinea pigs. *J Ethnopharmacol* 2006; **107**: 161–163.
- [4] Ayyanar M, Ignacimuthu S. Herbal medicines for wound healing among tribal people in Southern India: ethnobotanical and scientific evidences. *Int J Appl Res Nat Prod* 2009; **2**(3): 29–42.
- [5] Wild T, Rahbarnia A, Kellner M, Sobotka L, Eberlein T. Basics in nutrition and wound healing. *Nutrition* 2010; **26**: 862–866.
- [6] Süntar IP, Akkol EK, Yalçın FN, Koca U, Keleş H, Yesilada E. Wound healing potential of *Sambucus ebulus* L. leaves and isolation of an active component, quercetin 3-O-glucoside. *J Ethnopharmacol* 2010; **129**: 106–114.
- [7] Zhai Z, Haney DM, Wu L, Solco AK, Murphy PA, Wurtele ES, et al. Alcohol extract of *Echinacea pallida* reverses stress-delayed wound healing in mice. *Phytomedicine* 2009; **16**: 669–678.
- [8] Murti K, Lambole V, Gajera V, Panchal M. Exploration of healing promoting potentials of roots of *Ficus religiosa*. *Pharmacologia* 2011; **2**(12): 374–378.
- [9] Murti K, Kumar U, Lambole V. Pharmacological properties of *Ficus racemosa*—a review. *Pharmacologyonline* 2010; **2**: 802–807.
- [10] Joseph B, Raj SJ. Phytopharmacological properties of *Ficus racemosa* Linn—an overview. *Int J Pharm Sci Rev Res* 2010; **3**(2): 134–138.
- [11] Padmaa M. Phytochemicals in *Ficus racemosa*. *Nat Prod Radiance* 2009; **8**(1): 84–90.
- [12] Murti K, Kumar U. Reversal of dexamethasone depressant action in wound healing by *Ficus benghalensis* L. roots. *Am J Pharmacol Toxicol* 2011; **6**(2): 68–75.
- [13] Mohammed A. *Text book of pharmacognosy*. New Delhi: CBS Publishers and Distributors; 2006, p. 81, 116, 372, 447.
- [14] Kokane DD, More RY, Kale MB, Nehete MN, Mehendale PC, Gadgoli CH. Evaluation of wound healing activity of root of *Mimosa pudica*. *J Ethnopharmacol* 2009; **124**: 311–315.
- [15] Sachin J, Neetesh J, Tiwari A, Balekar N, Jain DK. Simple evaluation of wound healing activity of polyherbal formulation of roots of *Ageratum conyzoides* Linn. *Asian J Res Chem* 2009; **2**(2): 135–138.
- [16] Kiran K, Asad M. Wound healing activity of *Sesamum indicum* L seed and oil in rats. *Indian J Exp Biol* 2008; **46**(11): 777–782.
- [17] Zhaia Z, Haney DM. Alcohol extract of *Echinacea pallida* reverses stress-delayed wound healing in mice. *Phytomedicine* 2009; **16**: 669–678.
- [18] Pattanayaka SP, Sunita P. Wound healing, anti-microbial and antioxidant potential of *Dendrophthoe falcata* (L.f) Ettingsh. *J Ethnopharmacol* 2008; **120**: 241–247.
- [19] Nayak BS, Vinutha B, Geetha B, Sudha B. Experimental evaluation of *Pentas lanceolata* flowers for wound healing activity in rats. *Fitoterapia* 2005; **76**: 671–675.
- [20] Jagtap NS, Khadabadi SS, Farooqui IA, Nalamwar VP, Sawarkar HA. Development and evaluation of herbal wound healing formulations. *Int J Pharmtech Res* 2009; **1**(4): 1104–1108.
- [21] Deshmukha PT, Fernandes J, Atul A, Toppo E. Wound healing activity of *Calotropis gigantea* root bark in rats. *J Ethnopharmacol* 2009; **125**: 178–181.
- [22] Vinothapooshan G, Sundar K. Wound healing effect of various extracts of *Mimosa pudica*. *Pharmacologyonline* 2010; **1**: 307–315.
- [23] Adiga S, Tomar P, Rajput RR. Effect of *Punica granatum* peel aqueous extract on normal and dexamethasone suppressed wound healing in Wistar rats. *Int J Pharm Sci Rev Res* 2010; **5**(2): 34–37.
- [24] Barua CC, Telukdar A, Begum SA, Sarma DK, Pathak DC, Barua AG, et al. Wound healing activity of methanolic extract of leaves of *Alternanthera brasiliensis* Kuntz using *in vivo* and *in vitro* model. *Indian J Exp Biol* 2009; **47**: 1001–1005.
- [25] Shivhare Y, Singour PK, Patil UK, Pawar RS. Wound healing potential of methanolic extract of *Trichosanthes dioica* Roxb (fruits) in rats. *J Ethnopharmacol* 2010; **127**: 614–619.
- [26] Bhat RS, Shankrappa J, Shivakumar HG. Formulation and evaluation of polyherbal wound treatments. *Asian J Pharm Sci* 2007; **2**(1): 11–17.
- [27] Lodhi S, Singhai AK. Preliminary pharmacological evaluation of *Martynia annua* Linn leaves for wound healing. *Asian Pac J Trop Biomed* 2011; **1**: 421–427.
- [28] Charles VM, Rusell RCG, Williams NS. *Short practice of surgery*. 22nd ed. London: Champan and Hall; 2006, p. 9–11.
- [29] Pattanayak SP, Sunita P. Wound healing, anti-microbial and antioxidant potential of *Dendrophthoe falcata* (L.f) Ettingsh. *J Ethnopharmacol* 2008; **120**: 241–247.
- [30] Allen LV, Popovich NG, Ansel HC. *Ansel's pharmaceutical dosage form and drug delivery system*. Baltimore: Lippincott Williams & Wilkins; 2005, p. 278–281.
- [31] Murti K, Lambole V, Panchal M, Shah M, Gajera V. Evaluation of wound healing activity of polyherbal formulation in rats. *Res J Pharmacogn Phytochem* 2011; **3**(3): 112–115.