

Anatomical variations of caecum and appendix: A cadveric study in Mysore based population

Vidya CS^{1,*}, Vasantha Kuberappa²

¹Associate Professor, JSS Medical College, Mysore, ²Assistant Professor, Dept. of Anatomy, Karwar Institute of Medical Sciences, Karwar

Email: vidyasatish78@rediffmail.com

Abstract

Background: The caecum is the first part of the large intestine. It begins caudally from the ileocecal valve and ends blindly in the right iliac fossa. Typically the caecum is located intraperitoneally in the right lower abdomen and has a length of 5 to 7 cm. The vermiform appendix is attached dorsomedially to the end of the caecum where all three taeniae converge. It is 2 to 15 cm long and lies often intraperitoneally, variations in anatomical location of appendix can result in different clinical presentation in acute appendicitis and carcinoid tumour. The present study aims to determine the morphological variations of caecum and appendix.

Material and method: The study was carried out in 28 cadavers which were available in the department of anatomy JSS medical college. The shape of the caecum, morphometry and ileal opening into caecum was noted, the position and length of appendix was also observed.

Results: The shape of the caecum was adult in 21 specimens 75% and in 25 specimens ileum opened posteromedially to caecum (89.2%) Fig 1 in 3 specimen's ileum opened anteromedially to caecum.

Conclusion: The identification of caecum and appendix is first step in appendectomy either in open or laproscopic surgery. The anatomical variations of caecum and appendix is important for surgical gastroenterologists.

Keywords: Caecum, Appendix, Appendicitis, Appendectomy, Anatomical variations

Access this article online	
Quick Response Code:	Website: www.innovativepublication.com
	DOI: 10.5958/2394-2126.2016.00059.1

Introduction

Caecum begins caudally from the ileocecal valve and ends blindly in the right iliac fossa. Typically the caecum is located intraperitoneally in the right lower abdomen and has a length of 5 to 7 cm. Due to an incomplete rotation of the umbilical loop during embryogenesis however it may lie quite variably. Therefore clinically one differentiates between three important variations: mobile caecum (completely covered by peritoneum), free caecum (with its own mesocaecum) and fixed caecum (secondary retroperitoneal). The vermiform appendix is attached dorsomedially to the end of the caecum where all three taeniae converge. It is 2 to 15 cm long and lies often intraperitoneally retrocaecal (65%) or in the lesser pelvis (30%). The appendix is attached to the posterior abdominal wall by the mesoappendix.¹

During embryonic development of appendix, the position in the abdomen is not constant. Depending upon stage of development and rotation of gut, appendix is found at different locations in the abdominal cavity.² Vermiform appendix has greater

clinical significance as it is involved in different disease process such as appendicitis, carcinoma and diverticulitis. Inflammation of appendix is the most common cause of emergency laparotomy.³ There is no definite rule about the position of the vermiform appendix, but it is thought that the position of the vermiform appendix is closely related to the development of caecum.⁴

Inflammation of the appendix resulting in acute appendicitis is a common cause for acute abdomen in young adults. If diagnosed late, it results in increased morbidity and mortality rates.⁵ The present study was carried out in cadavers of Mysore based population to determine type and morphometry of caecum and appendix. Thorough knowledge of variations of caecum and appendix will help in identifying the appendix in case of laprotomy or laproscopic surgeries. Very few studies on caecum and appendix is done among South Indian population and in Mysore based population. The present study attempts to enlighten the anatomical variations of caecum and appendix which aids surgeons in performing various abdominal operations in adults and children.

Material and Method

The study was conducted on 28 cadavers which were available in the department of anatomy JSS medical college. The shape of the caecum and peritoneal relation was noted. The opening of ileum into caecum was observed by opening the right wall of the caecum. The length, breadth of caecum was measured using divider and measuring scale. The

position and peritoneal relation of appendix was noted, the length of appendix was measured using thread and measuring scale, the position of the appendix was confirmed by the direction of the tip of the appendix.

Results

The shape of the caecum was adult in 21 specimens 75% and in 25 specimen's ileum opened posteromedially to caecum (89.2%) in 3 specimen's ileum opened anteromedially to caecum. The length of

caecum varied from 42mm to 75mm and the breadth of caecum varied from 37mm to 67mm. The average length of caecum is 43.64mm and breadth is 48.71mm. The position of appendix in 20 specimens (71.4%) were retrocolic or retrocaecal and 12 o'clock position. The length of appendix varied from 42 mm to 136 mm the lengthiest. The average length of appendix is 76.7mm the double or duplicate appendix was seen in one specimen.

Table 1: Showing shape of caecum and ileal opening into caecum

Sl no.	Type of caecum	No. of specimens	Percentage	Posteromedial opening	Anteromedial opening
1	Foetal type	4	14.2%	25 no.-89.2%	3no.- 10.7%
2	Adult type	21	75%		
3	Quadrate type	3	10.8%		

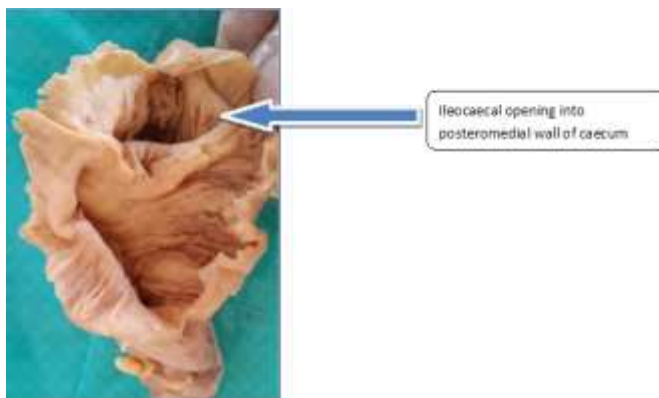


Fig. 1: Showing the opening of ileum posteromedially into caecum (arrow)

Table 2: Showing the parameters of length and breadth of caecum

Specimen	Length in mm	Breadth in mm
1	62	53
2	5	45
3	42	5
4	5	48
5	47	49
6	55	62
7	5	41
8	6	53
9	58	52
10	51	56
11	52	6
12	7	65
13	56	5
14	75	75
15	62	55
16	7	65
17	68	58
18	42	48
19	48	37
20	55	48
21	55	48
22	65	58

23	55	56
24	56	47
25	56	53
26	65	58
27	7	55
28	55	63
Average	43.64mm	48.71mm

The length of caecum varied from 42mm to 75mm and the breadth of caecum varied from 37mm to 67mm. The average length of caecum is 43.64mm and breadth is 48.71mm

Table 3: Showing different positions of appendix (n=28)

Sl. No.	Position of appendix	No. of specimen	Percentage
1	Retrocolic/ retrocaecal 12 o clock	20	71.4%
2	Preileal 20 clock	4	14.2%
3	Promontoric 3 o clock	2	7.1%
4	Midinguinal 6 o clock	1	3.5%
5	Double appendix	1	3.5%
6	Ectopic type	0	0

The position of appendix in 20 specimens (71.4%) were retrocolic or retrocaecal and 12 o clock position as shown in Table 3. In one specimen the appendix showed mid inguinal or 6 o clock position as shown in Fig. 2 the length of appendix varied from 42 mm to 136 mm the lengthiest as shown in Fig. 3. The average length of appendix is 76.7mm the double or duplicate appendix was seen in one specimen as shown in Fig. 4.

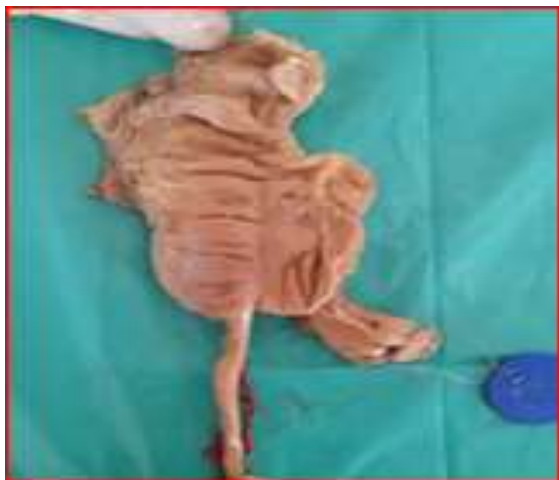

Fig. 2: Showing midinguinal or 6o clock position

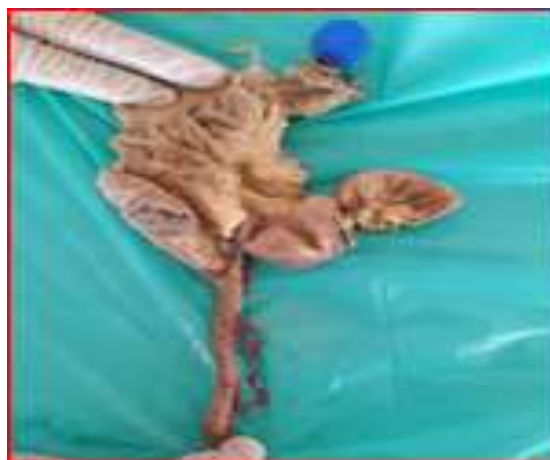

Fig. 3: Showing lengthiest appendix of 136mm

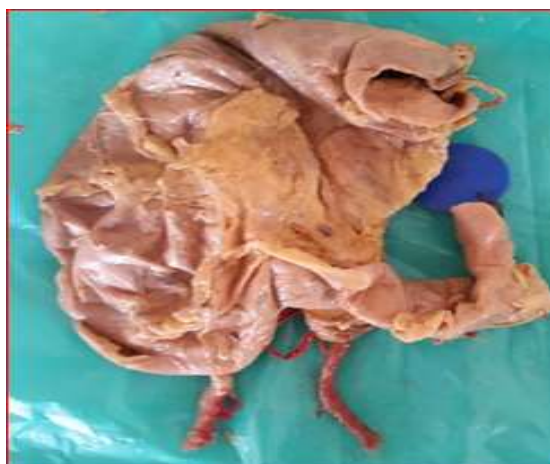

Fig. 4: Showing double or duplicate appendix

Discussion

Acute appendicitis a common intraabdominal surgical pathology requires a comprehensive understanding of its presentation, evaluation, diagnosis and overall operative management. The morbidity and mortality are related to the presenting stage of the disease and are substantially higher in cases of perforation.

In the present study, the adult type of caecum was highest 75%, foetal type 14.2%. The retrocaecal position was highest (71.4%) followed by preileal(14.2%), promontoric (7.5%), midinguinal and double appendix 3.5% each. This is in accordance with previous studies.

Arindom B and others studied 25 adult cadavers over a period of 3 years and found in all specimens the shape of the caecum was adult type and the appendix was found in the retrocaecal position in majority with a complete mesoappendix.⁵

Sunnapu studied in 50 embalmed cadavers and examined for shape of Caecum measurements of Caecum, site of entry of ileum into Caecum, measurements of Appendix & position of Appendix. It showed that in all the cadavers shape of caecum is adult type asymmetrical. Out of 35 male cadavers the length was ranging from 54-65mm & breadth was ranging from 65-75 mm. In 15 female cadavers length was ranging from 50-62mm, breadth was ranging from 65-75mm. In all 50 (100%) adult specimens the ileum has opened posteromedially into the caecum. Most common position of appendix was retrocaecal and least common was pre & post ileal position.⁶

Geethanjali and others studied 52 cadavers and observed the variations in position, length ofv appendix and study revealed that pelvic position was highest 36.52%, retrocaecal 32.69%, post ileal 11.53%, preileal 9.62%, subcaecal 5.77%, rt paracolic 1.9%. The average length of appendix was 6.47cms in males and 5.34cms in females.⁷

A successful outcome of lap appendicectomy require greater skills from the operator. The result of many comparative studies have shown that outcome of lap appendicectomy was influenced by the experience and technique of operator. Minimally access surgery require different skills and technical knowledge of appendix.⁸

Conclusion

The present study determined the commonest shape of the caecum, commonest position of appendix in Mysore based population which aids surgeons during open or lap appendicectomy in cases of appendicitis.

References

1. Standring S. Gray's anatomy. Anatomical basis of clinical practice. 39th ed. Churchill livingstone,2005;1189-1190.
2. Setty SNRS, Katikireddi RS. Morphometric study of human cadaveric caecum and vermiform appendix. Int J Health Sci Res. 2013;3(10):48-55.
3. Reshma M. et al, Morphological features and morphometric parameters of human fetal vermiform appendix at different gestational ages. Int J Anat Res 2013;02:18-25.
4. Uttam Kumar Paul. Position of Vermiform Appendix: A Postmortem Study .Bangladesh J. Anat. 2009;7(1):34-36.
5. Arindom banerjee. Morphological variations in the anatomy of caecum and appendix – A cadaveric study. National journal of clinical anatomy. 2012;Vol-1:30-35.
6. Sunnapu U. Morphometric Study of Adult Ileo Caecal Region. Indian journal of applied research. July 2015;Volume:5(7):442-444.
7. Geethanjali HT. A Study of variations in the position of vermiform appendix. Anatomica Karnataka. 2011;Vol 5(2):17-23.
8. Mishra RK. Textbook of practical laparoscopic surgery. Jaypee publications. 3rd edition. ISBN 978-93-5025-941-2.2013;202.