

## First Sacral Pedicle – A Morphometric Analysis

Nirmala Devi Murugesan<sup>1,\*</sup>, Mathivanan Dharmalingam<sup>2</sup>

<sup>1</sup>Associate Professor, <sup>2</sup>Post Graduate Student, Dept. of Anatomy, PSG IMS & R, Combatore

\*Corresponding Author:

E-mail: nimmi1971@yahoo.com

### Abstract

**Background:** Human osteology varied in various phases of human evolution. The morphology and morphometry of bones varies across different geographical areas in response to the climatic (topographical) and hereditary factors. Knowledge on Osteology plays a vital role in anthropological studies, forensic aspect, diagnostic and interventional aspects in the field of surgery. Human sacrum is a triangular fusion of five vertebrae. It forms the postero superior wall of the pelvic cavity. Sacral pedicle screw fixations are becoming increasingly popular now a days in interventions like posterior transpedicular screw fixation, pediculocorporeal screw placement for the treatment of unstable lumbosacral spine caused due to trauma, degenerative changes, malignancies and congenital anomalies. Lumbosacral spondylosis is best treated by spinal external fixation.

**Methods and Results:** In this study of 30 sacra in adults (15 males & 15 females), the first sacral pedicle morphometry with parameters like H distance, W distance, XP distance, T angle and AM angle were measured using vernier caliper & goniometer. The total H distance, W distance, XP distance, T angle and AM angle were  $20.85 \pm 2.46$  mm,  $21.76 \pm 2.50$  mm,  $46.21 \pm 3.68$  mm,  $43.17 \pm 2.74^\circ$  and  $34.07 \pm 2.15^\circ$  respectively on the right side. The total H distance, W distance, XP distance, T angle and AM angle were  $21.33 \pm 2.73$  mm,  $21.69 \pm 2.61$  mm,  $45.89 \pm 3.58$  mm,  $43.30 \pm 1.69^\circ$  and  $34.17 \pm 1.95^\circ$  respectively on the left side. The results were documented in males and females along with their right and left sides respectively.

**Conclusion:** To update knowledge of human sacrum which proves mandatory for the Forensic, Radiology, orthopaedic fields and to help as a marker for interventions like posterior transpedicular screw fixation, pediculocorporeal screw placement for the treatment of unstable lumbosacral spine caused due to trauma, degenerative changes, malignancies and congenital anomalies, the study has been carried out.

**Keywords:** anthropological, transpedicular, lumbosacral, first sacral pedicle.

Access this article online	
Quick Response Code:	Website: www.innovativepublication.com
	DOI: 10.5958/2394-2126.2016.00009.8

### Introduction

Human sacrum is a triangular fusion of five vertebrae. It forms the postero superior wall of the pelvic cavity. It is placed in between the two hip bones thereby completing the pelvis. It articulates with the fifth lumbar vertebra above (base) and with the coccyx below (apex). It has dorsal, pelvic, lateral surfaces and a sacral canal situated between the base and the apex. The base consists of pedicle which is short and got projected posterolaterally<sup>(1)</sup>. Spinal nerves and vascular bundles are running along the medial and lateral aspects of the pedicle respectively.

Sacral pedicle screw fixations are becoming increasingly popular now a days in interventions like posterior transpedicular screw fixation<sup>(2)</sup>, pediculocorporeal<sup>(3)</sup> screw placement for the treatment of unstable lumbosacral spine caused due to trauma, degenerative changes, malignancies and congenital anomalies. Lumbosacral spondylosis are best treated by spinal external fixation<sup>(4)</sup>. Hence the knowledge on the morphometry of S1 pedicle proves to be mandatory for

safe placement of the pedicle screws during orthopedics interventions and radiological diagnosis.

### Aim & objective

To analyse and report the morphometrical parameters of the first sacral pedicle in the south Indian population which carries significance during orthopedics interventions like sacral screw fixation and during radiological diagnosis.

### Material

30 Human sacrum in the Department of Anatomy (15 males & 15 females).

### Inclusion criteria:

1) Completely ossified bone.

### Exclusion criteria:

- 1) Pathological sacra (bony deformity or disease).
- 2) Unossified bone.

### Methodology

30 Human sacra of specified sex (15 males & 15 females) were observed in the Department of Anatomy after obtaining the due ethical clearance.

Morphometric analysis of the S1 pedicle was made with the help of the vernier caliper and goniometer.

### Parameters

H Distance: Cephalo-caudal height of S1 pedicle. H distance was measured between the most superior

border of the S1 foramen and superior surface of body of first sacral vertebra (Fig1).

W Distance: Width of S1 pedicle was measured between anterior and posterior margins of S1 pedicle (Fig 2).

X Point: A point below and lateral to the inferior tip of the superior articular process of S1(Fig 2).

P Point: Sacral promontory (Fig2).

XP Distance: Pedicle length is the distance from entrance point (X) to sacral promontory (P) (Fig2).

T Angle: Transverse angle of S1 pedicle. T angle represents the angle between vertebral anteroposterior on midline of S1 and XP line on transverse plane (Fig2).

AM Angle: The sacral pedicle anteromedial screw trajectory angle (Fig2).

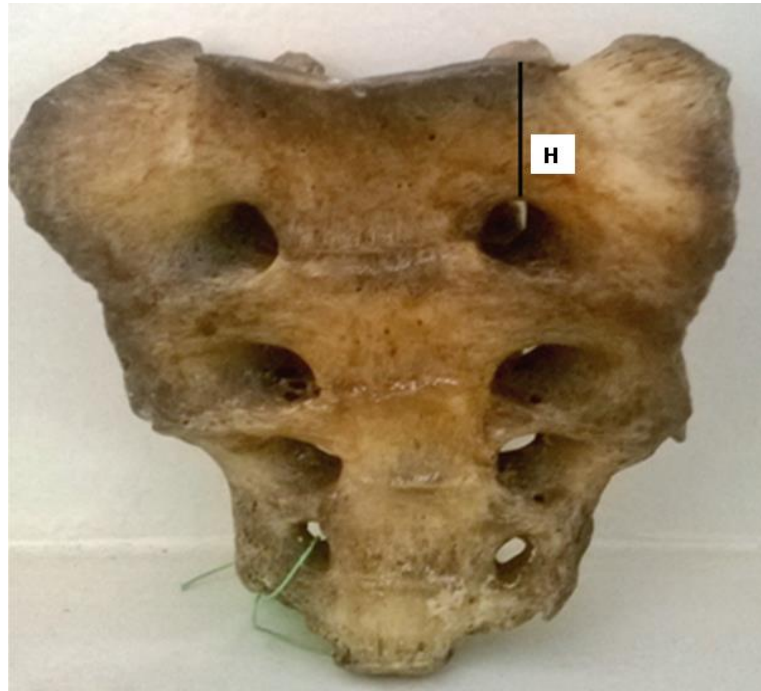


Fig. 1: H Distance – cepalo-caudal height of first sacral vertebra




Fig 2: X point, P point, W distance, XP distance, T angle and AM angle

**Observation:** Tables attached

**Table 1: H, W, XP, T & AM of right & left sides in Males**

Males	H(mm)	W(mm)	XP (mm)	T °	AM°
Right	21.69 ± 2.46	22.30 ± 3.10	46.06 ± 4.01	43 ± 2.90	34.13 ± 2.39
Left	22.50 ± 2.93	22.27 ± 3.16	45.47 ± 4.01	43.33 ± 1.67	34.20 ± 2.31

**Table 2: H, W, XP, T & AM of right & left sides in Females**

Females	H(mm)	W(mm)	XP(mm)	T°	AM °
Right	20.02 ± 2.21	21.22 ± 1.68	46.36 ± 3.46	43.33 ± 2.66	34 ± 1.96
Left	20.15 ± 1.98	21.10 ± 1.84	46.30 ± 3.18	43.27 ± 1.75	34.13 ± 1.60

**Table 3: H, W, XP, T & AM of right & left sides in Total**

Total	H(mm)	W(mm)	XP(mm)	T°	AM°
Right	20.85 ± 2.46	21.76 ± 2.50	46.21 ± 3.68	43.17 ± 2.74	34.07 ± 2.15
Left	21.33 ± 2.73	21.69 ± 2.61	45.89 ± 3.58	43.30 ± 1.69	34.17 ± 1.95

## Discussion

A study in 100 west Antolian population in 2003 it was documented the measurements of H, W, XP & T in females as 13.6±2.30 mm, 22.5±2.60 mm, 50.7±3.7 mm, 43±2.3° and in males as 13.6±2.7 mm, 22.2±2.8 mm, 51.8±3.5 mm, 41±2.2° respectively<sup>(3)</sup>.

In 2008, an observation was made in 50 adults (38 male & 12 female) that the pedicle length in males and females as 43.73mm, 41.7 mm respectively, pedicle width was 15.6 mm and 14.73 mm in males, females respectively and the pedicle height was 21.9mm and 20.15mm in males and females respectively<sup>(6)</sup>.

It was documented in 2009 after a study in 100 adults of 35 to 87 years old (59males and 41 females) in Thailand that the S1 pedicle height on right as 14.88 mm and on left as 14.75 mm, the AM angle was 35.65 ± 4.73°, 31.95 ± 3.95° on right and left respectively<sup>(5)</sup>.

In a study of 50 dry adult sacra (25 males and 25 females) of south Indian population in 2013 it was noted that the cephalo caudal height of S1 pedicle as 19.33±2.72 mm and 19.52±3.14 mm in right and left respectively, S1 pedicle length as 49.9±3.6 mm and 46.3±4.8mm for the males and females respectively, antero posterior width was 12.25 mm and 11.50±2.64 mm in right and left respectively and pedicle depth was 28.31mm and 28.55mm in right and left respectively<sup>(4)</sup>.

In 2014, a study in 22 dry bony pelvis of Taiwanese population it was documented that the cephalo caudal height of S1 pedicle as 27.2±4 mm and 23.9±3.7 mm in males and females respectively, S1 pedicle length as 49.9±3.6 mm and 46.3±4.8mm for the males and females respectively and antero posterior width as 7.5 mm and 7.5±1.7 mm in males and females respectively<sup>(2)</sup>.

In the present study it was observed that: The mean with standard deviation of the male sacrum on the right side for H, W, XP, T and AM were 21.69 ± 2.46 mm, 22.30 ± 3.10 mm, 46.06 ± 4.01 mm, 43 ± 2.90° and 34.13 ± 2.39° respectively.

The mean with standard deviation of the male sacrum on the left side for H, W, XP, T and AM were 22.50 ± 2.93 mm, 22.27 ± 3.16 mm, 45.47 ± 4.01 mm, 43.33 ± 1.67° and 34.20 ± 2.31° respectively.

The mean with standard deviation of the female sacrum on the right side for H, W, XP, T and AM were 20.02 ± 2.21 mm, 21.22 ± 1.68 mm, 46.36 ± 3.46 mm, 43.33 ± 2.66° and 34 ± 1.96° respectively.

The mean with standard deviation of the female sacrum on the left side for H, W, XP, T and AM were 20.15 ± 1.98 mm, 21.10 ± 1.84 mm, 46.30 ± 3.18 mm, 43.27 ± 1.75° and 34.13 ± 1.60° respectively.

Independent sample test (t test for equality of means) was used for significance analysis, which showed significance between the male and female pedicle (S1) height of the human sacrum on the left side, rest of all the parameters compared were insignificant.

## Conclusion

Thus the morphometrical parameters of the first sacral pedicle are reported with the view of designing the appropriate size of the sacral pedicle screw in our population. We are recommending a future scope for this study by adding a radiological correlation and also to assess the morphometry with increased sample size.

**Conflict of Interest: None**

**Source of Support: Nil**

**References:**

1. Susan standring. The back. 40<sup>TH</sup> ed. china, elsevier, 2008:724-727.
2. Pai MM, Murlimanju BV. Morphometry of the pedicle of first sacral vertebra. *Rev Arg de Anat Clin.*2014; 6(3)156-61.
3. Okutan O, Kaptanoglu E, Solaroglu I. Pedicle morphology of the first sacral vertebra. *Neuroanatomy.* 2003;2.
4. Manisha S, Mrithunjay R, Soumitra T. Morphometry of first pedicle of sacrum and its clinical relevance. *IJHBR.*2013 july;4(1).
5. Arman C, Naderi S, Kiray A, Aksu FT. The human sacrum and safe approach for screw placement. *Journal of clinical Neuroscience.* 2009 ;16(1).
6. Xu R, Ebraheim NA. Surgical anatomy of the sacrum. *Am J Orthop.*2008;37(10)177-181.