

Management of Persistent Hypotension after Resection of Parasagittal Meningioma

Salih Gulsen*

Baskent University Medical Faculty Hospital - Neurosurgery, Maresal Fevzi Cakmak cad.10, sok. No: 45, Ankara 06540, Turkey

Abstract

Citation: Gulsen S. Management of Persistent Hypotension after Resection of Parasagittal Meningioma. *OA Maced J Med Sci*. 2014 Sep 15; 2(3):483-487. <http://dx.doi.org/10.3889/oamjms.2014.086>

Key words: Bifrontal craniotomy; frontal sinus; sagittal sinus; meningioma; hypotension.

***Correspondence:** Salih Gulsen, MD, Department of Neurosurgery, Faculty of Medicine, Baskent University Medical Faculty Department of Neurosurgery, Fevzi Cakmak Caddesi 10. Sokak no: 45, Cankaya, Bahcelievler, Ankara 06490, Turkey. Business Phone: 0090 312 212 68 68 /1362. FAX: 0090 3122237333. E.mail: salihgulsen07@gmail.com

Received: 10-Feb-2014; **Revised:** 19-Mar-2014; **Accepted:** 30-Mar-2014; **Online first:** 11-May-2014

Copyright: © 2014 Gulsen. This is an open access article distributed under the terms of the Creative Commons Attribution License, which permits unrestricted use, distribution, and reproduction in any medium, provided the original author and source are credited.

Competing Interests: The authors have declared that no competing interests exist.

Various complications including air embolism have been discussed in large clinical series regarding the parasagittal meningioma. We presented and discussed the patient suffering from persistent hypotension after excision of parasagittal meningioma.

A 47-year-old man was admitted to our hospital with complaints of headache and frontal region swelling. His cranial MRI showed a bilaterally located parasagittal meningioma at the anterior one third of the sagittal sinus. Conspicuously, he had large frontal sinus and its length was about totally 7 cm in sagittal and transverse part.

During craniotomy, we had to open frontal sinus because of its large size and open the sagittal sinus while removing of the tumor. So coincidental opening of the superior sagittal sinus and/or emissary veins located within diploe of the cranium and frontal sinus may cause hypotension after extubation due to normal respiration led to air escaping from the frontal sinus to the emissary veins placed next to the frontal sinus. Bilateral application of the tamponade embedded with vaseline inside to the nose prevents air escaping from the frontal sinus to the emissary veins.

Introduction

Venous air embolism can happen in any surgical position [1]. The cause may be an open vein and a gradient between the operation site and the heart [1]. Venous air embolism may occur in any operation including cesarean section, pelvic, laparoscopic and orthopaedic surgery, as well as neurosurgery [1]. Emissary veins, located within diploe of the cranium, may cause air embolism during craniotomy. And these are one of the most frequent site for venous embolism [1-3].

Meningiomas may result in hyperostosis of adjacent bone and frequently show calcification and the classic histological feature of psammoma bodies [2-5]. Parasagittal meningiomas make up of 20% of all meningiomas [2-5]. Surgical resection of a parasagittal meningioma needs comprehensive

preoperative evaluation to prevent possible complications in the perioperative period.

We presented this case to provide a way to manage relevant problems including venous air embolism, perioperative hypotension, bone involvement with meningioma and bilateral involvement of the sagittal sinus.

Case Report

History and Presentation. A 47-year-old man presented with a history of swelling in the anterior part of the frontal bone and nonspecific headache for one year. The neurological examination revealed no pathology.

Magnetic resonance angiography without

contrast enhancement of the head revealed that complete occlusion in the anterior third of the superior sagittal sinus and partial occlusion central third of the superior sagittal sinus. Arrowheads show complete occlusion and arrows show partial occlusion in the figure 3a and 3b. In addition, bilateral cortical veins were present just posterior to the partially occluded sinus. Magnetic resonance imaging of the brain with gadolinium revealed a homogenous and hyperintense extraaxial mass located bilaterally at the frontal region and invading the sagittal sinus on T1-weighted sequences. A meningioma was originally suspected (Fig. 1, 2).

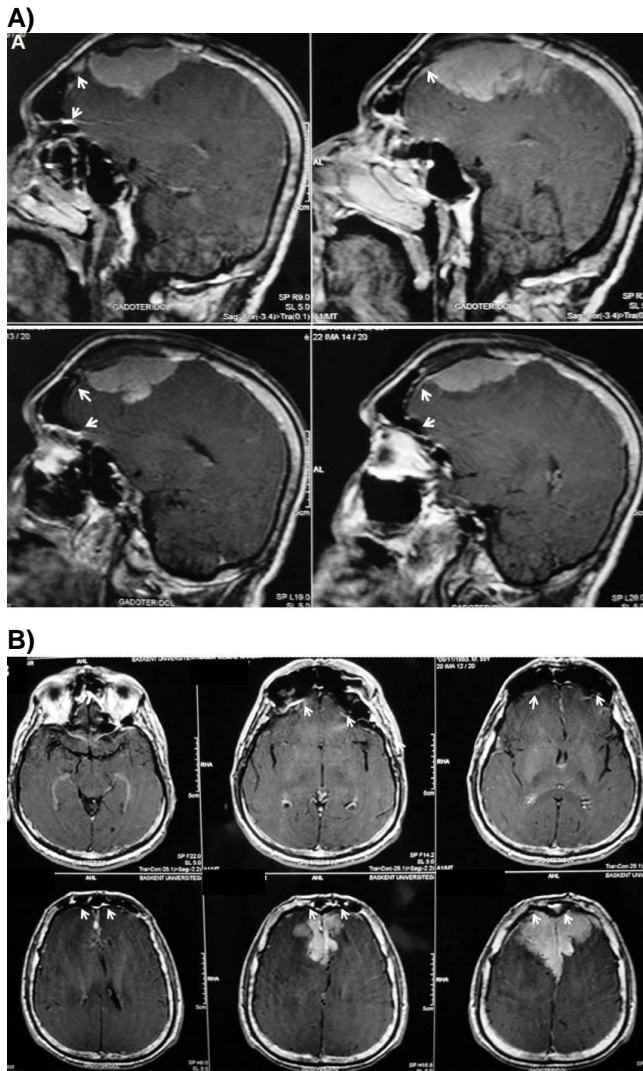


Figure 1: A) and B) preoperative sagittal and axial T1-weighted MRI scan (contrast- enhanced) showing a parasagittally located lesion with homogenous contrast enhancement. Arrows are showing the large frontal sinus.

Operation. Bifrontoparietal craniotomy was performed following a bicoronal skin incision behind the coronal suture. The frontal sinus was opened along with the frontal bone due to a large frontal sinus. The frontal bone, duramater and sagittal sinus were totally involved by the tumour, none of them separable from each other because of the tumoral invasion. For

this reason, we had to extract the duramater, the anterior third of superior sagittal sinus and bone. While we were performing and extracting the frontoparietal bone involved and destructed by the tumour, the tumor was also pulled out due to tumoral invasion of the tumor to the bone.

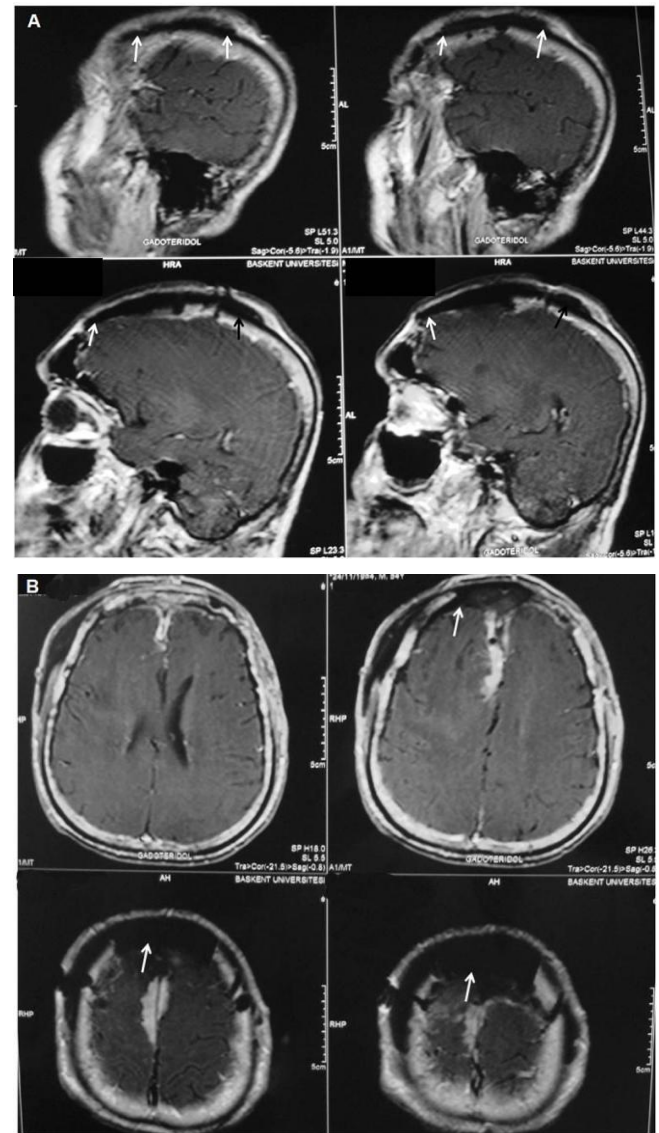


Figure 2: A) and B) postoperative sagittal and axial T1-weighted MRI scan (contrast-enhanced) showing parasagittal residual lesion with homogenous contrast enhancement. Arrows are showing subgaleal fluid collection (A) and the large frontal sinus (B).

After extracting the bone, duramater and the tumor, we had confronted profuse venous bleeding from the partially occluded part of the sagittal sinus and we ligated this sinus at the anterior part of the central third of the superior sagittal sinus to stop the bleeding. Meanwhile, the patient immediately developed hypotension with an end-tidal PCO₂ of 15 mmHg so massive air was aspirated from the central venous catheter placed right atrium via right subclavian vein. Later hypotension was resolved in minutes after ligating at the anterior part of the central third of the superior sagittal sinus and putting a

muscle graft and soaked cotton piece on the the superior sagittal sinus as well as we plastered bone-wax at the edges of craniotomy to prevent air leakage from the operation side to the breached diploic veins and we took the muscle graft and soaked cotton piece on the the superior sagittal sinus and we did not observed bleeding from the venous system.

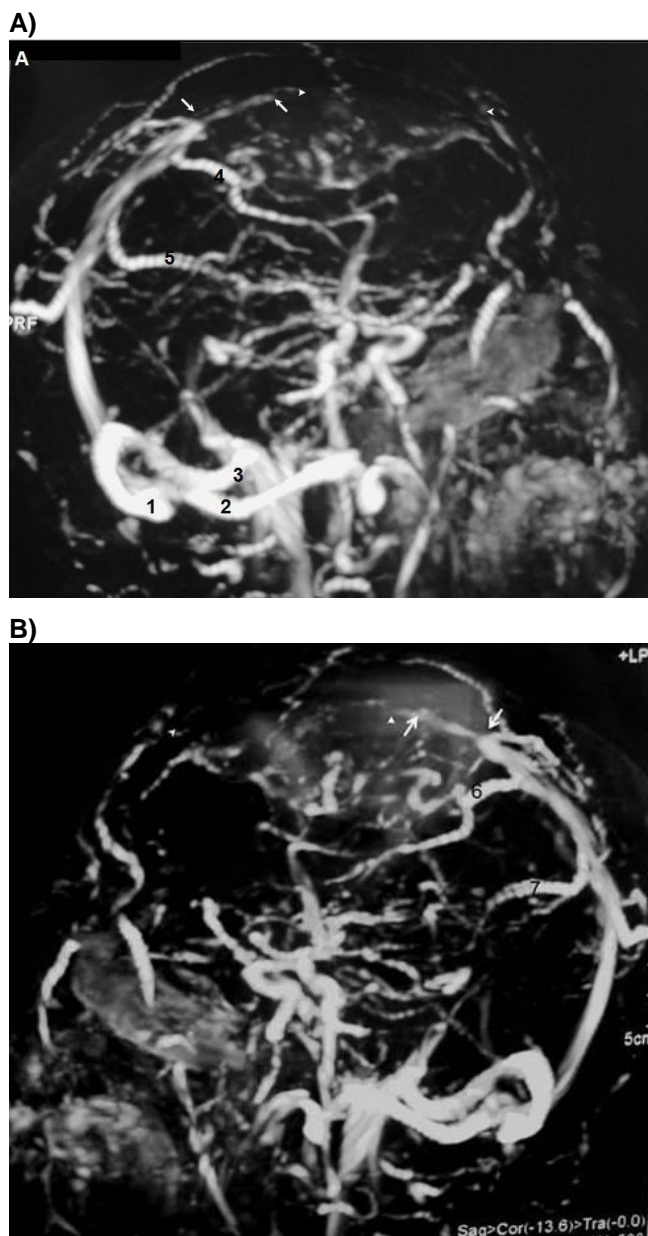


Figure 3: A) and B) preoperative MRI angiography showing the partially and totally occluded part of the superior sagittal sinus on the left and right side, respectively. Arrows show the partially occluded part of the superior sagittal sinus and arrowheads show the totally occluded part of the superior sagittal sinus. 1. Confluence of sinuses (torcular herophili) 2. Left transverse sinus 3. Right transverse sinus 4, 5, 6, 7. Major cortical drainage veins.

After stabilization of the patient, we continued to remove the residual tumor, but we did not to remove it completely because of two reasons. Firstly, the posterior part of tumor was very close to the motor cortex on both sides, secondly, also this region's

drainage veins very close to the tumor. Because of this reasons, complete extraction of the tumor would cause devastating complications, including damaging to drainage veins, superior sagittal sinus and motor cortex on both sides. So tumoral resection was performed as grade III according to the Simpson grading system [6]. Involved duramater and frontal bone were removed and a dural substitute was placed on the defective area without suturing at the edges of uninvolved duramater. Then we dissected the galea aponeurotica from the inner face of the scalp which we opened it to perform craniotomy. After dissecting the galea aponeurotica without cutting it from its base, we created a pedicle flap and we extended it to cover opened frontal sinus area and we stitched it on the duramater next to the base of the frontal bone as possible as in water-proof style to prevent any air and cerebrospinal fluid leakage through opened frontal sinus. Following these steps, we performed cranioplasty with polymethyl methacrylate (PMMA) on the involved part of the frontal bone.

Postoperative course. We transferred the patient to the intensive care unit in an intubated condition and extubated there. He had no neurological deficit, but developed hypotension after extubation in the early postoperative period. So we started to administer dopamine infusion at 10- 15 μ gr/kg/minute for 24 hours. We positioned the patient in the left lateral recumbent position (patient's right side up) to prevent air embolism. Transthoracic echocardiogram showed normal ejection fraction and systolic function with no air bubble within the heart. Blood gas analysis showed no abnormality. The hemoglobin level and the central venous pressure were within the normal range. After excluding cardiac reasons, we applied tamponade embedded with vaseline inside to the nose and changing it every two hours for 36 hours to prevent air passage. After stabilization of the patient, postoperative magnetic resonance imaging of the brain showed no air (Figure 2a, 2b).

Discussion

Series of superior sagittal sinus meningiomas emphasize some complications in the peroperative period [3, 4, 7]. These complications include postoperative hematoma, venous air embolism, subgaleal fluid collection, new onset of seizures, deep venous thrombosis, brain edema and transient or permanent neurological worsening in the immediate postoperative period [2, 3, 4, 8, 9]. Operative mortality varies between 1.8% and 7.3%, but has been reduced with new imaging systems and improved microsurgical technique [2, 3, 4, 9]. Different authors have classified parasagittal meningioma regarding superior sagittal sinus invasion by the tumour [2, 10]. Parasagittal meningiomas are graded from I to VIII. Grade VIII represents bilateral complete invasion of

the sagittal sinus. As these grade increases, the surgical resection and dissection from the sagittal sinus may be more difficult and there is an increased complication risk depending on whether collateral venous drainage has developed or not [2, 4, 9]. Moreover, Merrem Krause and Bonnal Brotchi also classified meningiomas regarding their invasion to the dural venous sinus in six different grades [11]. On the contrary to Merrem and Bonnal, Sindou offers both grading and surgical treatment method for each grade his grading system [10]. For example, Type V-VI: removal of involved portion of sinus and restoration by venous bypass [10]. But we preferred to ligate instead of making bypass because totally occluded part located anterior one third of superior sagittal sinus and sacrificing of this part would not cause any complication such as edema or hemorrhagic infarct [2, 3, 4, 9, 12]. However, while sacrificing the totally occluded part of the superior sagittal sinus does not create any major clinical problem, sacrificing or inadvertent injury to the veins around the occluded part of the superior sagittal sinus can cause significant morbidity and even mortality [2, 3, 4, 9, 12]. A meningioma located at the anterior third of the sagittal sinus can be removed without significant morbidity risk. The middle and posterior third of the sagittal sinus is the problematic location for meningioma that invades the sagittal sinus, because the major cortical drainage veins and the vein of Trolard are located around these parts [2, 3, 4, 9].

Maximal resection of meningiomas gives lower recurrence risk, but increases the morbidity risk for a meningioma located at the middle and posterior third of the sagittal sinus [2, 4, 7]. Our aim in this case report was to present the consequences of coincidental opening of a large frontal sinus and superior sagittal sinus or emissary veins located diploe of the cranium during bifrontoparietal craniotomy to remove a parasagittal meningioma. It is known that sagittal sinus occlusion may be tolerable if it develops over time in contrast to an acute occlusion. The mechanism underlying this tolerance is the emergence and development of collateral veins around the occluded part of the sagittal sinus [2, 3, 4, 9]. Some authors advocate partial resection of parasagittal meningiomas located in the middle and posterior part of the sagittal sinus and gamma knife radiosurgery after partial resection of the meningioma or waiting for development of collateral venous structures before the second operation [2, 3, 4, 9, 13]. The preconditions for the occurrence of venous air embolism are a breach of the venous system and a pressure gradient for air entry. For example, the sitting position increases the risk of venous air embolism because of decreased venous pressure at the surgical site due to gravitational effect [1]. We speculated that opening the frontal sinus causes a change of aeration within the frontal sinuses, but does not create any clinical problem when it is repaired; however, coincidental opening of the frontal sinus and an emissary vein located diploe and superior sagittal

sinus may cause hypotension. Each cycle of respiration causes a pressure gradient and may lead to air bubbling into the opened part of these venous structures. Our hypothesis is supported by the comparison of the patient's blood pressure while intubated intraoperatively and postoperatively and extubated in the intensive care unit. The patient developed hypotension while being operating on under general anesthesia and a massive amount of air was aspirated from the centrally placed venous catheter. Putting a soaked cotton ball and muscle tissue on the middle third of the sagittal sinus and placing mild pressure on the cotton caused normalization of the blood pressure and end-tidal CO₂. After closure of the craniotomy, the patient was transferred into the intensive care unit while he was intubated. When extubated, the patient developed immediate hypotension and required dopamine to sustain his blood pressure within normal limits. The various factors that cause hypotension including hypovolemia and cardiac dysfunction were excluded, but the cause of the hypotension was not diagnosed.

If we compare the normal physiologic respiration and the ventilation in the intubated patient, air bypasses the frontal bone sinuses and directly ventilates the lungs through the intubation tube in intubated patients in contrast to the normal respiration pattern. Air ventilates the frontal sinus through the middle meatus in the ipsilateral nasal cavity by a frontonasal canal during normal respiration [12]. The patient had a normal respiration pattern when extubated and each inspiration created a pressure gradient between the breach veins and the heart as it created pressure lower than normal inside of the cranium due to the opened large frontal sinus (Figure 1a, b; Figure 2a, b). Each respiratory cycle creates pressure differences and causes opening and closing of the injured part vein or sinus and air escaping into the injured part of the vein or sinus during inspiration and expiration. After establishing this mechanism, we decided to place tamponade embedded with vaseline inside to the nose to prevent air passage every two hours for 36 hours due to vaseline melting in normal human body temperature, and stopped it as the patient's blood pressure was within normal limits. Following the application of the tamponade, the patient's hypotension resolved and dopamine infusion was stopped in one hour. We continued this application about 36 hours. Because while we were changing the nasal tamponade in each two hours, we controlled his blood pressure through arterial line in continuous manner and when we observed that there was no change (Hypotension) his blood pressure during changing of the tamponade, we decided to stop at 36th hours to apply this nasal tamponade. In addition, we think that this blood pressure stabilization was provided thanks to epithelization of the breached veins, including diploic veins or cortical veins, but not superior sagittal sinus because we ligated it perfectly and controlled its bleeding during surgery. So the 36-hour period was necessary for closure through

epithelization of the injured part of the venous structures. Notably, I did not find any information about epithelization of the breached veins of the cranium or cerebrum in the literature. Finally, I propose that the development of hypotension after extubation in any parasagittal meningioma case should raise suspicion of coincidental opening of the large frontal sinus and venous structures around the operation site. All cardiac factors leading to hypotension, including systolic dysfunction, hypovolemia, and low level of hemoglobin should be ruled out when treating hypotension. Nasal air passage should be temporarily blocked to prevent a pressure difference inside the cranium during respiration.

In conclusion, coincidental opening of the superior sagittal sinus or /and any emissary veins and frontal sinus may cause hypotension after extubation because of the breach of the venous system and presence of a pressure gradient during each cycle of respiration in cases with an opened frontal sinus. If any similar clinical condition is present, bilateral application of nasal tamponade embedded with vaseline inside to the nose prevents air passage to the frontal sinus, and it would stop air leakage into venous structures especially upon diploic veins.

References

1. Palmon SC, Moore LE, Lundberg J, Toung T. Venous air embolism: a review. *J Clin Anesth.* 1997; 9(3): 9:251-7.
2. Bonnal J, Brotchi J. Surgery of the superior sagittal sinus in parasagittal meningiomas. *J Neurosurg.* 1978; 48(6):935-45.
3. Colli BO, Carlotti CG Jr, Assirati JA Jr, Dos Santos MB, Neder L, Dos Santos AC. Parasagittal meningiomas: follow-up review. 2006;66 (Suppl 3):20-8.
4. DiMeco F, Li KW, Casali C, Ciceri E, Giombini S, Filippini G, Broggi G, Solero CL. Meningiomas invading the superior sagittal sinus: surgical experience in 108 cases. *Neurosurgery.* 2004; 55(6):1263-74.
5. Ohigashi Y, Tanabe A. A huge frontal meningioma associated with intraoperative massive bleeding and severe brain swelling-case report. *J Clin Neurosci.* 2001;(1):54-8.
6. Simpson D. The recurrence of intracranial meningiomas after surgical treatment. *J Neurol Neurosurg Psychiatry.* 1957; (20):22-39.
7. Ayerbe J, Lobato RD, De La Cruz J, Alday R, Rivas JJ, Gómez PA, Cabrera A. Risk factors predicting recurrence in patients operated on for intracranial meningioma. A multivariate analysis. *Acta Neurochir (Wien).* 1999;(141):921-32.
8. Jääskeläinen J, Haltia M, Servo A. Atypical and anaplastic meningiomas: radiology, surgery, radiotherapy, and outcome. *Surg Neurol.* 1986;(25):233-42.
9. Oka K, Go Y, Kimura H, Tomonaga M. Obstruction of the superior sagittal sinus caused by parasagittal meningiomas: the role of collateral venous pathways. *J Neurosurg.* 1994; (81):520-24.
10. Sindou M, Hallacq P. Venous reconstruction in surgery of meningiomas invading the sagittal and transverse sinuses. *Skull Base Surg.* 1998;8(2):57-64.
11. Merrem G. Die parasagittalen meningeome. Fedor KRAUSE Gedachtnivorlesung. *Acta Neurochir.* 1970;(23):203-216.
12. Peter L. Williams: *Gray's Anatomy*, Ed. 38 New York: ELBS with Churchill Livingstone, 1995: 1882-1883.
13. Hattori K, Miyachi S, Kobayashi N, Kojima T, Hattori K, Negoro M, Yoshida J, Nagasaka T. Contralateral meningeal artery supply of paramedian meningiomas. *Surg Neurol.* 2005;(64) :242-48.