

# Compression of the Seventh Cervical Vertebra Following C6-7 and C7-T1 Discectomy, PEEK Cage Implantation in these Intervertebral Spaces, and Management of this Complication in a Patient with Multiple Myeloma

Salih Gulsen\*

*Baskent University Medical Faculty Hospital - Neurosurgery, Maresal Fevzi Cakmak cad.10. sok. No: 45, Ankara 06540, Turkey*

## Abstract

**Citation:** Gulsen S. Compression of the Seventh Cervical Vertebra Following C6-7 and C7-T1 Discectomy, PEEK Cage Implantation in these Intervertebral Spaces, and Management of this Complication in a Patient with Multiple Myeloma. *OA Maced J Med Sci*. 2014 Sep 15; 2(3):467-471. <http://dx.doi.org/10.3889/oamjms.2014.082>

**Key words:** Multiple Myeloma; osteoporosis; Peek Cage; Complication; Vertebra fracture.

\***Correspondence:** Salih Gulsen, MD, Department of Neurosurgery, Faculty of Medicine, Baskent University Medical Faculty Department of Neurosurgery, Fevzi Cakmak Caddesi 10. Sokak no: 45, Cankaya, Bahcelievler, Ankara 06490. Turkey. Business Phone: 0090 312 212 68 68 /1362. FAX: 0090 3122237333. E.mail: salihgulsen07@gmail.com

**Received:** 10-Feb-2014; **Revised:** 18-Mar-2014; **Accepted:** 30-Mar-2014; **Online first:** 09-May-2014

**Copyright:** © 2014 Gulsen. This is an open access article distributed under the terms of the Creative Commons Attribution License, which permits unrestricted use, distribution, and reproduction in any medium, provided the original author and source are credited.

**Competing Interests:** The authors have declared that no competing interests exist.

Patients with multiple myeloma suffer from bone pain, and spontaneous spinal and appendicular bone fractures due to osteoporosis. Osteoporosis occurs as a result of the following 2 factors: 1. Plasma cells secrete macrophage inflammatory protein-1 alpha, which induces osteoclastic activity; 2. Use of corticosteroids. The incidence of osteoporotic fractures and other complications of multiple myeloma are well described in the literature, but the management of cervical disc herniation and its associated complications has not been reported to date.

Herein we present a case that we think exemplifies the management of cervical disc herniation and its complications. Consecutive multilevel cervical discectomy and placement of PEEK cages between the intervertebral cervical disc spaces may cause compression fracture of the vertebrae located between the PEEK cages in osteoporotic patients under continuous corticosteroid treatment—whether or not they have MM; therefore, we recommend use of an anterior plate to prevent this complication.

## Introduction

Multiple myeloma (MM) is a malignancy of plasma cells that produce monoclonal immunoglobulin, and invade and destroy adjacent bone tissue. Bone pain, kidney failure, hypercalcemia, anemia, and recurrent infection are common manifestations of MM [1-3]. The incidence of MM is 3-4/100,000 [4], the male/female ratio is 3:2, and most patients are aged >40 years [5, 6]. Diffuse osteoporosis or discrete osteolytic lesions develop, usually in the pelvis, spine, ribs, and skull. Patients with MM have persistent and unexplained bone pain, especially at night or at rest; 70% of MM patients have bone pain due to lytic bone lesions [2, 6]. These

lesions initially affect the medullary cavity of bones, progressively destroy the osseous cortex, and eventually lead to pathologic fractures. A punch-out lytic appearance of the bone lesion is characteristic, which occurs less frequently than diffuse osteopenia. MM cells produce macrophage inflammatory protein-1 alpha (MIP-1 $\alpha$ ), a member of the CC chemokine family that is responsible for cell adhesion and migration, and directly stimulates osteoclast formation and differentiation in patients with MM [2, 6, 7].

Spontaneous osteoporotic vertebral fractures are commonly seen in MM patients [7]; however, to date, the incidence of cervical disc herniation and complications associated with its surgical treatment have not been reported based on a search of

PubMed. An anterior cervical approach for anterior cervical discectomy would be more complicated due to osteoporosis, even in patients with a stable stage of MM [2, 3, 7]. Many researchers have reported the effectiveness of the (polyetheretherketone) PEEK cage—with or without plate augmentation—in patients undergoing anterior cervical discectomy for restoration and maintenance of disc space height [8, 9, 10]. Additionally, use of a PEEK cage prevents neuroforaminal compression until complete osseous fusion has occurred, as bone grafts may be resorbed and subside, or completely collapse, leading to neuroforaminal narrowing and possibly nerve root compression [11, 12]. Nonetheless, use of a PEEK cage may lead to pseudoarthrosis, kyphosis, and subsidence of the PEEK cage into the corpus of the vertebra [13, 14]. Use of an anterior plate could prevent complications following discectomy and placement of a PEEK cage [15, 16].

To the best of our knowledge the literature does not contain any earlier reports about compression fracture of the cervical vertebra following cervical discectomy and placement of a PEEK cage in patients with or without MM.

### Case Report

A 68-year-old female had been treated for MM for 2 years and received chemotherapy and palliative therapy. She was referred by her hematologist to our neurosurgery department due to left arm pain. She had a 10-d history of progressive disabling right shoulder, right arm, and right forearm pain that was so severe that at the time of presentation she had not slept nor performed her usual daily activities for 8 d. Upon examination she was pale and overweight.

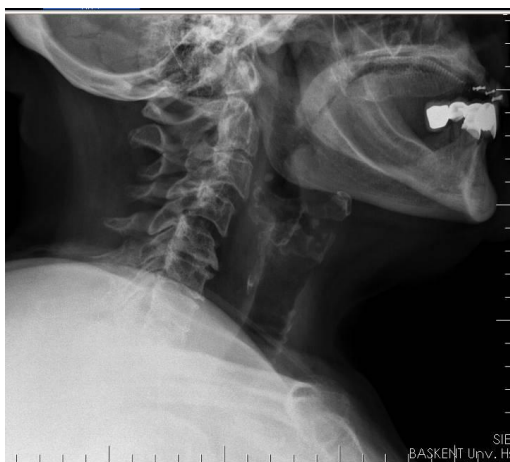

Figure 1: Preoperative lateral cervical X-ray shows that there wasn't a compression fracture in any level or lytic lesion, but does show spondylopathic features.

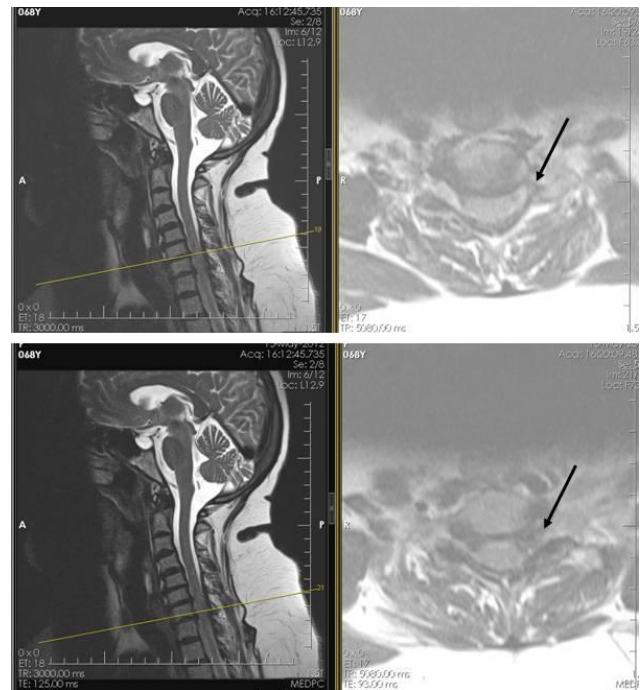


Figure 2: T2-weighted sagittal and axial cervical MRI sections show cervical disc herniation on the left side. The upper image shows C6-7 and the lower image shows C7-T1.

Her left triceps and left intrinsic hand muscle power was 4/5, and triceps reflex was unresponsive. Her pain radiated from the left shoulder region to the left arm, left forearm, and left hand. The remainder of her systemic examination was normal. She had normal blood chemistry and a normal complete blood count, except for the following: hemoglobin: 11 g/dl (normal range: 12-16 g/dl); hematocrit: 33.2% (normal range: 35%-46%). Her erythrocyte sedimentation rate was 55 mm h (normal range: 0-25 mm/h).

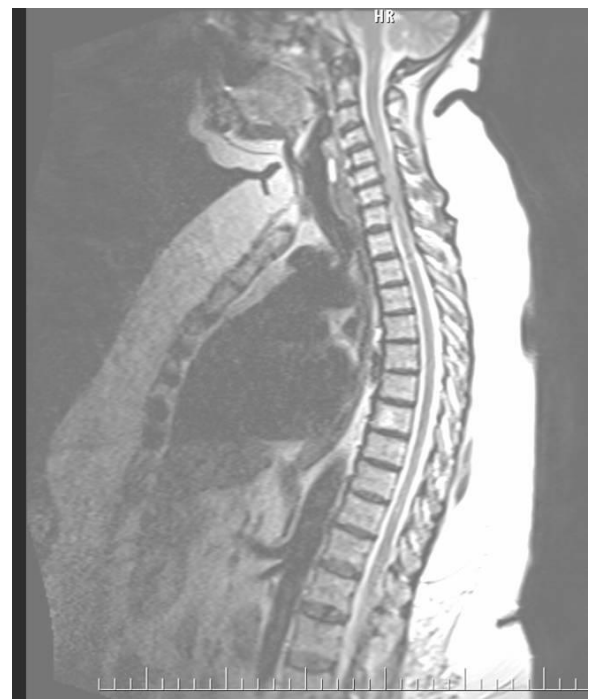

Figure 3: T2-weighted sagittal thoracolumbar MRI section shows that there wasn't an osteolytic lesion.

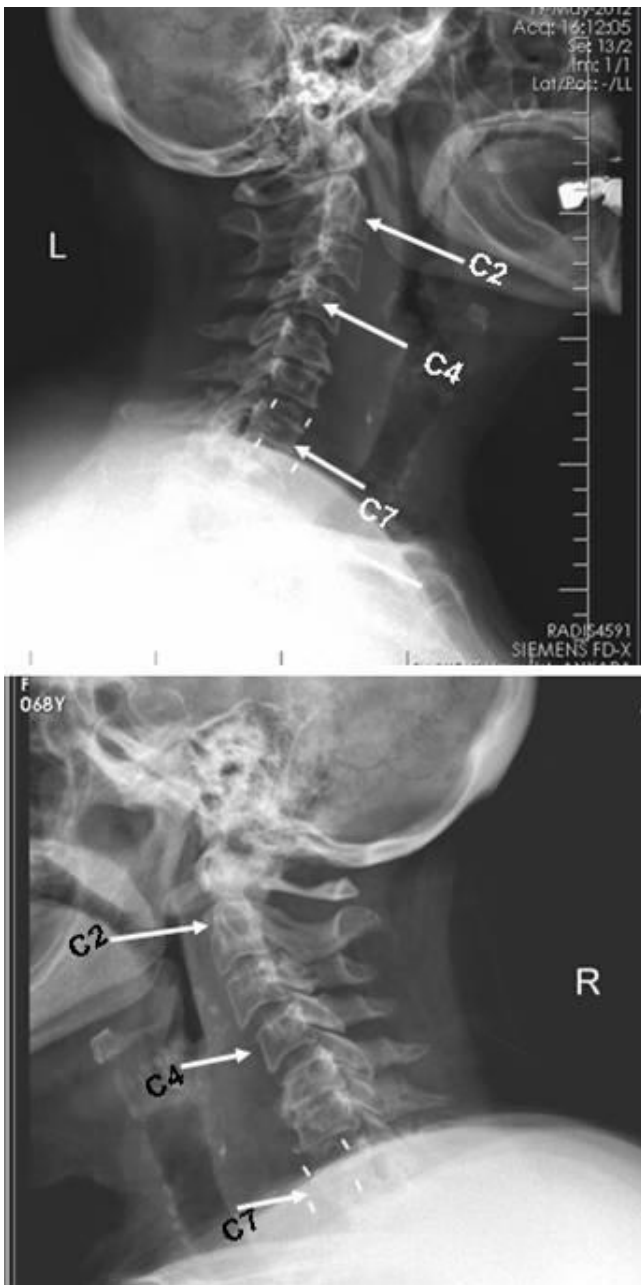


Figure 4: Lateral cervical X-ray shows the PEEK cage's titanium pins. The upper image shows no compression fracture 2 d post surgery; the lower image shows a compression fracture at the C7 vertebral level 3 d post surgery.

Imaging studies, including cervicothoracic vertebral MRI, left shoulder MRI, left shoulder X-ray, and left scapula X-ray did not show osteolytic lesions, but she had an osteophytic spur and herniated disc on the left side at the level of C6-7 and C7-T1, according to cervicothoracic MRI. EMG studies regarding cervical radiculopathy were normal, but her pain persisted and was unresponsive to narcotic analgesic.

Thus, we suggested surgical treatment. We consulted the hematologist that was responsible for her treatment, who agreed with our decision to perform anterior cervical discectomy, as the patient was in a stable period (inactive myeloma).

We performed anterior cervical discectomy at the C6-7 and C7-T1 vertebral levels, and placed a PEEK cage with crumbling homologue bone for fusion on these levels. The patient reported experiencing no pain in her left upper extremity and her muscle power increased the first 2 d post surgery; she was discharged on postoperative d 3. Follow-up cervical vertebral X-ray showed that the PEEK cages placed in the intervertebral spaces remained in the proper location on 2<sup>nd</sup> postoperative days. She presented to our service again with severe left shoulder, left arm, and left forearm pain 3 d after discharge.

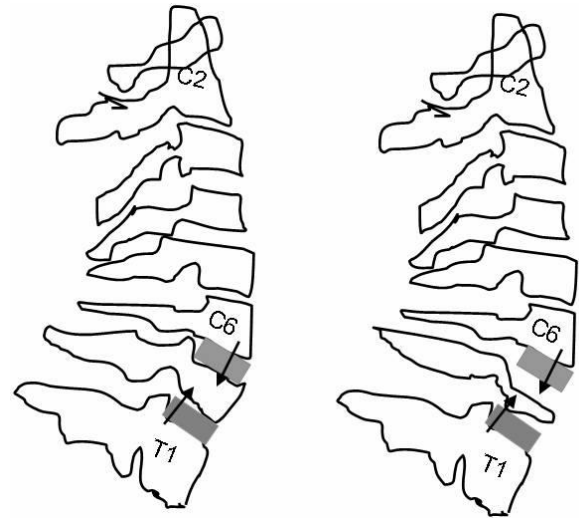


Figure 5: Schematic representation of the lateral X-ray. The left image represents no compression fracture 2 d post surgery; the right image represents the compression fracture at the C7 vertebral level 3 d post surgery. Arrows show vertical loading on the corpus of the C7 vertebra. Grey boxes represent PEEK cages.

Cervical vertebral X-ray showed the almost total collapse of the seventh vertebral body. We promptly performed another surgical procedure. We extirpated the PEEK cages and performed corpectomy of the seventh vertebral body. Then, we placed a retractable titanium cage with crumbling homologue bone for fusion between the C6 and T1 vertebrae. Following placement of the retractable titanium cage, we implanted an anterior plate on the C6 and T1 vertebrae. Following the second surgery the patient did not have any pain and she was discharged 4 days later of the second operation. At the 9 month post-surgery follow-up the patient was in good condition and pain free.

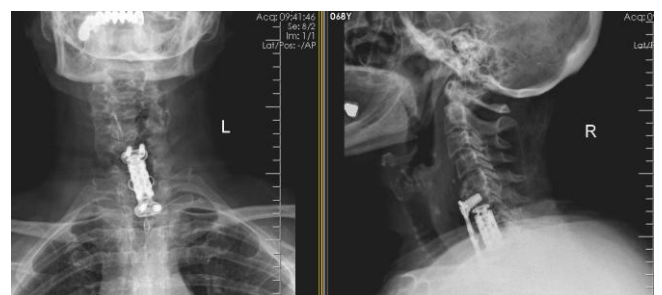


Figure 6: Anterior and lateral cervical X-rays show the anterior plate and retractable titanium cage following the second operation.

## Discussion

Osteoporosis is one of the most important consequences of MM, which occurs because of multiple factors, including immobilization due to bone pain, corticosteroid treatment for hypercalcemia, and bone invasion by plasma cells [2, 3, 7]. Pathologic fractures are common, and vertebral collapse may cause spinal cord compression and hemiplegia or quadriplegia [8]. Primary treatment of active MM is high-dose chemotherapy and autologous progenitor stem cell transplantation [3, 7]. Secondary treatment is supportive treatment and includes kyphoplasty or vertebroplasty for vertebral compression fracture. In addition, radiation treatment for non-vertebral bone lesions or vertebral fractures for which kyphoplasty and vertebroplasty are contraindicated. Also, bisphosphonate treatment for diminishing the risk of skeletal complications; intravenous fluids, steroids, and biphosphonates for hypercalcemia; calcitonin injections and gallium nitrate for refractory hypercalcemia cases; erythropoietin for anemia; antiviral and antibiotics for infections are part of secondary treatment. Lastly, intravenous immunoglobulin for recurrent severe infection [2, 3, 7] are needed.

The case described herein presented to our clinic with severe and disabling pain, and loss of muscle power due to C6-7 and C7-T1 level disc herniation, and osteophytic spur impingement on the left C7 and C8 roots. As the patient did not respond to narcotic analgesic, we performed surgical treatment—discectomy to these levels and scraping the osteophytic spurs on each level with a bone curette rather than extruding the disc fragments, because the intervertebral disc in each intervertebral space was calcified and unified with the osseous structure, and placing PEEK cages at each level. The patient experienced no pain in her left upper extremity during the first 2 d post surgery, but she had severe pain again in her left upper extremity 3 d after discharge from hospital (6 d post surgery). Cervical X-ray at that time showed complete compression of the seventh cervical vertebra. We removed the PEEK cages and performed corpectomy on the level of the C7 vertebra. Then, we placed titanium retractable cages with an anterior plate for fixation.

A PEEK cage is made of polyetheretherketone, a semi-crystalline polyaromatic linear polymer with biomechanical properties very similar to those of bone [8, 9]. It provides a good combination of rigidity, strength, and toughness; it is corrosion-resistant and resistant to the environment, and it is biocompatible and non-absorbable [8, 9]. In addition, the PEEK cage is radiolucent and does not cause radiographic artifacts. PEEK cage-assisted anterior cervical discectomy and fusion is very effective for the treatment of degenerative cervical disc disease, because it prevents graft collapse and provides indirect foraminal decompression via

restoration and preservation of intervertebral height and lordosis [8-11].

We think that the presented patient's clinical situation, together with use of PEEK cages, caused compression fracture, because the biomechanical properties of the PEEK cage are similar to those of normal bone, but not those of severe osteoporotic bone [6]). Some complications have been reported in the literature, such as cage subsidence, local kyphosis, and pseudoarthrosis, but none were related to compression fracture of cervical vertebrae [9, 11, 13, 15]. We have used the PEEK cage in our patients for years, but until the presented case had not encountered such a complication. In addition, to the best of knowledge there are no reported cases of cervical compression fracture related to the PEEK cage following anterior cervical discectomy. This compression fracture would ensue due to different factors in our case. MM patients experience spontaneous osteoporotic fractures in the spinal column and other bones due to the effect of myeloma-derived MIP-1 $\alpha$ , which activates osteoclasts via nuclear factor kappa B [2, 7]. The biomechanical properties of the peek cage are similar to those of normal bone, but not those of severe osteoporotic bone; hence, many patients with MM have more severe osteoporosis than those without MM. For example, the duration of the MM would be a contributing factor for the fracture risk due to osteoporosis.

A retrospective study that included 488 MM patients (52% male; mean age: 71.4 years) reported that 385 fractures occurred in 200 (41%) of the patients [17]. Compared to the expected fracture rate in the general population, the risk of vertebral fractures was higher (relative risk: 2.7), whereas the risk of appendicular fractures was not (relative risk: 1.1). We think that those findings were due to the effect of MIP-1 $\alpha$ . Furthermore, MM is a disease that affects the elderly, with a peak incidence between 65 and 70 years [4, 17], and osteoporosis frequently occurs in postmenopausal women [18]. Finally, we have sufficient evidence/data to explain the presented patient's compression fractures: her age (68 years), pre-existing osteoporosis associated with her age, corticosteroid treatment for MM, and, lastly and most importantly, the effect and infiltration of plasma cells on bone tissues [2, 5-7].

We scraped the presented patient's intervertebral spaces and osteophytic spurs with a bone curette to relieve the nerve roots. Had we scraped the end plate and uninvolved parts of the vertebrae (which we did not) it would have caused deterioration of the limited vertical loading capacity of the bone. Furthermore, PEEK cages have similar biomechanical properties as normal bone, but are much harder than the vertebrae affected by MM. We think that if the presented patient had been osteoporotic and MM negative, or we had we

performed 1-level discectomy, she would have had only embedding of the PEEK cage into the vertebrae, not the compression fracture that did occur. A few factors can lead to the complication observed in the presented case. These factors are severe osteoporosis due to MM and continuous corticosteroid treatment for MM, and infiltration of the bone with plasma cells. In addition, the cervical vertebrae exposed under pressure from the top and bottom—the pressure on both sides can induce compression fracture. In contrast, anterior plate augmentation would distribute the weight by maintaining the cervical lordosis, enhancing the stability of the fusion sites and preventing the peek cages from embedding into the vertebral bones following cervical discectomy.

We think that when performing multilevel cervical discectomy and placement of PEEK cages in a patient with MM, an anterior plate should be used to lower the risk of compression of the vertebrae located between 2 PEEK cages. In patients with compression fracture of the cervical vertebrae following anterior cervical discectomy, we recommend corpectomy and placement of a retractable titanium cage with an anterior plate to prevent further complications. In summary, consecutive multilevel cervical discectomy and placement of PEEK cages between intervertebral cervical disc spaces can cause compression fracture of the vertebrae located between the PEEK cages in osteoporotic patients under continuous corticosteroid treatment, whether or not they have MM. Additionally, use of an anterior plate to prevent this complication is suggested.

## References

1. Wright JH. A case of multiple myeloma. *J Boston Soc Med Sci.* 1900;4:195-204-5.
2. Kyle RA, Rajkumar SV. Criteria for diagnosis, staging, risk stratification and response assessment of multiple myeloma. *Leukemia.* 2009;23:3-9.
3. Wirk B. Renal failure in multiple myeloma: a medical emergency. *Bone Marrow Transplant.* 2011;46:771-83
4. Jemal A, Bray F, Center MM, et al. Global cancer statistics. *CA Cancer J Clin.* 2011;61:69-90.
5. Landgren O, Weiss BM. Patterns of monoclonal gammopathy of undetermined significance and multiple myeloma in various ethnic/racial groups: Support for genetic factors in pathogenesis. *Leukemia.* 2009;23:1691–1697.
6. Kyle RA, Gertz MA, Witzig TE, et al. Review of 1,027 patients with newly diagnosed multiple myeloma. *Mayo Clinic Proc.* 2003;78:21–33.
7. Durie BG, Salmon SE. A clinical staging system for multiple myeloma. Correlation of measured myeloma cell mass with presenting clinical features, response to treatment, and survival. *Cancer.* 1975;36:842-54.
8. Brooke NS, Rorke AW, King AT et al. Preliminary experience of carbon fiber cage prostheses for treatment of cervical spine disorders. *Br J Neurosurg.* 1997;11:221–227
9. Munoz FL, de las Heras BG, Lopez VC et al. Comparison of three techniques of anterior fusion in single-level cervical disc herniation. *Eur Spine J.* 1998;7:512–516
10. Song KJ, Lee KB. A preliminary study of the use of cage and plating for single-segment fusion in degenerative cervical spine disease. *J Clin Neurosci.* 2006; 13(2):181–187
11. Cho DY, Liao WR, Lee WY, Liu JT, Chiu CL, Sheu PC. Preliminary experience using a polyetheretherketone (PEEK) cage in the treatment of cervical disc disease. *Neurosurgery.* 2003; 51(6):1343–1349.
12. Song KJ, Taghavi CE, Hsu MS, Lee KB, Kim GH, Song JH (2010) Plate augmentation in anterior cervical discectomy and fusion with cage for degenerative cervical spinal disorders. *Eur Spine J.* 2010; 19:1677–1683.
13. Barsa P, Suchomel P. Factors affecting sagittal malalignment due to cage subsidence in standalone cage assisted anterior cervical fusion. *Eur Spine J.* 2007;16(9):1395–1400.
14. Schmieder K, Wolzik-Grossmann M, Pechlivanis I, Engelhardt M, Scholz M, Harders A. Subsidence of the wing titanium cage after anterior cervical interbody fusion: 2-year follow-up study. *J Neurosurg Spine.* 2006;4(6):447–453.
15. Kulkarni AG, Hee HT, Wong HK. Solis cage (PEEK) for anterior cervical fusion: preliminary radiological results with emphasis on fusion and subsidence. *Spine J.* 2007; 7(2):205–209.
16. Papadopoulos EC, Huang RC, Girardi FP, Synnott K, Cammisa FP. Three-level anterior cervical discectomy and fusion with plate fixation: radiographic and clinical results. *Spine.* 2006; 8:897–902.
17. Melton LJ, 3rd, Rajkumar SV, Khosla S, et al. Fracture risk in monoclonal gammopathy of undetermined significance. *J Bone Miner Res.* 2004;19:25–30.
18. Nasto LA, Fusco A, Colangelo D, Mormando M, Di Giacomo G, Rossi B, De Marinis L, Logroscino CA, Pola E. Clinical predictors of vertebral osteoporotic fractures in post-menopausal women: a cross-sectional analysis. *Eur Rev Med Pharmacol Sci.* 2012;16(9):1227-34.