

RESEARCH AND REVIEWS: JOURNAL OF DENTAL SCIENCES

Replantation of Avulsed Permanent Anterior Teeth: A Case Report.

Abu-Hussein Muhamad^{1*}, Watted Nezar², and Abdulgani Azzaldeen³.

¹Department of Pediatric Dentistry, University of Athens, Athens, Greece.

²Department of Orthodontics, Arab American University, Jenin, Palestine.

³Department of Conservative Dentistry, Al-Quds University, Jerusalem, Palestine.

Case Report

Received: 18/08/2014

Revised : 13/09/2014

Accepted: 17/09/2014

*For Correspondence

Department of Pediatric
Dentistry, University of
Athens, Athens, Greece.

Keywords: Permanent
teeth, avulsion,
replantatio, PDL

ABSTRACT

Tooth avulsion in the permanent dentition constitutes a dental emergency. Replantation of the avulsed tooth restores aesthetics and occlusal function shortly after the injury. This article describes the management of a 12-year old male with four avulsed anterior maxillary permanent teeth. The avulsed teeth were replanted and root canal treatment carried out after a short fixation. The result obtained was very satisfactory and the teeth remain in good functional status one year after replantation. Early treatment and regular attendance to clinic following replantation is an important factor for good result.

INTRODUCTION

Traumatic injuries have become more common these days and the incidences of dental trauma have become comparatively higher. Trauma might involve both the hard and soft tissues. The success of the treatment of traumatized teeth revolves around the status of periodontium since it is a vital structure. Hence treatment of traumatic injuries are quite complex and at times requires a multi disciplinary approach ^[1,2,3,4,5].

Avulsion is known as complete displacement of tooth from the alveolus. The incidences are 1% to 16% in permanent teeth and 7% to 13% in primary teeth in school going children age. Replantation for avulsed teeth should be carried out immediately. The maxillary incisors are frequently avulsed teeth while lower jaw is less affected ^[1,5,6].

The prognosis for avulsions improves if the periodontal ligament (PDL) cells are preserved ^[7,8,9]. Soder et al. and Andreasen have shown that when a tooth is avulsed from the socket, PDL cells on the root surface will remain viable if they are hydrated ^[5,10]. Vital PDL cells can reattach when replanted and viability is best maintained if the tooth is replanted within the first 15-20 minutes after avulsion ^[11]. Tissue transport medium, such as Viaspan® (DuPont Pharmaceuticals, Wilmington, DE) Fig.1 and Hank's Balance Salt Solution (HBSS) (Mediatech, Herndon, VA) Fig.2 have exceptional ability to keep cells alive and are considered to be superior storage media. Readily available storage media for an avulsed tooth, in order of preference, are milk, saliva and saline ^[12,13,14]. Another commercially available, antibiotic-free, protective medium is the emt TOOTHSAYER® (SmartPractice, Phoenix, AZ) Fig.3. Water is not recommended because the hypotonic environment damages the PDL cells. One study measured the average number of vital human lip fibroblasts remaining after 2-168 hours of storage in 3 media. This study showed that after 12 hours, Viaspan® was effective at keeping 72.9% of cells vital while HBSS and milk maintained the vitality of 70.5% and 43.4% cells, respectively ^[12].

Researchers have shown that relatively good success rate was achieved when the tooth is replanted immediately. Therefore this technique for replantation assumes that avulsed tooth should be located quickly and replanted at the site of injury itself if possible before reaching to the dentist. If not the

tooth has to be Fig.4 immediately placed in a suitable transport medium like saliva, buccal vestibule, milk, coconut water etc. In a tooth with an open apex there are possibilities of revascularization of the pulp as well as continued root development [1,2,7,12].

The speed with which the avulsed tooth is replanted is the most important factor for success [8,9].

There are several possible effects on the root surface and attachment apparatus of an avulsed tooth.

- Normal PDL healing: complete regeneration of the PDL. Damage cannot be clinically or radiographically detected.
- Surface resorption: the crushing injury is restricted, inflammatory response is limited and repair can occur with replacement cementum. Clinically, the tooth presents asymptomatic, with normal mobility and percussion sounds. Radiographically, there are no periradicular radiolucencies and no loss of lamina dura [15].
- Ankylosis and replacement resorption: occurs when excessive drying damages the PDL cells and evokes an inflammatory response that results in the replacement of the cells with alveolar bone. Dentoalveolar ankylosis is the term used when precursor bone cells populate the damaged root resulting in a direct bone-root contact void of an attachment apparatus. Replacement resorption occurs when osteoclasts in contact with the root resorb dentin that is eventually replaced with new bone by osteoblasts. Clinically, the tooth will be immobile and have a high-pitched sound when percussed. Radiographically, there is absence of the lamina dura. With replacement resorption, the root surface appears moth-eaten [15]. In young patients, infraocclusion or submergence results when replacement resorption interferes with the tooth's ability to move with the normal downward growth of the alveolar process.

External inflammatory root resorption: the result of a combination of severely damaged attachment and bacterial contamination of a necrotic pulp. It may rapidly progress. Clinically, it presents as radiolucencies in the root and adjacent bone [15].

Case Report

A 12 year old boy reported to our pediatric dental clinic with avulsed maxillary right central incisor, lateral incisor and canine after one hour of injury. The teeth were soaked in a water. There was swelling and lacerations on upper lip and lower lip. His parents and boy, both were very anxious and disturbed due to loss of front teeth. They were assured that his teeth could be saved and they were relaxed. The teeth were rinsed with water and placed in a saline solution. Fig.5

Local anesthesia was given and as much care was taken not to hold teeth by root to save the vitality of periodontal ligament. The debris of dust and dead tags of the tissues over root were removed with wet sponge of saline very gently. Then sockets were prepared for replantation. Sockets were gently aspirated and irrigated with saline, then the teeth were replaced in the sockets and manually compressed to its original position. Knocked out tooth. If a permanent tooth has been knocked out of its socket (avulsed), immediate attention is required.

Then the teeth were splinted with ligature wire and interdental wiring was performed along with light cure composite resin. Patient was kept under antibiotics and analgesics. He was advised for tetanus consultation within 48 hours Fig.7. Patient was also advised not to bite on splinted teeth and to take soft diet and ask to maintain good oral hygiene by proper brushing and chlorhexidine rinses 12%. In the present case patient was tried for replantation in an attempt to revitalize pulp. Patient was called after six to eight weeks because of partly involvement of alveolar bone Fig.8,9.

After eight weeks splinting was removed and it was found that teeth were strongly adhered to the socket and there was no mobility at all Fig.10. Patient was complaining of mild pain while percussion. After clinical and radiographical evaluation root canal treatment was performed. Patient was recalled at interval of every six months. There was no sign of pain, mobility found within six months. Patient was kept under observation for further evaluation Fig.11,12.

DISCUSSIONS

A traumatic dental injuries are emergencies that the dentist must be able to assess rapidly and manage appropriately. The determination of treatment plan is very important in case of avulsed teeth. In present study a 12 year old boy with avulsed right maxillary incisors was treated with replantation technique. After thorough investigation of vitality of teeth the root canal treatment was done after six weeks of replantation not at the time of replantation with the hope to revascularize the pulp because pulpal necrosis is usually demonstrated after three weeks. The results in this case were satisfactory clinically as well as radiographically and patient was kept under observation for further study [1,2,4,5,6].

The patient will generally present with one of three clinical scenarios

- The tooth has already been replanted. Do not extract the tooth. Simply cleanse the area with water spray, saline, or a 0.1% chlorhexidine mouth rinse.
- The tooth has been kept in an appropriate storage media or the extra-oral dry time has been less than 60 minutes. The contaminated root surface should be cleaned with saline. If needed, the tooth can be stored in a storage media such as HBSS or Viaspan while a trauma examination is quickly performed. Assessment of the socket and surrounding teeth and bone by palpating and radiographing the injured site will determine whether the socket is intact and suitable for replantation. Fractures of the socket wall should be repositioned prior to replantation. Coagulum can be removed from the socket with a stream of sterile saline to facilitate slow, slight digital pressure replantation. Fig.13,14,15
- The tooth has an extra-oral dry time of more than 60 minutes. The root surface PDL cells are not expected to survive. Assess the injured socket and surrounding area for fractures and reposition prior to replantation. Remove the coagulum with sterile saline only. Do not curette the socket. The PDL should be removed by soaking the tooth for 5 minutes in 2.4% sodium fluoride solution acidulated to a pH of 5.5. This procedure will remove the damaged tissue that would otherwise initiate an inflammatory response [7,8]. The use of an enamel matrix protein, Emdogain® (Biora, Malmö, Sweden), is now recommended because recent studies demonstrate that it may make the root more resistant to resorption and promote the growth of a new PDL from the socket [16,17]. The socket can be filled with Emdogain® prior to replantation of a tooth with an extra-oral dry time of greater than 60 minutes (7). It may also be valuable in cases where the extra-oral dry time is 20-60 minutes [8]. Revascularization of the pulp in an avulsed tooth with a mature, closed apex is not possible. The root canal treatment can be done prior to replantation if the extra-oral dry time is greater than 60 minutes, but care must be taken to keep the canal space bacteria-free. Fig.16,17

Pulpal tissue of teeth with closed apices cannot survive an avulsion injury and must be removed. Endodontic treatment for all avulsed permanent teeth with a closed apex should be initiated, and calcium hydroxide placed at 7-10 days. Usually after one month, when an intact lamina dura can be traced around the root surface, the calcium hydroxide can be replaced with gutta-percha. If endodontic treatment has been delayed, and there is radiographic evidence of root resorption, calcium hydroxide is needed for an extended period of time and the status of the lamina dura should be checked every 3 months. Fig.18.

The same concerns for viability of the PDL on avulsed permanent teeth with open apices apply to those with closed apices and treatment guidelines are also based on the tooth's extra-oral dry time [18,19].

- The tooth has already been replanted. The area should be cleaned with water spray, saline or a 0.1% chlorhexidine mouth rinse.
- The tooth has been kept in a storage media for less than 60 minutes. Clean the contaminated root surface with a stream of sterile saline. Prior to replanting, soak the tooth in a solution of doxycycline (1mg/20ml saline). Examine the socket for suitability, remove the coagulum with sterile saline, and replant slowly with slight digital pressure.
- Current guidelines recommend that teeth with open apices and extra-oral dry times of greater than 60 minutes not be replanted. Studies and debate are ongoing to determine if there are situations when replanting a tooth can maintain the height and width of the alveolar bone in a growing child.

A replanted tooth is determined to have a satisfactory outcome if it is asymptomatic, has normal mobility and eruption pattern, normal sound to percussion, and tests positive to vitality tests. It is important to note that it may take up to 3 months to respond positively to vitality testing. Radiographically,

continued root development is expected. An unsatisfactory outcome includes symptoms, high-pitched percussion sound, infra-occlusion, arrested development of the root and a pulp lumen unchanged in size. At the first definite signs of failure, the necrotic pulp must be removed and apexification treatment initiated [7,8].

Figure 1: VaSpan fluid



Figure 2: HBSS 1X Hanks' Balanced Salt Solution is designed to maintain pH and osmotic balance and to provide cells with water and essential inorganic ions.



Figure 3: Save-A-Tooth - Tooth Saver

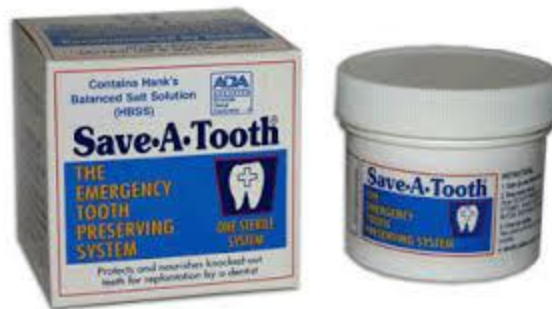

Figure 4: Dental avulsion

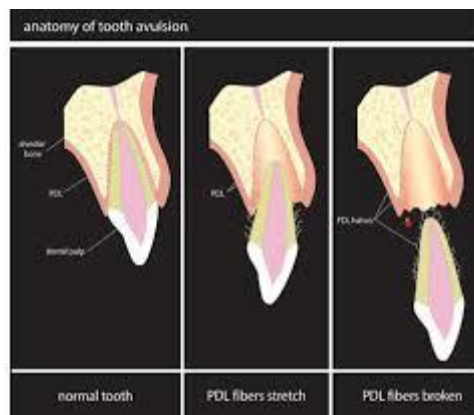


Figure 5: Tooth transferred to solution of sodium fluoride

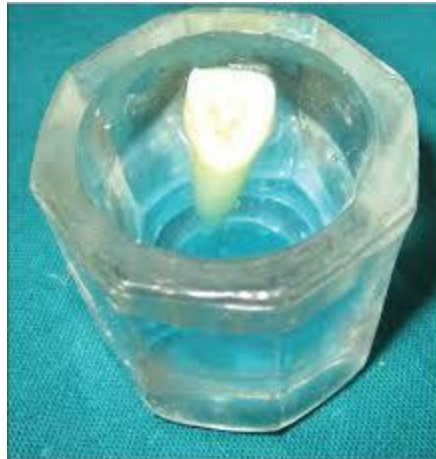

Figure 6: Pre-operative intraoral periapical radiograph showing extensive bone loss

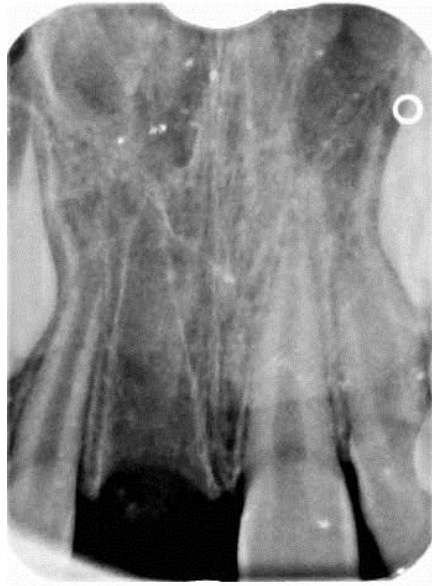

Figure 7: Splinted from maxillary primary canine to canine with a Flexible Niti wire.

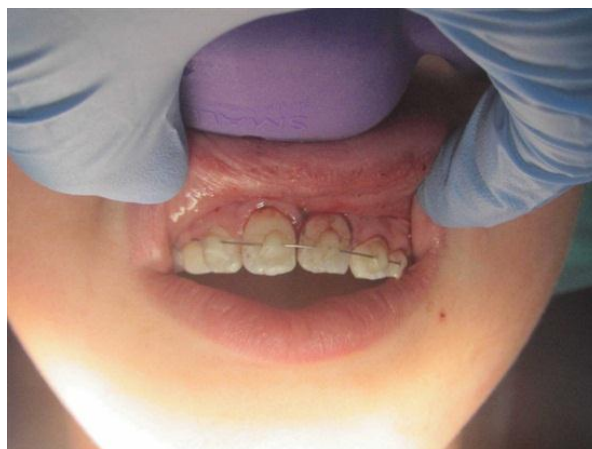

Figure 8: Post-operative intraoral periapical radiograph taken after 7 days, to ascertain alignment of tooth and apical positioning

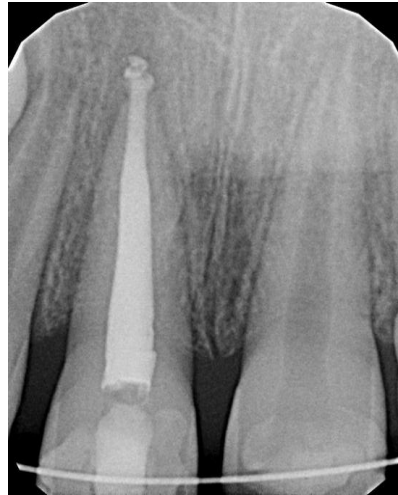

Figure 9: Post-operative intraoral periapical radiograph taken after 30 days, to ascertain alignment of tooth and apical positioning

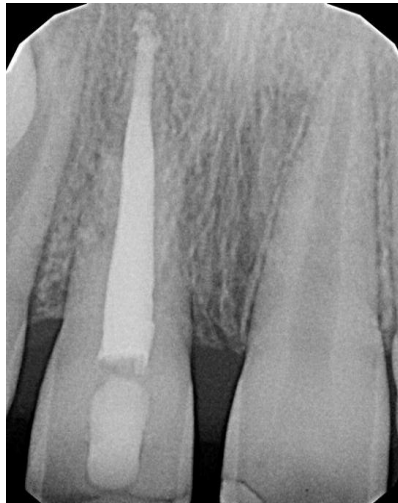

Figure 10: Post-operative intraoral periapical radiograph taken after 3 months, to ascertain alignment of tooth and apical positioning

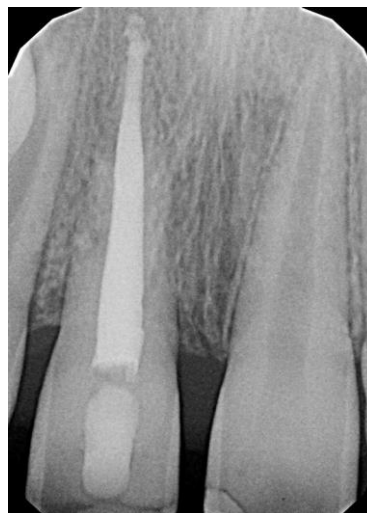

Figure 11: Intraoral periapical radiograph 6 months post-operative

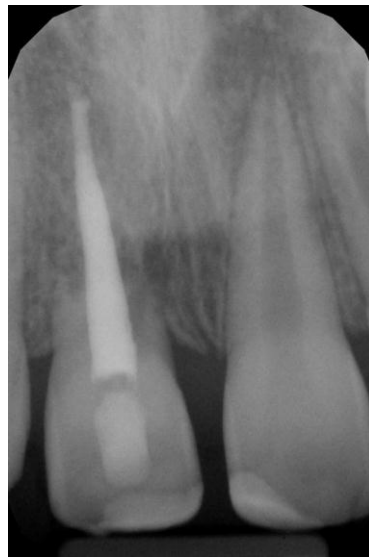

Figure 12: Esthetic outcome after splint removal, core placement and composite buildup

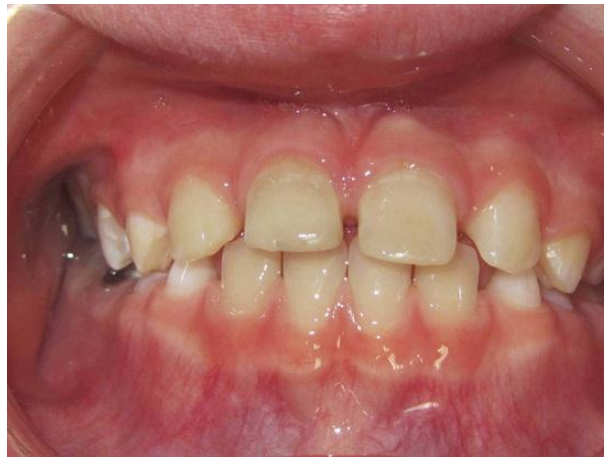

Figure 13: Knocked out tooth. If a permanent tooth has been knocked out of its socket (avulsed), immediate attention is required.

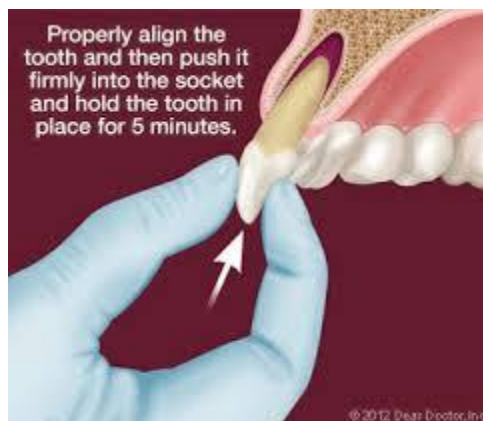

Figure 14: The tooth has been kept in a medium of physiologic osmolarity (saliva, milk, saline, or tissue culture medium). The extraoral time is less than 60 min.

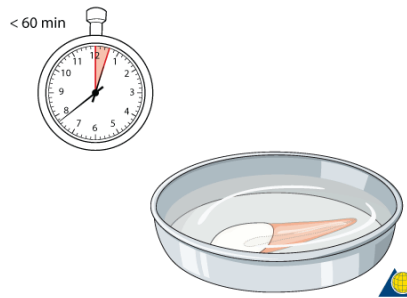


Figure 15: The tooth has been replanted prior to the patient arriving at the dental office or clinic

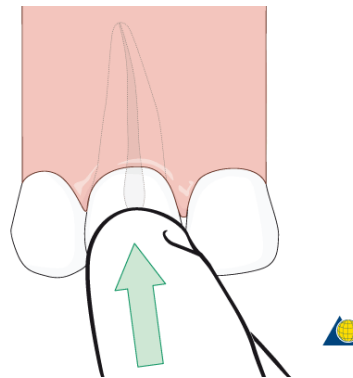


Figure 16: The tooth has not been kept in a medium of physiologic osmolarity (saliva, milk, saline, or tissue culture medium), eg, tap water, or dry storage for the first 60 minutes posttrauma or more.

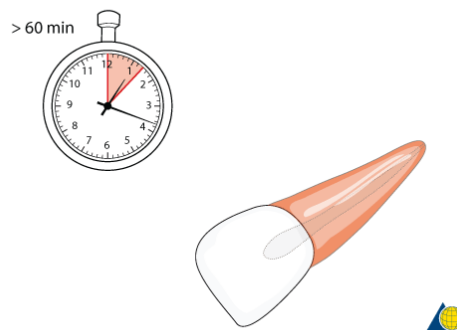


Figure 17: Delayed replantation has a poor long-term prognosis. The periodontal ligament has dried out or necrosed and cannot heal to normal periodontal attachment. A replacement resorption (ankylosis) is inevitable. The tooth may still be replaced, not least for psychological reasons and for gaining time in decision making for definitive treatment

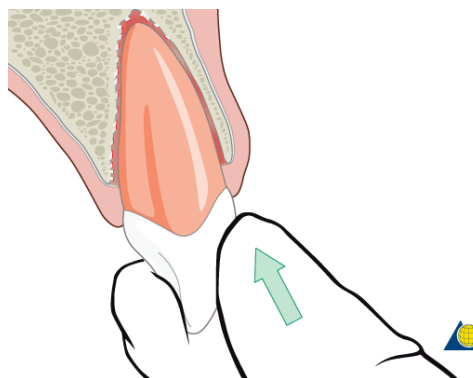
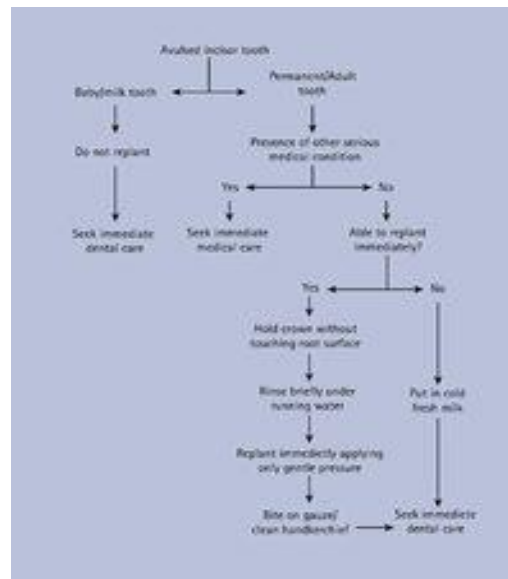


Figure 18: Protocol for emergency management of an avulsed incisor



CONCLUSION

The success of avulsed tooth is directly proportional to the time and storage type of the tooth. Clinical studies have shown that teeth replanted within 20-30 minutes have the best prognosis, so reattachment success will be much higher. The choice of storage for preserving traumatically avulsed teeth is important for the success of future replantation. Ideally, the tooth should be stored in milk, saliva, physiological saline and clean water. Follow-up appointments: include splint removal and initiation of endodontic treatment, if required, at one week. Clinical and radiographic exams should be scheduled at 2-3 weeks, 3-4 weeks, 6-8 weeks, 6 months, 1 year and annually for 5 years.

REFERENCES

1. Andreasen FM, Andreasen JO. Textbook and color atlas of traumatic injuries to the teeth. 3rd ed. St Louis: Mosby, Inc.;1994; 383-425.
2. Andreasen JO. Etiology and pathogenesis of traumatic dental injuries. A clinical study of 1298 cases. Scand J Dent Res. 1970;78(4):329-42.
3. Hedegård B, Stålhane I. A study of traumatized permanent teeth in children aged 7-15 years. Part I. Swed Dent. J 1973;66(5):431-52.
4. Lenstrup K, Skieller V. A follow-up study of teeth replanted after accidental loss. Acta Odontol Scand. 1959;17:503-9.
5. Andreasen JO. Effect of extra-alveolar period and storage media upon periodontal and pulpal healing after replantation of mature permanent incisors in monkeys Int J Oral Surg. 1981 ;10(1):43-53.
6. Cvek M, Granath LE, Hollender L. Treatment of non-vital permanent incisors with calcium hydroxide. III. Variation of occurrence of ankylosis of reimplanted teeth with duration of extra-alveolar period and storage environment. Odontol Revy. 1974;25(1):43-56.
7. American Association of Endodontists. Recommended Guidelines of the American Association of Endodontists for the Treatment of Traumatic Dental Injuries. Chicago; 2003.
8. Trope M. Clinical management of the avulsed tooth: present strategies and future directions. Dent Traumatol. 2002;18(1):1-11.
9. Diangelis AJ, Bakland LK. Traumatic Dental Injuries: current treatment concepts. J Am Dent Assoc. 1998;129(10):1401-14.
10. Soder PO, Otteskog P, Andreasen JO, Modeer T. Effect of drying on viability of periodontal membrane. Scand J Dent Res. 1977;85(3):164-8.
11. Barrett EJ, Kenny DJ. Avulsed permanent teeth: a review of the literature and treatment guidelines. Endod Dent Traumatol. 1997;13(4):153-63.
12. Hiltz H, Trope M. Vitality of human lip fibroblasts in milk, Hank's balanced salt solution and Viaspan storage media. Endod Dent Traumatol. 1991;7(2):69-72.

13. Trope M, Friedman S. Periodontal healing of replanted dog teeth stored in Viaspan, milk and Hank's balanced salt solution. *Endod Dent Traumatol.* 1992;8(5):183-8.
14. Blomlof L. Milk and saliva as possible storage media for traumatically exarticulated teeth prior to replantation. *Swed Dent J Suppl* 1981;8:1-26.
15. Trope M, Chivian N, Sigurdsson A, Vann WF Jr. Traumatic injuries. In Cohen S, Burns RC, editors: *Pathways of the pulp.* 8th ed. Philadelphia: Mosby Inc.; 2002;623-631.
16. Iqbal MK, Bamaas N. Effect of enamel matrix derivative (EMDOGAIN ®) upon periodontal healing after replantation of permanent incisors in beagle dogs. *Dent Traumatol.* 2001;17(1):36-45.
17. Filippi A, Pohl Y, Von Arx T. Treatment of replacement resorption with Emdogain ® - preliminary results after 10 months. *Dent Traumatol.* 2001;17(3):134-8.
18. Cvek M, Cleaton-Jones P, Austin J, Lownie J, Kling M, Fatti P. Effect of topical application of doxycycline on pulp revascularization and periodontal healing in reimplanted monkey incisors. *Endod Dent Traumatol.* 1990;6(4):170-6.
19. Yanpiset K, Trope M. Pulp revascularization of replanted immature dog teeth after different treatment methods. *Endod Dent Traumatol.* 2000;16(5):211-7.
20. Tsukiboshi M. Autotransplantation of teeth: requirements for predictable success. *Endod Dent Traumatol.* 2002;18:157-80.
21. Sae-Lim V, Wang CY, Choi GW, Trope M. The effect of systemic tetracycline on resorption of dried replanted dogs' teeth. *Endod Dent Traumatol.* 1998;14(3):127-32.
22. Sae-Lim V, Wang CY, Trope M. Effect of systemic tetracycline and amoxicillin on inflammatory root resorption of replanted dog's teeth. *Endod Dent Traumatol.* 1998;14(5):216-20.