



COMPLEX TREATMENT IN A PATIENT WITH SEVERE CHRONIC PERIODONTITIS (Case Report)

Kamen Kotsilkov¹, Radoi Dimitrov²

1) Department of Periodontology, Faculty of Dental Medicine, Medical University, Sofia.

2) Student at Faculty of Dental Medicine, Medical University, Sofia

ABSTRACT:

INTRODUCTION: Periodontitis is characterized by progressive destruction of periodontium, caused by relatively small group of microorganisms. The treatment aims to create proper environment which hampers the colonization of pathogens. The mechanical cleaning of the root surfaces combined with meticulous oral hygiene is the consensus treatment. In advanced cases the progression of the disease could lead to different problems - gingival recessions, insufficiency of attached gingiva, mobility and tooth loss which require complex treatment.

OBJECTIVE: This presentation demonstrates the multidisciplinary treatment approach in a patient with a severe chronic periodontitis.

METHODS: S.S. (42) with severe chronic periodontitis, insufficient mandibular vestibule depth, lack of keratinized gingiva, class III recessions and central incisors with grade III mobility. The #12 is missing and a crossbite is present on #32. The anti-infective therapy led to stable periodontal status. The corrective phase included the creation of vestibule depth with an autogenous gingival graft, dental implant placement with immediate provisional loading for #12, extraction of #31 and #41 due to attachment loss to the apex and immediate placement of provisionals with crossbite correction.

RESULT: The reevaluation demonstrated good control of the gingival inflammation and stable periodontal status. The subsequent implant and prosthetic treatment led to the restoration of a functional dentition.

CONCLUSION: The long term success of the treatment of the complex cases with severe chronic periodontitis depends significantly upon the proper control of the periodontal infection and the achievement of a stable periodontal status. These are the major prerequisites for successful further implant and prosthetic rehabilitation.

Key words: multidisciplinary dental rehabilitation, chronic periodontitis, autogenous gingival graft, dental implants, immediate loading.

INTRODUCTION:

Periodontitis is a disease characterized by progressive destruction of the periodontium (connective tissue attachment and alveolar bone) which is caused by relatively small group of microorganisms inhabiting the subgingival biofilm.[1]

The goal of the treatment is to create proper oral environment which hampers the further colonization of peri-

odontal pathogens. The consensus opinion is that the mechanical cleaning of the root surfaces (scaling and root planing) combined with meticulous oral hygiene is the proper treatment of the periodontitis.[2]

However in advanced cases the progression of the disease could lead to different problems incl. gingival recessions, insufficiency of attached gingiva, tooth mobility and tooth loss which require complex treatment.[3, 4]

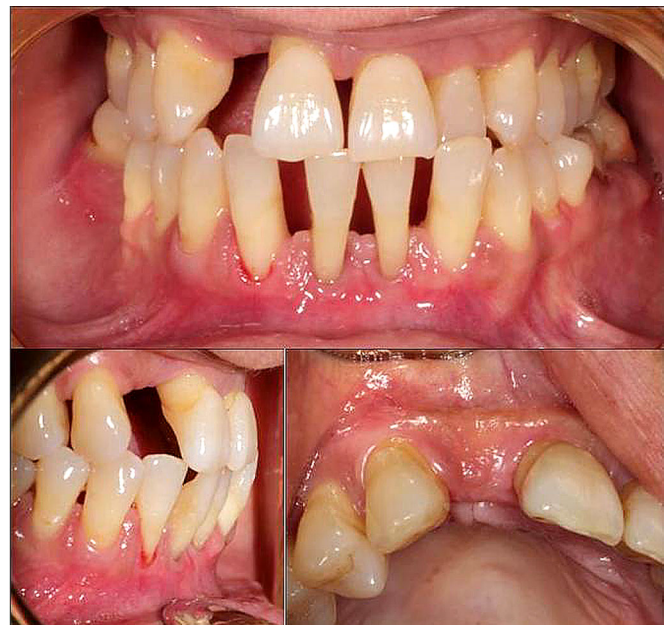OBJECTIVE:

The goal of this presentation is to demonstrate the multidisciplinary treatment approach in a patient with a severe chronic periodontitis.

METHODS:

S.S. (42) with a severe chronic periodontitis (HI 31%, PBI 2,13/66%, PD (0-3 mm) = 38%; PD (3-5 mm) = 54%; PD (5-7 mm) = 8%, CAL: 99%/4.5mm. In the lower mandibular segment an insufficient vestibule depth with a lack of keratinized gingiva and Miller class III gingival recessions are observed. Both central incisors had III grade mobility. Furthermore the right maxillary lateral incisor is missing and a crossbite is present on the left mandibular lateral incisor [Fig.1).

Fig. 1. Initial status.



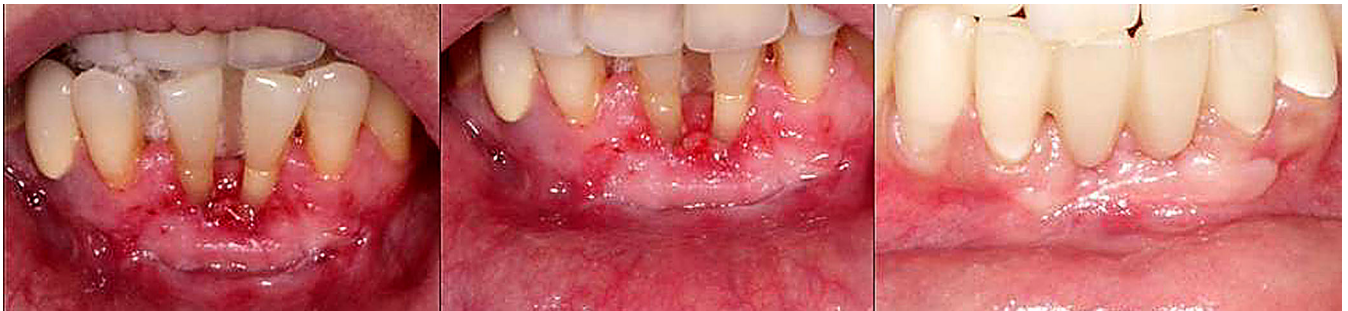The anti-infective periodontal therapy achieved good control of the oral hygiene (HI-79%) and gingival inflammation (PBI 0,12/9%) thus leading to a stable periodontal status - PD (0-3 mm) = 73%; PD (3-5 mm) = 27%; PD (5-7 mm) = 0%; CAL 76%/3 mm.

The treatment plan of the corrective phase of the periodontal treatment included the creation of sufficient ves-

tibule depth with an autogenous gingival graft, dental implant placement with immediate provisional loading for tooth #12, extraction of teeth #31 and #41 due to attachment loss to the apex and immediate placement of long-term provisional restoration with correction of the crossbite.

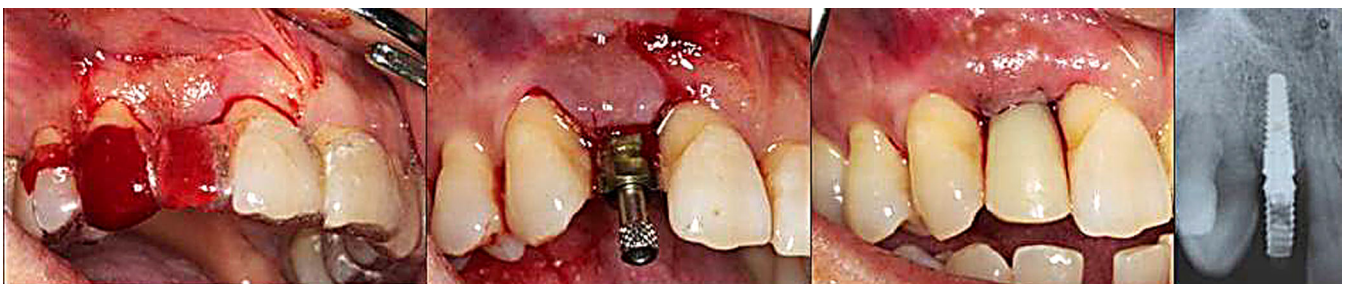
Procedure for gingival augmentation and correction of the vestibule depth with autogenous gingival graft. (Fig. 2)

Fig. 2. Autogenous gingival graft.



Placement of 3,5/12 mm implant Natural + (Euroteknika) with immediate screw retained provisional restoration on temporary abutment. (Fig. 3)

Fig. 3. Placement of dental implant with immediate provisional restoration in regio #12.



Extraction of the mandibular central incisors and placement of the immediate CAD-CAM fabricated provisional restoration with the correction of the cross-bite of the left lateral incisors. The “bullet shape” design of the provisional central incisors ensures the preservation of the interdental papilla's (Fig. 4).

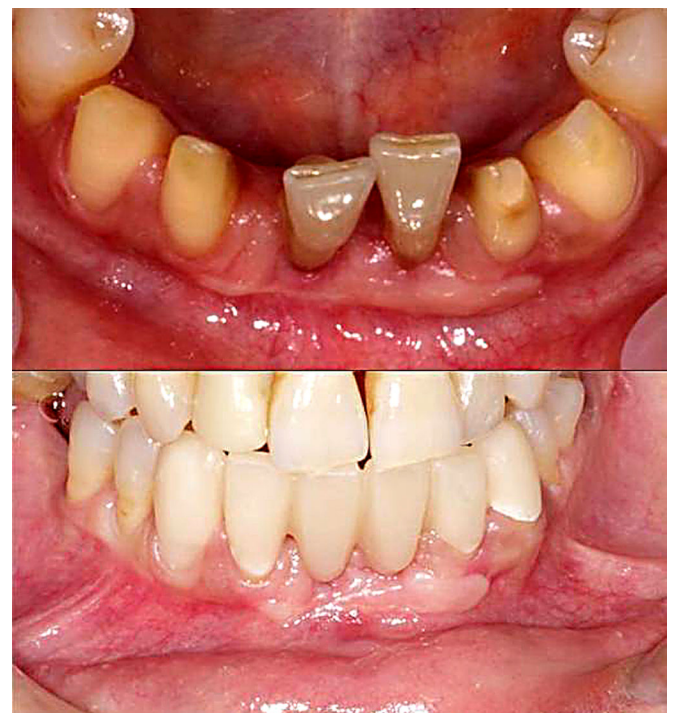
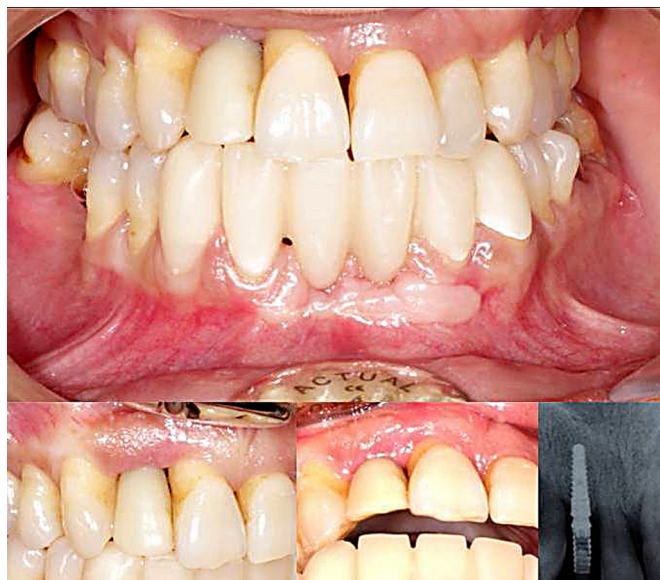
Fig. 4. Immediate provisional restoration in frontal mandibular region.

RESULT:

The reevaluation six months after the anti-infective periodontal therapy demonstrated a stable periodontal status. The subsequent implant and prosthetic treatment led to the restoration of a functional dentition (Fig. 5).

Fig. 5. Result on sixth month.



CONCLUSION:

The long term success of the treatment of the complex cases with severe chronic periodontitis depends significantly upon the proper control of the periodontal infection and the achieving of a stable periodontal status. These are the major prerequisites for successful further implant and prosthetic rehabilitation. In the presented case this approach led to successful treatment of the patient with the restoration of a functional dentition.

REFERENCES:

1. Teles R, Teles F, Frias-Lopez J, Paster B, Haffajee A. Lessons learned and unlearned in periodontal microbiology. *Periodontology 2000*. 2013 Jun;62(1):95-162. [PubMed] [CrossRef]
2. Caffesse RG, Mota LF, Morrison EC. The rationale for periodontal therapy. *Periodontology 2000*. 1995 Oct;9(1):7-13. [CrossRef]
3. Mohan CS, Harinath P, Cholan PK, Kumar DL. Predictable aesthetic outcome with immediate placement and early loading of one piece mini implant - A 5 year follow-up case report. *J Int Oral Health*. 2014 Apr;6(2):132-135. [PubMed]
4. Cosyn J, Eghbali A, Hanselaer L, De Rouck T, Wyn I, Sabzevar MM et al. Four modalities of single implant treatment in the anterior maxilla: a clinical, radiographic, and aesthetic evaluation. *Clin Implant Dent Relat Res*. 2013 Aug;15(4):517-30. [PubMed]

Please cite this article as: Kotsilkov K, Dimitrov R. COMPLEX TREATMENT IN A PATIENT WITH SEVERE CHRONIC PERIODONTITIS (Case Report). *J of IMAB*. 2015 Jan-Mar;21(1):687-689. DOI: <http://dx.doi.org/10.5272/jimab.2015211.687>

Received: 26/09/2014; Published online: 02/02/2015



Address for correspondence:

Kamen Kotsilkov, Assistant Professor at Department of Periodontology, Faculty of Dental Medicine, Sofia, 1, St. Georgi Sofiiski Blvd., 1431 Sofia, Bulgaria.
E-mail: kamenkotsilkov@gmail.com,