



HEME OXYGENASE-1 UPREGULATED BY MELATONIN: POTENTIAL PROTECTION AGAINST BURN-INDUCED OXIDATIVE GASTRIC MUCOSAL INJURY

Minka Hristova¹, Ganka Bekyarova¹, Maria Tzaneva²

1) Division of Pathophysiology, Faculty of Medicine, Medical University of Varna, Bulgaria

2) Department of Clinical and Preclinical Sciences, Faculty of Pharmacy, Medical University of Varna, Bulgaria

SUMMARY

Melatonin is indoleamine hormone derived from L-tryptophan. Due to its lipophilic nature, it is accessible to every cell. Melatonin has immunomodulatory and antioxidant activities thus protecting tissue injury. Heat shock proteins such as HSP32 known as heme oxygenase-1 (HO-1) possesses antioxidant, anti-inflammatory, and vasodilatory properties and plays an important role in the protecting of tissues from several stresses. The aim of study is to investigate the expression of HO-1 in gastric mucosa and its connection with oxidative stress and melatonin mediated protection after thermal injury. On rats back, under anesthesia, third degree burn was applied involving 30% of total body surface area (TBSA). Melatonin (10 mg per kg body mass) was injected i.p. immediately and 12 hours after thermal skin injury. We used tissue malondialdehyde (MDA), lipid peroxidation product, as a marker of oxidative stress. Gastric mucosa histopathology were observed on light microscopy and light immunohistochemistry investigating the HO-1 too. Results: The levels of MDA in gastric mucosa were elevated ($p < 0.05$). The HO-1 expression was significantly increased in rats with trauma. Melatonin inhibited elevation in lipid peroxidation product and augmented the increase in expression of HO-1 in the gastric mucosa. In conclusion, our data suggest that HO-1 induction following burn injury is an adaptive response protecting gastric mucosal against further oxidative damage. Melatonin increased the antioxidant capacity and restricted burn-induced oxidative damage in gastric mucosa and thus could be used therapeutically in organ protection.

Key words: melatonin, heme-oxygenase 1, oxidative stress, gastric mucosa, thermal injury

INTRODUCTION

Cutaneous burn injury causes gastric mucosal injury, alters mucosal integrity and leads to breakdown in mucosal defense - from superficial epithelial lesions to severe destructive alterations involving the underlying tissues [1, 2]. The underlying mechanism of the greater mucosal damage induced by thermal trauma is not clear. Some reports refer to several possible mechanisms including decreased gastric mucosal blood flow, changes in nitric oxide (NO) and pro-

taglandin (PG) production and increased free radical formation [3, 4].

Heme oxygenase-1 (HO-1) is a rate-limiting enzyme of heme degradation into its products carbon monoxide, free iron and biliverdin. The induction of HO-1 expression is considered a primary adaptive response of the cellular defence mechanism under oxidative stress, inflammation, ischemia and reperfusion, irradiation, hypoxia, hyperoxia, heavy metal action [5]. The enzyme accomplishes its antioxidant, antiinflammatory and antiapoptotic effects through its end products [5, 6]. HO-1 overexpression by pharmacological drug induction has been used to reduce the deleterious effect of free radicals, oxidative stress and apoptosis in various cell types and animal models. There are no data about changes in HO-1 activity after thermal injury.

Melatonin is an indole compound synthesized in the pituitary gland and many extrapineal tissues as well. It is widely disseminated in the organism and presents with pleiotropic properties, e.g. antioxidative, antiinflammatory and antiapoptotic. It has already been used as gastro-protective agent in some clinical investigations [7] and experimental models of damaged gastric mucosa [8, 9].

Melatonin increases HO-1 activity and contributes to the restriction of tissue oxidative damage [10]. We hypothesize that melatonin protects against reduces burn-induced oxidative gastric mucosal injury by HO-1 activation. To test this hypothesis, we examined the effect of melatonin on oxidative stress (using MDA as marker of peroxidation) HO-1 expression in gastric mucosa after experimental burns.

MATERIALS AND METHODS

Experimental thermal skin injury

All procedures were conducted in compliance with the national laws and policies, in conformity with the international guidelines.

Age-matched male rats weighing between 220 and 250 g fasted for 12 h were allowed free access to water before injury. Animals were housed in a 20°C and offered rat chow and water ad libitum. They were kept in dark/light cycles (12:12 h) in individual wire-bottomed cages. Thus, lights were turned off at 8:00 p.m. and turned on at 8:00 a.m. for achieving the satisfactory photoperiod. After light ether inhalation, general anesthesia was intraperitoneally

performed using thiopental (30 mg/kg). In order to accomplish 30% of third degree burn hot boiling water (98° C) was applied on the back of the animals during a period of 10 sec. For those rats which were subjected to burn injury, 4 mL of physiological saline was intraperitoneally applied for immediate resuscitation after the trauma. No animals died within the first 24 h of post-burn period.

Twenty male Wistar rats were randomly assigned to three groups: non-burned rats (controls (C, n = 6); vehicle-treated, burned rats (B, n = 7); and melatonin-treated, burned rats (B + M, n = 7).

All the animals were intraperitoneally given buprenorphine (0.3 mg/kg b.w.) twice daily for pain control post-burn. They were re-anesthetized with thiopental and sacrificed 24 h after burns as stomach was sampled.

Histopathological analysis

Tissue specimens were fixed in 10% buffered formalin (pH 7.2), dehydrated in ascending series of ethyl alcohol (70%-100%), cleared in methyl benzoate and embedded in paraffin wax. Tissue sections of 5 µm were stained with hematoxylin and eosin (H&E) and examined using light microscope (Olympus BH-2, Tokyo, Japan). Histopathological changes were examined at a magnification of 400x (high power field).

Biochemical analysis

Membrane lipid peroxidation was assayed by Malonaldehyde (MDA) measured by its thiobarbituric acid (TBA) reactivity of stomach homogenate using the method of Porter et al. [11]. Results were expressed as nmol MDA/g tissue. They were determined using the extinction coefficient of MDA-TBA complex at 532 nm = $1.56 \times 10^5 \text{ cm}^{-1} \text{ M}^{-1}$ solution.

Immunohistochemistry

Rat stomach specimens were fixed in 10% neutral buffered formalin and embedded in paraffin. The deparaffinized and dehydrated sections (5 µm thick) were treated with 1% hydrogen peroxide for peroxidase activity inhibition for 5 min. Then they were rinsed in 0.1 M phosphate buffered saline (PBS) (pH 7.4) and treated in normal goat serum for 20 min. Subsequently, the sections were incubated with polyclonal primary antibody for 24 h at room temperature. Rabbit anti-HO-1 antibody (Santa Cruz, USA) was used. After rinsing with PBS, the sections were incubated for 20 min in goat anti-rabbit immunoglobulins at room temperature. Then they were rinsed in PBS again, treated with rabbit peroxidase-antiperoxidase complex for 20 min at room temperature and then rinsed in PBS. Finally, peroxidase activity was estimated by the diaminobenzidine-tetrachloride H₂O₂-method. Negative controls were incubated with non-immune sera instead of primary antibody.

Statistical analysis

Using GraphPadInStat software, the data were statistically analysed using a one-way analysis of variance (ANOVA) and expressed as mean ±SEM. The level of significance was determined by unpaired Student's t test. A value of $p < 0.05$ was considered statistically significant.

RESULTS

Histological results

In control group the surface and glandular epithelium of gastric mucosa was intact (Fig. 1A). In the burned group were degeneration of the surface and glandular epithelium of gastric mucosa with loss of surface epithelial cells. Hyperemia (vascular congestion) and leukocyte infiltration was found (Fig. 1B). The gastric mucosa of melatonin-treated rats was almost intact. The congestion and leukocyte infiltration were minimal (Fig. 1C).

MDA levels in gastric mucosa

Gastric mucosal MDA levels in the burned group were significantly higher (by 43%, $p < 0.05$) than those of the control one (Fig. 2). In the melatonin-treated group, tissue levels were diminished, remaining close to the control values.

HO-1 expression in gastric mucosa

HO-1 expression was low and was localized in endothelial cells in the upper part of the mucosa in the control group (Fig. 3A). In the burned group, HO-1 content of the endothelial cells was moderate and mainly in endothelial cells in the upper part of the mucosa (Fig. 3B). HO-1 expression in the melatonin-treated group was moderate to high and was found in both endothelial cells and epithelial cells (Fig. 3C).

DISCUSSION

Our results showed a significant MDA increase as a marker of lipid peroxidation in stomach including with histopathological alterations such as degenerative changes in gastric mucosa in the rat model of burns. The present findings showed that administration of melatonin decrease oxidative gastric mucosal injury by upregulation of HO-1 expression.

Burn induced gastro-intestinal mucosal injury [12, 13]. Oxidative stress is crucial in pathogenesis of these changes. Ischaemia due to vasospasm in the splanchnic area and inadequate perfusion cause overproduction of oxygen-derived free radicals [14, 15]. Our data demonstrated microcirculatory disorders with congestion and leukocyte infiltration as well as degeneration of the surface and glandular epithelium. It could be assumed that activation of leukocytes and xanthine/xanthine oxidase system under condition of ischemia and microcirculatory disorders are potential source of free oxygen radicals in the stomach. The excessive free radicals and cytokines, e.g. TNF- α , interleukin 6 (IL-6) generated from inflammatory cells and the activation of lipid peroxidation may cause cell membrane destruction and degenerative changes in gastric mucosa. Oxidative stress is recognized as an important mechanism of apoptosis of epithelial cells in gastric mucosal injury [16].

Melatonin treatment limits congestion and leukocyte infiltration and degeneration of the surface and glandular epithelium and loss of surface epithelial cells of gastric mucosa as well. As a scavenger of both oxygen- and nitrogen-based reactants, it inhibits the recruitment of inflammatory

Fig. 1. Effect of melatonin on histomorphological changes in gastric mucosa after burn. Controls (A); burned rats (B); burned rats, treated with melatonin (C). (H&E staining, original magnification, x400).

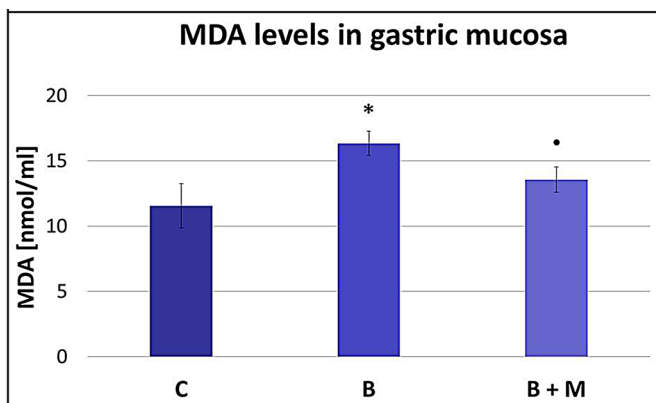
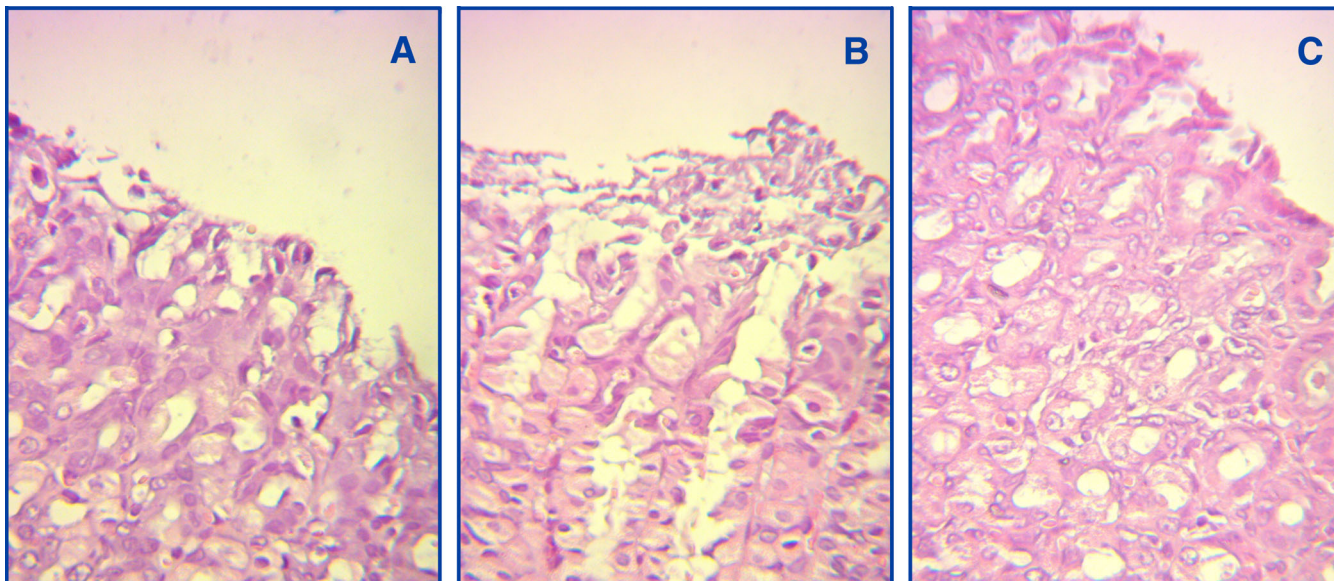
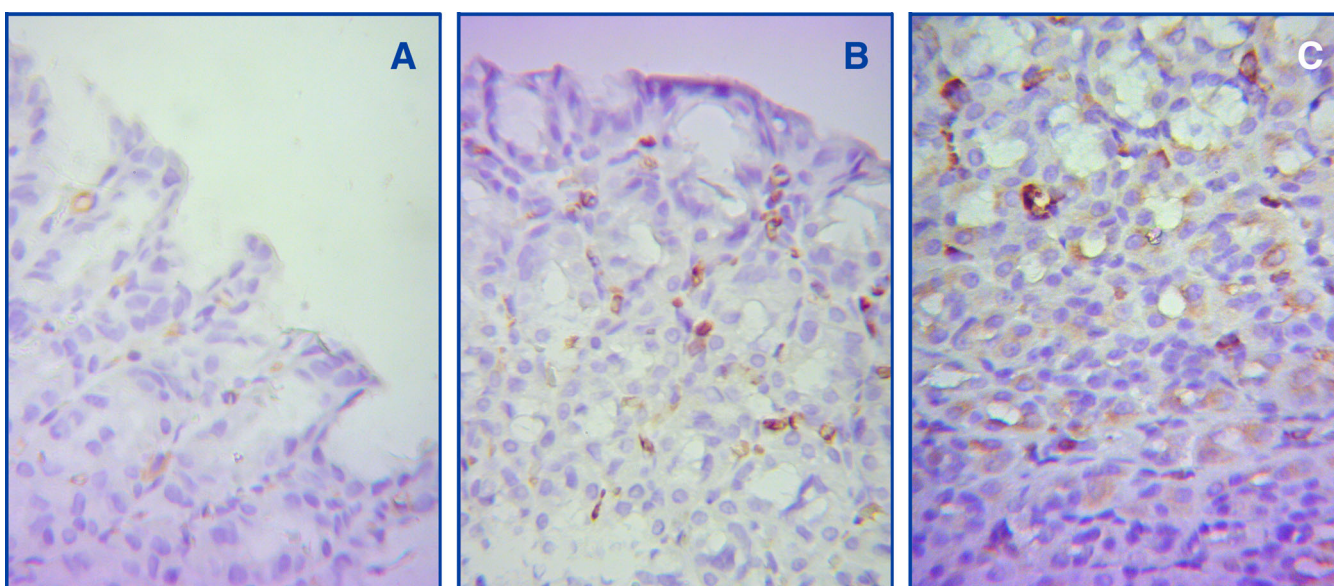


Fig. 2. Effect of melatonin on MDA levels in gastric mucosa after burns. Results are given as mean + SEM. * $p < 0.05$ for control animals; • $p < 0.05$ for burned, non-treated rats. C, Controls; B, burned rats; B + M, burned rats, treated with melatonin.

Fig. 3. Immunohistochemistry detection for heme–oxygenase-1 (HO-1) in gastric mucosa after burns. Controls (A); burned rats (B); burned rats, treated with melatonin (C). (Original magnification, x400).



cells, the production of pro-inflammatory cytokines and acute stress proteins, which may also contribute to the restriction of burn-induced tissue-oxidative damage, including that of the gastric mucosa [17, 12].

Melatonin prevents oxidative stress induced by ischemia / reperfusion (I/R) in gastric mucosa [18]. The protective effect of melatonin against gastric mucosal -oxidative damage is associated with the restriction of tissue lipid peroxidation and glutathione depletion after burns [12]. Moreover, melatonin acts to stabilize cell membranes, thereby making them more resistant to oxidative attacks [19]. Melatonin can protect against free-radical damage throughout the cell and limits membrane lipid peroxidation and proteins in the cytosol and oxidation of DNA in the nucleus [20].

Oxidative stress could be counterbalanced by induction of ROS detoxifying enzymes such as HO-1, SOD, glutathione S-transferase (GTS) [5, 21]. Because HO-1 is induced by oxidative stress, it could be speculated that the increased HO-1 expression in gastric mucosa is likely related to overproduction of free radicals after burns. A growing body of evidence indicates that HO-1 activation may play an important protective role in acute gastric and colonic damages. Induction of HO-1 protein has been reported to protect against a variety of stress conditions such as ischemia reperfusion, ethanol and NSAID [22, 23, 24].

Our data show that melatonin augments the increased HO-1 expression in burned rats. Both endogenous HO-1 and melatonin-induced HO-1 are responsible for degrading the

prooxidative heme and produce equimolar quantities of biliverdin, carbon oxide (CO) and free iron [5, 6]. Biliverdin is subsequently converted to endogenous antioxidative bilirubin via the action of biliverdin reductase. Free iron is promptly sequestered into ferritin, resulting in lowering the prooxidant state of the cell. CO improves the microcirculation by vasodilation and inhibition of platelet aggregation [5]. Ryter et al. demonstrate that CO can inhibit the production of proinflammatory cytokines [tumor necrosis factor (TNF)- α , interleukin (IL)-1 β , and macrophage inflammatory protein-1 β] and stimulate the synthesis of the antiinflammatory cytokine IL-10. CO has antiapoptotic effect [5]. Therefore, HO-1 up-regulation by melatonin may provide cytoprotection against oxidative injury, gastric mucosal injury and apoptosis [25, 26]. Other studies also suggest that HO-1 metabolites also show protective effects against the gastrointestinal lesions [22, 23, 24].

Both endogenous HO-1 and drug (zinc-L-carnosine)-induced HO-1 may protect against gastrointestinal injury [27]. Melatonin up-regulates HO-1 and protects against IR liver injury [28].

CONCLUSION

Melatonin increases HO-1 activity acting as a natural inducer antioxidant protection and protects gastric mucosa against oxidative injury after thermal trauma. This is the first report showing the protective role of HO-1 against burn-induced gastric mucosal lesions.

REFERENCES:

1. Pruitt BA Jr, Goodwin CW Jr. Stress ulcer disease in the burned patient. *J World Surg.* 1981 Mar;5(2): 209–222. [[CrossRef](#)]
2. Cakir B, Cevik H, Contuk G, Ercan F, Ekþioðlu-Demiralp E, Yeþen BC. Leptin ameliorates burn-induced multiple organ damage and modulates postburn immune response in rats. *Regul Pept.* 2005 Feb 15;125(1-3):135-44. [[PubMed](#)] [[CrossRef](#)]
3. Brzozowski T, Konturek PC, Drozdowicz D, Konturek SJ, Zayachivska O, Pajdo R, et al. Grapefruit-seed extract attenuates ethanol- and stress-induced gastric lesions via activation of prostaglandin, nitric oxide and sensory nerve pathways. *World J Gastroenterol.* 2005 Nov 7;11(41): 6450-8. [[PubMed](#)]
4. Magierowski M, Jasnos K, Sliwowski Z, Surmiak M, Krzysiek-Maczka G, Ptak-Belowska A, et al. Exogenous asymmetric dimethylarginine (ADMA) in pathogenesis of ischemia-reperfusion-induced gastric lesions: interaction with protective nitric oxide (NO) and calcitonin gene-related peptide (CGRP). *Int J Mol Sci.* 2014 Mar 20;15(3):4946-64. [[CrossRef](#)] [[PMC](#)].
5. Ryter SW, Alam J, Choi AM. Heme oxygenase-1/carbon monoxide: from basic science to therapeutic applications. *Physiol Rev.* 2006 Apr;86(2): 583-650. [[PubMed](#)] [[CrossRef](#)]
6. Morse D, Choi AM. Heme oxygenase-1: the “emerging molecule” has arrived. *Am J Respir Cell Mol Biol.* 2002 Jul;27(1):8-16. [[PubMed](#)] [[CrossRef](#)]
7. Konturek PC, Celinski K, Slomka M, Cichoz-Lach H, Burnat G, Naegel A, et al. Melatonin and its precursor L-tryptophan prevent acute gastric mucosal damage induced by aspirin in humans. *J Physiol Pharmacol.* 2008 Aug;59 Suppl 2:67-75. [[PubMed](#)]
8. Bandyopadhyay D, Ghosh G, Bandyopadhyay A, Reiter RJ. Melatonin protects against piroxicam-induced gastric ulceration. *J Pineal Res.* 2004 Apr;36(3):195-203. [[PubMed](#)] [[CrossRef](#)]
9. Bandyopadhyay D, Bandyopadhyay A, Das PK, Reiter RJ. Melatonin protects against gastric ulceration and increases the efficacy of ranitidine and omeprazole in reducing gastric damage. *J Pineal Res.* 2002 Aug; 33(1):1-7. [[PubMed](#)] [[CrossRef](#)]
10. Kwon KJ, Kim JN, Kim MK, Lee J, Ignarro LJ, Kim HJ, et al. Melatonin synergistically increases resveratrol-induced heme oxygenase-1 expression through the inhibition of ubiquitin-dependent proteasome pathway: a possible role in neuroprotection. *J Pineal Res.* 2011 Mar;50(2):110-23. [[PubMed](#)] [[CrossRef](#)]
11. Porter NA, Nixon JR, Isaac R. Cyclic peroxidase and thiobarbituric assay. *Biochim Biophys Acta.* 1976 Sep 27;441(3):596-599. [[PubMed](#)]
12. Sener G, Sehirli AO, Satiroðlu H, Keyer-Uysal M, Yeþen BC. Melatonin improves oxidative organ damage in a rat model of thermal injury. *Burns.* 2002 Aug;28(5):419-25. [[PubMed](#)]

[CrossRef]

13. Gurbuz V, Corak A, Yegen BC, Kurtel H, Alican I. Oxidative organ damage in a rat model of thermal injury: the effect of cyclosporin A. *Burns*. 1997 Feb;23(1):37-42. [PubMed] [CrossRef]

14. Hatherill JR, Till GO, Bruner LH, Ward PA. Thermal injury, intravascular hemolysis, and toxic oxygen products. *J Clin Invest*. 1986 Sep; 78(3):629-36. [PubMed] [CrossRef]

15. Pereira CT, Jeschke MG, Herndon DN. Beta-blockade in burns. *Novartis Found Symp*. 2007; 280:238-48; discussion 248-51. [PubMed]

16. Bindu S, Pal C, Dey S, Goyal M, Alam A, Iqbal MS, et al. Translocation of heme oxygenase-1 to mitochondria is a novel cytoprotective mechanism against non-steroidal anti-inflammatory drug-induced mitochondrial oxidative stress, apoptosis, and gastric mucosal injury. *J Biol Chem*. 2011 Nov 11;286(45):39387-402. [PubMed] [CrossRef]

17. Pandi-Perumal SR, Srinivasan V, Maestroni GJ, Cardinali DP, Poeggeler B, Hardeland R. Melatonin: Nature's most versatile biological signal? *FEBS J*. 2006 Jul;273(13):2813-38. [PubMed] [CrossRef]

18. Konturek PC, Konturek SJ, Majka J, Zembala M, Hahn EG. Melatonin affords protection against gastric lesions induced by ischemia-reperfusion possibly due to its antioxidant and mucosal microcirculatory effects. *Eur J Pharmacol*. 1997 Mar

12;322(1):73-7. [PubMed] [CrossRef]

19. García JJ, Reiter RJ, Guerrero JM, Escames G, Yu BP, Oh CS, et al. Melatonin prevents changes in mitochondrial membrane fluidity during induced lipid peroxidation. *FEBS Lett*. 1997 May 26;408(3):297-300. [PubMed] [CrossRef]

20. López-Burillo S, Tan DX, Mayo JC, Sainz RM, Manchester LC, Reiter RJ. Melatonin, xanthurenic acid, resveratrol, EGCG, vitamin C and alpha-lipoic acid differentially reduce oxidative DNA damage induced by Fenton reagents: a study of their individual and synergistic actions. *J Pineal Res*. 2003 May;34(4):269-77. [PubMed] [CrossRef]

21. Spanier G, Xu H, Xia N, Tobias S, Deng S, Wojnowski L, et al. Resveratrol reduces endothelial oxidative stress by modulating the gene expression of superoxide dismutase 1 (SOD1), glutathione peroxidase 1 (GPx1) and NADPH oxidase subunit (Nox4). *J Physiol Pharmacol*. 2009 Oct;60 Suppl 4:111-6. [PubMed]

22. Attuwaybi BO, Kozar RA, Moore-Olufemi SD, Sato N, Hassoun HT, Weisbrodt NW, et al. Heme oxygenase-1 induction by hemin protects against gut ischemia/reperfusion injury. *J Surg Res*. 2004 May 1;118(1):53-7. [PubMed] [CrossRef]

23. Gomes AS, Gadelha GG, Lima SJ, Garcia JA, Medeiros JV, Havt A, et al. Gastroprotective effect of heme-oxygenase 1/biliverdin/CO pathway in ethanol-induced gastric damage in

mice. *Eur J Pharmacol*. 2010 Sep 10; 642(1-3):140-5. [PubMed] [CrossRef]

24. Higuchi K, Yoda Y, Amagase K, Kato S, Tokioka S, Murano M, et al. Prevention of NSAID-Induced Small Intestinal Mucosal Injury: Prophylactic Potential of Lansoprazole. *J Clin Biochem Nutr*. 2009 Sep;45(2):125-30. Epub 2009 Aug 28. [PubMed] [CrossRef]

25. Choi KM, Gibbons SJ, Nguyen TV, Stoltz GJ, Lurken MS, Ordog T, et al. Heme oxygenase-1 protects interstitial cells of Cajal from oxidative stress and reverses diabetic gastroparesis. *Gastroenterology*. 2008 Dec;135(6):2055-64, 2064.e1-2. [PubMed] [CrossRef]

26. Takagi T, Naito Y, Yoshikawa T. The expression of heme oxygenase-1 induced by lansoprazole. *J Clin Biochem Nutr*. 2009 Jul;45(1):9-13. [PubMed] [CrossRef]

27. Ueda K, Ueyama T, Oka M, Ito T, Tsuruo Y, Ichinose M. Polaprezinc (Zinc L-carnosine) is a potent inducer of anti-oxidative stress enzyme, heme oxygenase (HO)-1 - a new mechanism of gastric mucosal protection. *J Pharmacol Sci*. 2009 Jul;110(3):285-94. Epub 2009 Jun 19. [PubMed] [CrossRef]

28. Kang JW, Lee SM. Melatonin inhibits type 1 interferon signaling of toll-like receptor 4 via heme oxygenase-1 induction in hepatic ischemia/reperfusion. *J Pineal Res*. 2012 Aug;53(1):67-76. [CrossRef]

Please cite this article as: Hristova M, Bekyarova G, Tzaneva M. HEME OXYGENASE-1 UPREGULATED BY MELATONIN: POTENTIAL PROTECTION AGAINST BURN-INDUCED OXIDATIVE GASTRIC MUCOSAL INJURY. *J of IMAB*. 2015 Apr-Jun;21(2):779-783. DOI: <http://dx.doi.org/10.5272/jimab.2015212.779>

Received: 25/02/2015; Published online: 22/05/2015



Address for correspondence:

Minka Hristova,
Divison of Pathophysiology, Medical University-Varna;
55 Marin Drinov Str., Varna 9002, Bulgaria;
E-mail: hristova_minka@abv.bg