



## REGISTRATION OF INTERNAL MORPHOLOGICAL CHARACTERISTICS OF THE TOOTH USING DENTAL PHOTOGRAPHY

Todor Ts. Uzunov<sup>1</sup>, Dimitar Kosturkov<sup>2</sup>, Tsonko Uzunov<sup>3</sup>, Dimitar Filchev<sup>1</sup>, Boiko Bonev<sup>4</sup>, Andon Filchev<sup>1</sup>.

1) Department of Prosthetic dentistry, 2) Dentist in private practice, 3) Department of Conservative dentistry, 4) Department of Social medicine and public dental health; Dental photography workshop, Faculty of Dental Medicine, Medical University - Sofia, Bulgaria.

### SUMMARY:

**Purpose:** Dental photography plays important role in the transfer of information between dentists as well as in communication between them and the dental technicians. It is very important to take precise photos of external and internal morphological characteristics of the teeth and there exist different methods for that.

The aim is to establish a protocol for registration of internal morphological characteristics of teeth by digital dental photography.

**Material and methods:** For the accomplishment of the aim 60 intact frontal teeth of 30 patients aged between 18 and 20 years were photographed.

The following basic and additional devices for dental photography were used:

1. Digital SLR (DSLR):
  - Body - Nikon D90
  - Lens - Nikon AF-S Micro Nikkor 105 f / 2.8G VR
  - Flash - Nikon SB-R-200 Speedlight remote kit R1
2. Lingual contraster
3. Reflective disk with silver surface

Lingual contraster was placed behind the respective tooth when taking photos. Light reflector was placed sideways near patient's head. The head of the flash that is near to the reflector was oriented towards it. The other flash on the opposite side, activated at a minimum power, was directed to the tooth row.

**Results:** Internal characteristics of the tooth - enamel cracks, translucency, transparency, opacity and opalescence were easily and predictably recorded by the described methodology.

**Conclusions:** The method suggested by us can be successfully used for recording the internal morphological characteristics of the tooth.

**Key words:** Dental photography, internal morphological characteristics of teeth

### INTRODUCTION:

With the development of modern technologies, methods for registration of patient's condition significantly increased. Dental photography and especially digital dental photography provides an excellent opportunity for recording

and storing data of the clinical condition of the patient. Photography is a powerful tool by which dentists can forward the information that cannot be described with words [1].

Clinical dental photography allows dentists to analyze the patient's condition carefully and to plan their treatment, without the necessity of patient's physical presence. Information obtained from clinical photographs is of significant importance in establishing the best treatment plan [2].

Most of the modern computer dental programs allow photographs of the patient to be kept in their file. Thus, the extraction of information about the patient is facilitated [2]. Some of these programs have options for photo processing and preparation of preliminary vision for the outcome of a treatment.

Dental photography plays very important role in the exchange of information from the main dentist to the patient, to another dental specialist or dental technician. In the field of prosthetic dentistry it is extremely important that all clinical information is submitted absolutely right to the dental laboratory where all the external and internal characteristics of teeth - enamel cracks, translucency, transparency, opalescence, opacity, mamelons, should be recreated when making prosthetic constructions [3, 4, 5].

Ring, twin flash or external flash can be used to capture the external characteristics of the teeth. Most authors suggest using lingual contraster, and some - making a black and white copy of the image in order to create a real topographic map of teeth's characteristics [3, 4, 6, 7].

The literature describes various methods for recording the internal characteristics of the tooth [3, 4, 6, 7]. The most popular is the technique with camera positioned at 60° angle above the teeth and the image is underexposed in order to register translucency [7]. This projection leads to shortening of the teeth in the photography, which may mislead the dental technician when mapping the internal characteristics of teeth.

Another alternative is to use two flashes with a different power directed at different angles to the tooth surface, but the correct positioning can be time consuming. This technique can be modified by placing a diffuser of a different kind on the flashes [3, 4, 6].

Some authors describe a method for capturing the internal characteristics of the tooth using special polarizing

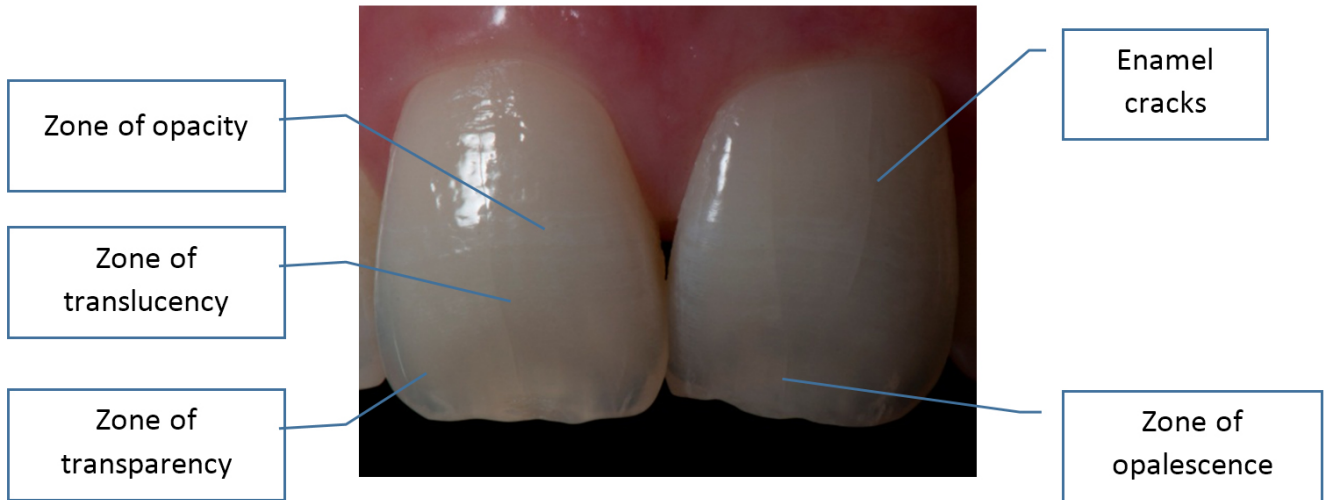filter which passes only light polarized at a certain angle that removes unwanted reflections [8, 9].

The aim of this study is to create an original protocol for recording internal morphological characteristics of tooth by means of digital dental photography.

**MATERIAL AND METHODS**

To achieve the aim we photographed maxillary central incisors of 30 patients aged from 18 to 20 years with an intact dentition. Clearly notable and clinically established enamel cracks, areas of translucency, transparency, opacity and opalescence of 60 teeth were recorded (fig. 1).

**Fig. 1.** Internal morphological characteristics of the tooth



For registration of internal morphological characteristics of the teeth, the following equipment and accessories are used:

- 1. Basic tools - DSLR (Figure 2):
  - 1.1. Body - Nikon D90
  - 1.2. Lens - Nikon AF-S Micro Nikkor 105 f / 2.8G VR
  - 1.3. Flash - Nikon SB-R-200 Speed light remote kit R1

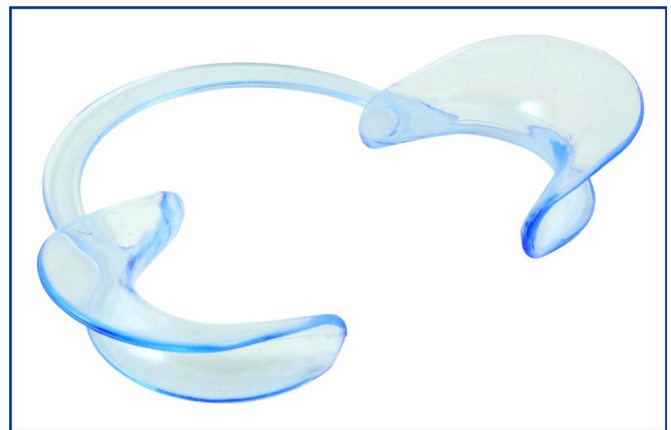2. Additional resources:

- 2.1. Double cheek retractor (Fig. 3)
- 2.2. Lingual contrastor (Fig. 4)
- 2.3. Reflective disc with silver surface (Fig. 5)
- 2.4. External flash (Fig. 6)

**Fig. 2.** DSLR



**Fig.3.** Double cheek Retractor



**Fig. 4.** Lingual contrastor



**Fig. 5.** Reflective disk



**Fig. 6.** External flash



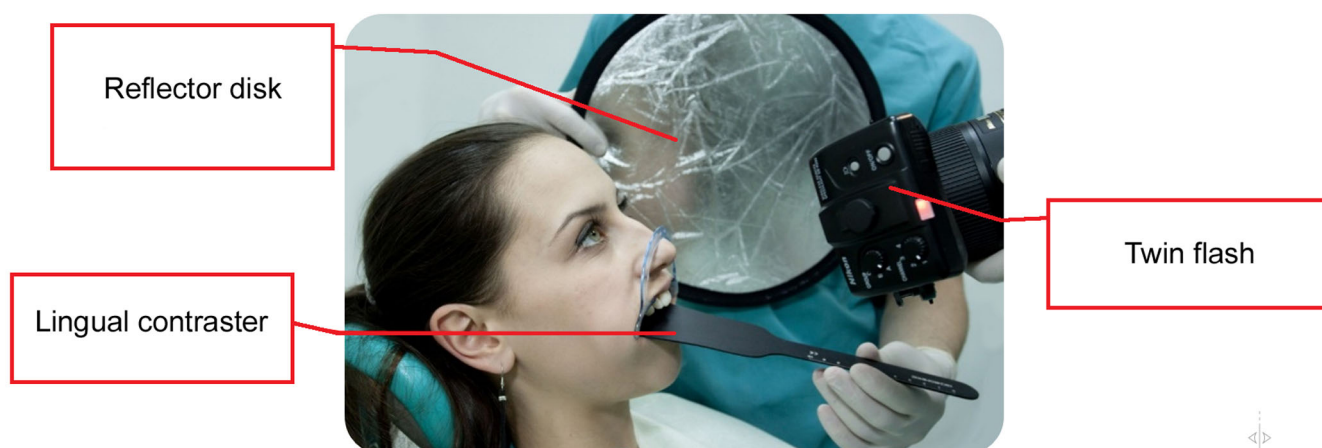
For registration of internal morphological characteristics of teeth the following original methodology was used (Fig. 7):

1. Positioning of the patient in dental chair
2. Setting up the camera with the following parameters:
  - Aperture -  $F = 40$  (between 36-45 or maximum closed)
  - Speed - between  $1 / 100s$  and  $1 / 200s$
  - ISO - 100 (minimum)
  - Intensity of flashes - full power on the side of the tooth being photographed, minimum power (or close to the minimum -  $1/128, 1/64$ ) on the opposite side.
3. Placing the cheek retractor on patient's mouth
4. Drying the teeth in order to reduce glare and to

record easier the internal morphological characteristics

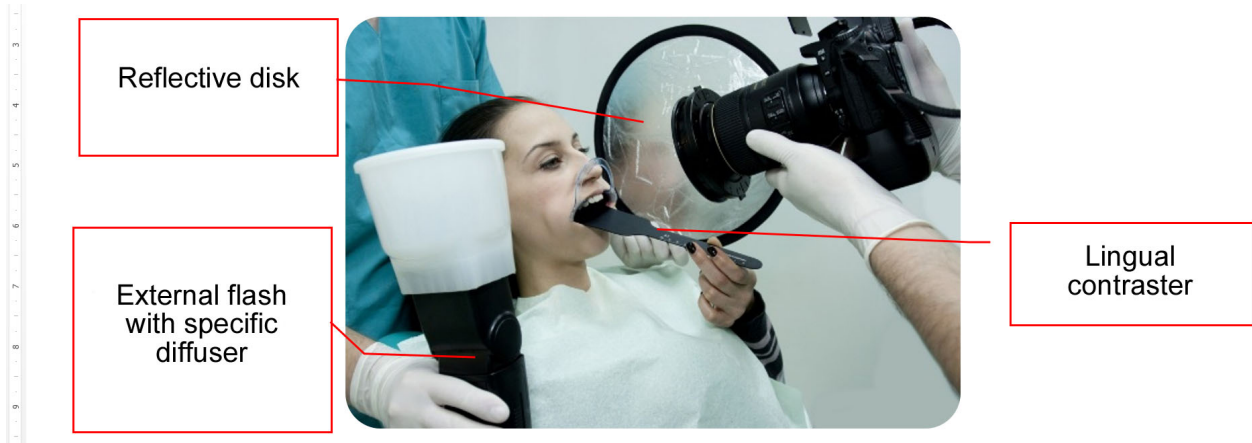
5. Placing the lingual contraster behind the tooth row
6. Positioning of the camera to capture the tooth row. The front of the lens must be parallel to the frontal plane (imaginary extension of the lens perpendicular to the tooth surface)
7. Positioning of reflective disk with a silver surface on the side of tooth being photographed near the patient's head
8. Positioning of the flash heads:
  - The head of the flash on the side of the reflector is directed to it (set to maximum intensity)
  - The head of the flash on the opposite side is directed to the tooth row (set to minimum intensity)

**Fig. 7.** A method for capturing internal morphological characteristics of the teeth using macro twin flash and reflective disk



We applied an alternative technique in which as a source of light external flash with a specific type of diffuser was used instead of a macro flash. Any other conditions were equal (Fig. 8)

**Fig. 8.** A method for capturing the internal morphological characteristics of teeth with external flash, specific diffuser and reflective disk



**RESULTS**

Results obtained from the research are as follows:  
(Table. 1 and Fig. 9):

**Table 1.** Results

Teeth(60)	Twin flash + reflective disk		External flash + reflective disk	
	number	%	number	%
Teeth with enamel cracks	60	100 %	60	100 %
Teeth with translucency	59	98,3 %	57	95 %
Teeth with transparency	60	100 %	59	98,3 %
Teeth with opacity	60	100 %	60	100 %
Teeth with opalescence	57	95 %	58	96,7 %

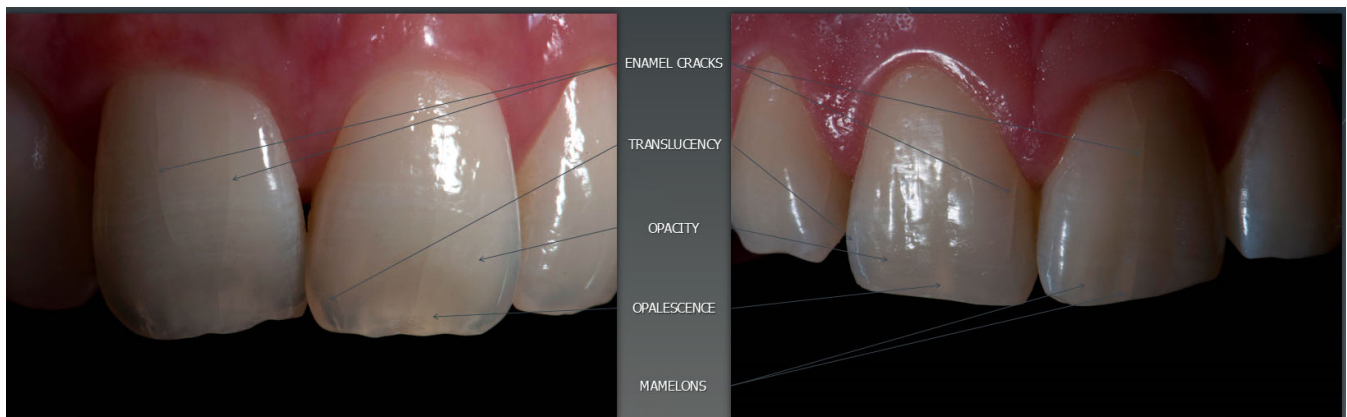
Among more than 95% of the upper central incisors, the internal characteristics of the teeth - enamel cracks, translucency, transparency, opacity and opalescence are successfully recorded using both original photographic techniques.

Clinically detectable enamel cracks and areas of opacity were recorded in all 60 examined teeth (100%) with the two photographic techniques. Clinically visible areas of translucency were captured using a macro twin flash in 59 teeth (98.3%) and in 57 teeth (95%) by the method with external flash. Clinical areas that appear transparent were

registered in all 60 teeth using the first technique and in 59 teeth (98.3%) with the second technique. Clinically identifiable zones of opalescence were captured in 57 of studied teeth (95%) and 58 teeth (96.7%), respectively with the first and second photographic methods.

As a result of the photographic techniques used by us, an image of the tooth with high sharpness and contrast is obtained. Due to the asymmetry of the light sources on the left and the right side, the peripheral zone of the image near to the registered tooth is underexposed (Fig. 9).

**Fig. 9.** Registered internal morphological characteristics of teeth by photographic techniques proposed by us.



## DISCUSSION

The survey results showed that the two suggested by us methods offer predictable and repeatable results when taking photos of internal morphological characteristics of teeth. Among almost all examined teeth (over 95%) clinically visible areas of translucency, transparency, opalescence, opacity, enamel cracks, mamelons and opaque stripes of incisal edges were digitally registered. Usage of reflective disk leads to getting a soft, diffused light that falls on the tooth surface and eliminates all unwanted glare. Introduction of lingual contraster behind examined teeth was dictated by the need to eliminate reflections from the mucosa. Thus, as Loiacono pointed [6], can be blocked the red shades that come out from the soft tissues. It is important because they reach the enamel and mix with the blue shades (enamel) breaking the effects of opalescence and translucency.

Unlike the suggested by Ratcliff [7] method to register the internal characteristics by positioning the lens at an angle of 60 ° above the occlusal plane, we use techniques that do not lead to shortening of the projection of digital image. Therefore, communication with dental laboratory is facilitated and allows the dental technician to

map accurately all the features of the tooth's surface.

As a result of the photographic methods used by us, there are some underexposed parts in the image, but they are only in the peripheral zone in the image near the studied tooth. In contrast, in the cited by Benson [8] technique when using a polarizing filter, problems related to the exposure of the entire image can appear. On the other hand, there is a lack of information in the image about the external characteristics of the tooth, which information presents partially in pictures taken with the techniques invented by us.

In proposed by Ahmad [3] technique two different flashes set at a different power and pointed at a different angle to the tooth surface are used. In our opinion, proper positioning and programming of the flashes takes valuable clinical time and seriously hampers the dentist. In contrast to it, the method described by us requires less time and is easier to be understood and performed.

## CONCLUSIONS

The methodology suggested by us may be used as the method of choice for recording the internal morphological characteristics of the tooth when performing the standard photographic protocol in daily dental practice.

---

## REFERENCES:

1. Bennet A. Photography in practice: An essential tool. *Dental Nursing*. 2008 Jan;4(1):16-20
2. Rao SA, Singh N, Kumar R, Thomas AM. More than meets the eye: digital fraud in dentistry. *J Indian Soc Pedod Prev Dent*. 2010 Oct-Dec;28(4):241-4. [PubMed] [CrossRef]
3. Ahmad I. Digital dental photography. Part 8: intra-oral set-ups. *Brit Dent J*. 2009 Aug;207(4):151-157. [PubMed] [CrossRef]
4. Ratcliff S, Bush DE, Fondriest JF. Chapter 4. Digital dental photography. A clinician's guide. *L. D. Pankey Dental Foundation, Inc*. 2004,
5. Ahmad I. Digital dental photography. Part 1: an overview. *Brit Dent J*. 2009 Apr;206(8):403-407. [PubMed] [CrossRef]
6. Loiacono P, Pascoletti L. The orthography of Images. Photography in Dentistry. Theory and Techniques in Modern Documentation. (Hardback). Quintessenza, Italy. 2012, Chapter 7: 182-194.
7. Ratcliff S, Bush DE, Fondriest JF. Chapter 5: Photography strategies in shade matching. Digital dental photography. A clinician's guide. *L. D. Pankey Dental Foundation, Inc*. 2004.
8. Benson PE, Shah AA, Willmot DR. Polarized Versus Nonpolarized Digital Images for the Measurement of Demineralization Surrounding Orthodontic Brackets. *Angle Orthodontist*. 2008 Mar;78(2):288-293. [CrossRef]
9. Payet C. Shade Matching Made Easy. Oct 29, 2012. Available from: <http://www.dentaldigitalphotography.com/2012/10/29/dental-shade-matching-polar-eyes-filter/>

*Please cite this article as:* Uzunov TT, Kosturkov D, Uzunov T, Filchev D, Bonev B, Filchev A. REGISTRATION OF INTERNAL MORPHOLOGICAL CHARACTERISTICS OF THE TOOTH USING DENTAL PHOTOGRAPHY. *J of IMAB*. 2015 Jan-Mar;21(1):677-681. DOI: <http://dx.doi.org/10.5272/jimab.2015211.677>

Received: 29/10/2014; Published online: 28/01/2015



### Address for correspondence:

D-r Todor Uzunov, Department of Prosthetic dentistry, Faculty of Dental Medicine, Medical University Sofia,  
1, St. Georgi Sofiyski blvd., 1431 Sofia, Bulgaria.  
Mobile: +359/889428273  
E-mail: [uzunov\\_todor@abv.bg](mailto:uzunov_todor@abv.bg),