

Closure of Midline Diastema by Direct Composite Resin Build-Up Using a Customized Matrix Technique - A Case Report

Syed Mukhtar-Un-Nisar Andrabi¹, Afaf Zia², Ashok Kumar³, Sharique Alam⁴

^{1,2,4}Assistant Professor, ³Professor & Chairman, Department of Conservative Dentistry & Endodontics, Dr. Z.A. Dental College, A.M.U Aligarh

***Corresponding Author:**

E-mail: mukhtarandrabi@gmail.com

Abstract:

Correction of midline diastemas without much preparation of the teeth is one of the challenges in clinical esthetic dentistry. While excellent aesthetics are possible with indirect restorations, there may be unnecessary tooth structure removed in order to achieve the desired results. This may affect the long term success of the restoration, when dealing with younger patients. Whenever possible, tooth material augmentation versus tooth material amputation allows for a more conservative treatment option. Many innovative therapies have been used, varying from restorative procedures to surgery (frenectomies) and orthodontics. The size of the diastema is an important determinant when selecting the mode of treatment as well as the material for correction. When a larger space closure is needed, orthodontics may be indicated to allow for a more aesthetic outcome. When a small diastema with teeth in proper orthodontic alignment, no preparation of the tooth structure is necessary and direct composite bonding may yield the desired result. The following case report shows a restorative protocol using direct composite resin build up when addressing the midline diastema.

Keywords: *Diastema closure, Direct resin, Customized matrix*

Introduction:

The midline diastema is a space between the maxillary central incisors.¹ The incidence of diastemas varies greatly with age and race. The space can be a normal growth characteristic during the primary and mixed dentition and generally is closed by the time the maxillary canines erupt.² In adults, the most common factors in the development of diastemas are tooth-size discrepancies and excessive vertical overlap of the incisors. Other less frequent, but important, contributing factors are Incisor mesiodistal angulations, generalized spacing, labiolingual incisor inclination, frenums and pathological conditions.³

Maxillary midline diastemas are considered as esthetic problems by majority of the patients and thus are an esthetic liability just like crowding or protrusion of incisors. A study evaluating the influence of incisal malocclusion on social attractiveness of young adults in Finland found that patients with a broad midline diastema were perceived as being less socially successful and of lower intelligence.⁴

Diastemas can be treated in a multitude of ways including orthodontic closure, restorative therapy, surgical correction or multidisciplinary approach depending upon the particular case and the etiology of diastema.^{5,6} A carefully developed differential diagnoses allows the practitioner to choose the most effective treatment plan. Diastemas based on tooth-size discrepancy are most amenable to restorative solutions.^{7,8} The restorative closure of diastemas can be achieved by using any of the

techniques mentioned; direct composite veneers, indirect composite veneers, porcelain laminate veneers, all ceramic crowns, metal ceramic crowns and composite crowns.⁹

The increased patient demand for minimally invasive aesthetic procedures and the improved physical properties of current composite materials has resulted in the extensive utilization of direct bonding of composite resin to anterior teeth.¹⁰ Contemporary composite materials can be handled throughout the restorative process to achieve the desired morphology and color of the final restoration. Direct resin build up can be a worthy choice to treat diastemas based on tooth-size discrepancy. However, direct placement of composites for veneering is a laborious process particularly for multiple teeth. Simpler techniques using matrix have been advocated to make the procedure less technique sensitive. Use of matrix in placing composite simplifies the chair side treatment procedure. This paper proposes a new simplified direct composite veneering using a modified matrix to achieve diastema closure and desirable esthetics in single visit.

Case Presentation:

A 20 year old female patient reported to the department of conservative dentistry and endodontics, Dr. Z.A Dental College, A.M.U Aligarh, India with a chief complaint of midline spacing between her upper anterior teeth (fig.1a-b). The spacing was a social embarrassment to the patient, and was affecting her self-confidence.

On examination a space of around 1.5 mm existed between the maxillary central incisors and also there was spacing between the right central and lateral incisor and furthermore all the upper incisors had relatively less mesiodistal width and improper contours. After the discussion of the condition with the patient the following treatment plan was formulated:

Closure of midline diastema and overall smile build up using a customized matrix technique.

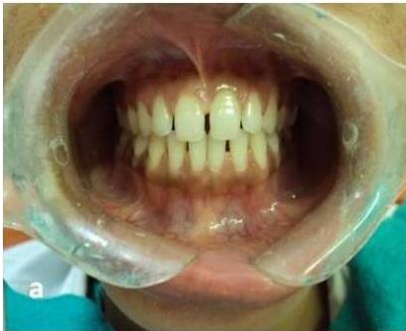

Fig - 1(a)

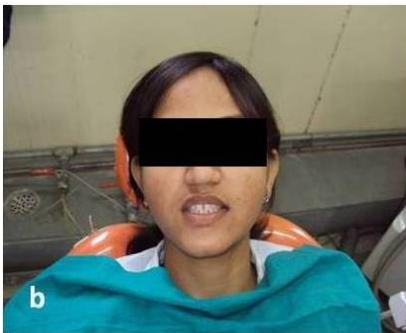

Fig - 1(b)

Fig.1: Pre-operative view a) intra oral b) frontal profile

Modified Matrix Fabrication:

Impressions were made and models prepared. A diagnostic wax up of the models was performed to modify and finish them to predictable esthetics for the patient (fig.2a-b). The waxed up modified models were then duplicated. The duplicated casts were then placed in a Biostar machine. The matrix material selected was copyplast 1 mm (Scheu Dental GmbH Am Burgberg 2058642 Iserlohn Germany). Copyplast is a low density polyethylene (PE-LD) biocompatible material available in 1mm and 1.5mm round and 0.5mm, 1mm, and 1.5mm square. Copyplast is ideal for fabricating a temporary matrix. The matrix was fabricated and trimmed to be used in the patient's mouth (fig.3a-b).

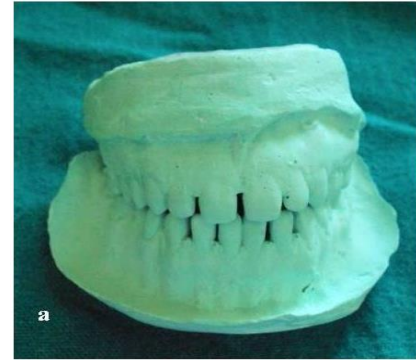

Fig - 2(a)

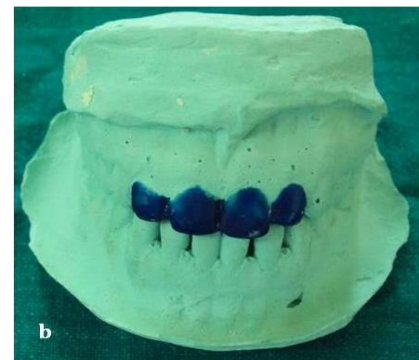


Fig - 2(b)

Fig.2: a) Pre-operative model b) Diagnostic wax up

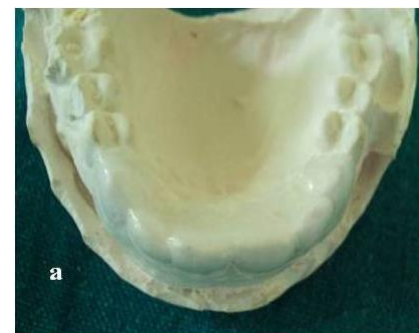

Fig - 3(a)

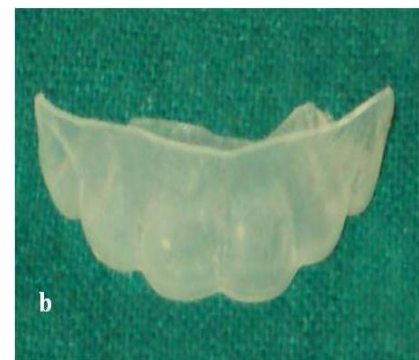


Fig - 3(b)

Fig.3: a-b Customized matrix fabrication

Restoration:

The teeth were restored with a nano-hybrid composite, Tetric N Ceram (Ivoclar Vivadent AG Schaan/Liechtenstein) by a three step etch rinse and bond technique.

Etching was done for 20 seconds with **N-Etch** (Ivoclar Vivadent AG Schaan/Liechtenstein), a phosphoric acid gel for enamel etching and dentin conditioning (fig.4a-b).

Bonding was done by **Tetric N-Bond** (Ivoclar Vivadent AG Schaan/Liechtenstein), a light-curing, single-component bonding agent for enamel and dentin bonding used in combination with the total-etch technique.

In the process of resin build up after etching and bonding, a light-curing, radiopaque nano-hybrid restorative composite (**Tetric N-Ceram**, Ivoclar Vivadent AG Schaan/Liechtenstein) was applied on the tooth surfaces and then the transparent custom matrix was placed. The curing was done with a light emitting diode (LED) curing unit (ART-L3 LED, Bonart Medical Technology, Inc. CA, USA) through the transparent matrix for 60 seconds for each tooth (fig.5a-b). After the curing was complete the matrix was removed and the extra flash was removed with fine-grit flame shaped diamonds and finishing carbide burs. The final finishing of the restorations was done by fine composite finishing discs (Shofu, Inc. Japan). The final restorations resulted in the diastema closure and as well as overall aesthetic improvement of the patient, both meeting the patient's expectations (fig.6a-b).

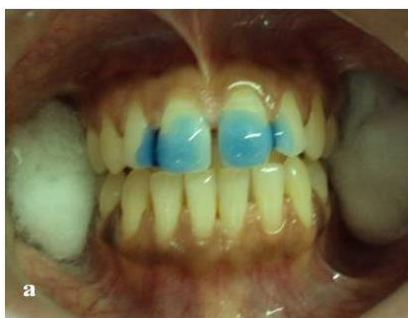

Fig. 4: (a)

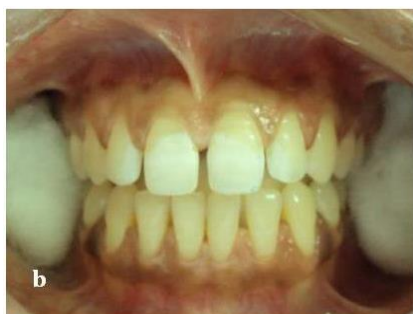

Fig. 4: (b)

Fig.4: (a-b) Etching of the tooth surfaces

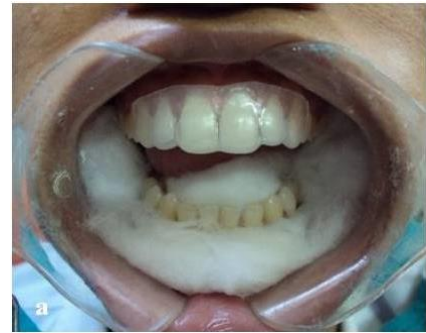

Fig. 5: (a)

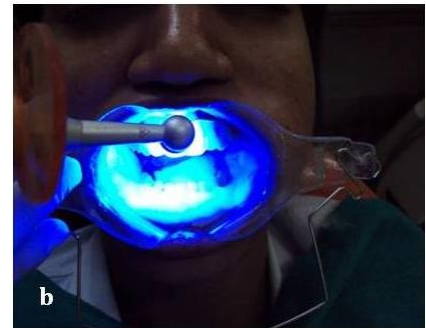

Fig. 5: (b)

Fig.5: (a-b) Composite build up with customized matrix in place

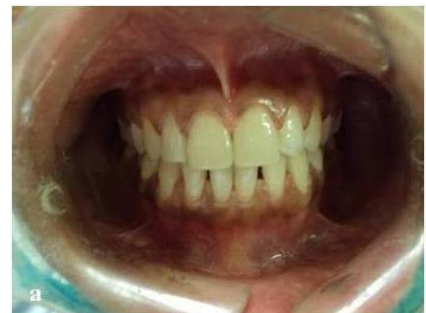

Fig. 6: (a)

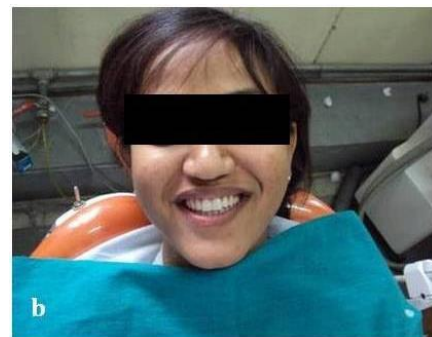

Fig. 6: (b)

Fig.:6(a-b) Final restoration after finishing a) intra oral view b) frontal profile view

Discussion:

With the current trend towards minimally invasive dentistry, direct composite veneering has provided clinician with added advantage of achieving predictable esthetic results with minimized trauma to the teeth.¹¹

The modern composite restorative materials are remarkable with their improved physical and esthetic properties, if manipulated properly they can be used to create good quality esthetic restorations with sufficient wear resistance providing satisfactory years of service. They are conservative esthetic options of restorative dentistry since minimal or no tooth preparation as compared to ceramics. Direct resin veneering can be done by hand sculpting or free hand bonding, but that is a cumbersome process, requiring a lot of effort, time and often it is not possible to veneer multiple teeth in the same appointment. To simplify composite placement –a customized matrix for individual patients can be made which is less technique sensitive and provides greater opportunity and freedom to deliver optimized aesthetic goals. The only limitation to the customized matrix technique can be the need for wax up of the models and then the accurate fabrication of the matrix. However, keeping in view the benefits of using a customized anatomical matrix for direct resin veneering this extra effort is worth. The advantage of using a laboratory-fabricated template is, of course, the freedom from having to sculpt perfect dental anatomy.¹² In the present case report the fabrication of the customised matrix helped to achieve optimal aesthetics in a single visit.

Conclusion:

Direct resin veneering can be a valuable treatment option in treatment of midline diastemas due to tooth size discrepancies. The utilization of a customized matrix can greatly improve the control of the operator over the fine reproduction of anatomic details and will result in easily achievable aesthetic restorations. Besides, this can be seen as an economic treatment option for aesthetic correction of midline diastemas.

References:

1. Baum AT: The midline diastema. J Oral Med 1966;21:30-39.
2. Broadbent BH: The face of the normal child (diagnosis, development). Angle Orthod 1937; 7:183-208.
3. Oesterle L.J; Shellhart W.C. Maxillary Midline Diastemas: a look at the causes. J Am Dent Assoc, 1999; 130:85-94.
4. Kerosuo H, Hausen H, Laine T, Shaw WC. The influence of incisal malocclusion on the social attractiveness of young adults in Finland. Eur J Orthod 1995;17:505-12.
5. Dlugokinski MD, Frazier KB, Goldstein RE: Restorative treatment of Diastema. In: Esthetic in Dentistry (Vol.2),RE Goldstein, VB Hoywood (Eds.); 2nd Edn.; BC Decker Inc. London, 2002;703-732.

6. Edwards JG. The diastema, the frenum, the frenectomy: a clinical study. Am J Orthod 1977;71(5):489-507.
7. Bolton WA. Clinical application of a tooth-size analysis. Am J Orthod 1962;61:504-29
8. Bolton WA. Disharmony in tooth size and its relation to the analysis and treatment of malocclusion. Angle Orthod 1958;28:113-30.
9. Bhoyar AG. Esthetic Closure of Diastema by Porcelain Laminate Veneers: A Case Report. People's Journal of Scientific Research 2011;4(1):47-50.
10. Dietschi D. Free-hand composite resin restorations: A key to anterior aesthetics. Pract Periodont Aesthet Dent 1995;7(7):15-25.
11. Lal SM, Jagadish S. Direct composite veneering technique producing a smile design with a customised matrix. J Conserv Dent 2006;9:87-92
12. Shuman IE, Goldstein MB. Anterior aesthetics using direct composite with a custom matrix guide. Dent Today. 2008;27:126-131.