

Treatment of Developing Skeletal Class iii Malocclusion, Using fr-iii Appliance: A Case Report

Saveen. N.S, Rosaline Tina Paul, Jerun Jose, Deepak. P.R, Drisya S, Lakshmanan L

Royal dental college. Palakkad

***Corresponding Author:**
Email: dr.saveen@gmail.com

Abstract:

Introduction: Dento-alveolar and skeletal effects of orthopedic treatment have always been the subject of controversial scientific discussions. The aim of this article is to describe and discuss a clinical case with skeletal Class III malocclusion treated with Frankel-III appliance in the following manner.

- 1) To cephalometrically evaluate the skeletal, dental and soft tissue changes following therapy with Frankel's function regulator -III (FR-III).
- 2) To evaluate arch width and apical base width changes with Frankel's function regulator -III (FR-III).

Conclusion: It was found that the FR-III appliance restricts mandibular growth and stimulates forward movement of maxilla.

Key words: Skeletal Class III, FR-III appliances, soft tissue profile, apical base width.

Introduction:

Class III malocclusion and anterior crossbites are common clinical problems, especially in patients of Asian ancestry. The etiology of Class III malocclusion could be either genetic or environmental. Studies on human inheritance and its role in Class III malocclusion support the belief that hereditary affects the growth and size of mandible. The most well-known example of Class III inheritance is the Hapsburg family which was described by McGuigan in 1966¹. Rakosi and Schilli¹ described some environmental influences, such as habits and mouth breathing, mandibular posture, functional mandibular shifts due to respiratory needs, tongue size being the etiology of Class III malocclusion. Proclination of mandibular incisors and retroclination of maxillary incisors can cause anterior posturing of mandible due to incisal interference and the condition is known as pseudo Class III. True Class III or skeletal Class III is either due to retrognathic maxilla, prognathic mandible or combination of both. There are various treatment modalities based on the cause of Class III malocclusion. eg: protraction headgear, FR-III appliance, reverse activator etc.

The FR-III appliance was developed by Professor Rolf Frankel, Zicavu, Germany in 1969. The FR-III appliance is indicated during the deciduous, mixed, and early permanent dentition to correct Class III malocclusion characterized by maxillary skeletal retrusion and not mandibular prognathism. The theoretical concept and clinical results following treatment have aroused considerable interest and controversy. According to Frankel², the vestibular shields and the upper labial pads function to counteract the forces of the surrounding muscles that restrict the forward maxillary skeletal

development and retrude maxillary tooth position. Frankel² has also stated that the vestibular shield stands away from the alveolar process of maxilla but fit closely in mandible, thus stimulating maxillary alveolar development and restricting mandibular alveolar development. Though the FR-III appliance corrects the Class III malocclusion, controversy exists as to its effectiveness in promoting maxillary growth and restricting mandibular growth. Even though various studies have shown changes in arch width with Frankel's function regulator -III therapy, very few researches were done in demonstrating changes in apical width.

Case report:

A 9 year old female patient in her prepubertal period reported with a retrognathic maxilla and orthognathic mandible. She was in the late mixed dentition period. It was decided to treat the patient with a FR-III appliance, which would restrict mandibular growth and enhance maxillary growth, at the same time the appliance would also bring about arch expansion, thus creating more space for the erupting permanent teeth and permit exfoliation of deciduous teeth.

Materials and methods:

Alginate impression with full sulcus poured in dental stone, lateral cephalograms in occlusion were taken as records.

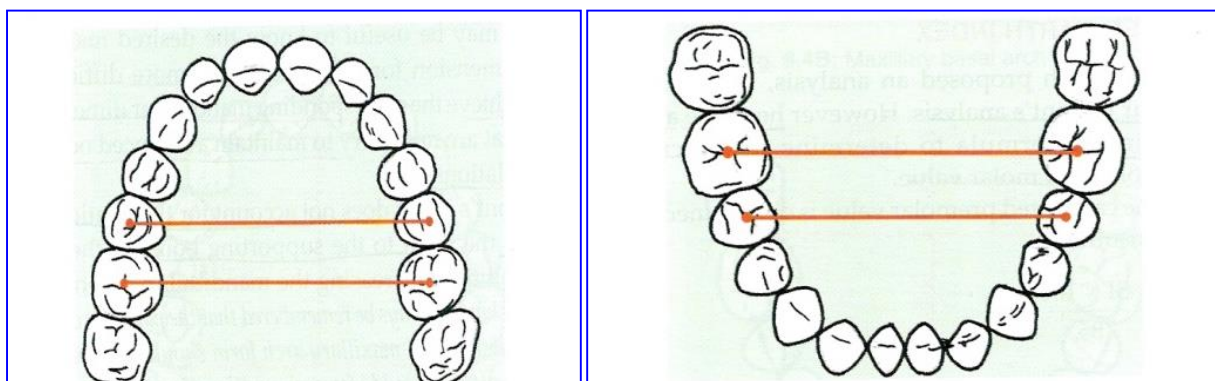
1) Cephalometric measurements: The pre and post lateral cephalograms were plotted using the Dolphin software (Dolphin Imaging version 11.7 Chatsworth, USA). The skeletal, dental and soft tissue measurement with composite Cephalometric

analysis was used to assess the treatment changes. The Cephalometric measurements that used in this study are given in table no: 1

Table No:1: Cephalometric Measurements

N0	MEASUREMENTS	MEAN	PRE-TREATMENT	POST TREATMENT	TREATMENT OUT COME
1	Point A to N [⊥]	0+/-2mm	-9.1mm	-6.3mm	2.8mm
2	SNA	82°	76.1°	80°	3.9°
3	SNB	80°	79°	80°	1°
4	ANB	2°	-2.9°	0°	2.9°
5	Co-Gn(Effective mandibular length)		104.5mm	110.5mm	6mm
6	Co-point A (Effective maxillary length)		77mm	81mm	4mm
7	ANS-Me(LAFH)		60.9mm	65.4mm	4.5mm
8	Wit's appraisal	BO 1mm Anterior to AO	-7mm	-3mm	4mm
9	FH-GoMe (Mandibular plane)	22+/-4°	33°	34°	1°
10	Pog-N [⊥]	0-4mm	10.9mm	10.2mm	-0.7mm
11	Pn line to ANS- PNS (Angle of inclination)	0+/-3.5°	3°	1.7°	-1.3°
12	Ptm Gn-Ba N [⊥] (Facial axis angle)	85°	83°	83°	0°
13	SGo-NMe (Anterior and posterior face height)	62-65%	62.04%	61.81%	0.23%
14	U incisor to SN	102°	121.9°	116°	-5.9°
15	L incisor to Go Gn	90°	89.9°	91.4°	1.5°
16	Ls-E line	4mm behind	4.5mm	3.8mm	-0.7mm
17	Li-E line	2mm behind	3.9mm	2.5mm	-1.4mm
18	Pog-Pog'(Chin thickness)	10-12mm	10mm	10mm	0mm
19	N'-Sn-Pog'(Soft tissue facial convexity angle)	Class-I 159° Class-II 163° Class-III 168°	Class-III 169°	Class-I 160°	-9°
20	N'-Pog to FH	90-92°	87°	88°	1°

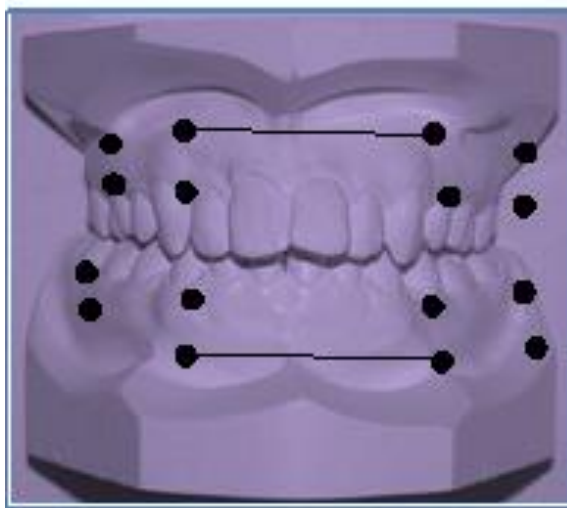
2) Measurement of arch width: All pre and post treatment study models were measured with modified dial calipers to an accuracy of 0.02mm. All measurements were remeasured manually by three operators to determine the magnitude of error. Changes in arch width would be measured between right and left primary or permanent canine, primary first molar or first premolars, primary second molar or second premolar.



2) Apical base

To examine whether the expected increase in arch width was bodily or tipping tooth movement, each tooth has measured in three regions:

- Occlusal values
- Gingival values
- Alveolar values



Occlusal values

For canines, premolars, primary first molar these values were recorded from the cusp tip of one tooth to its counterparts of the same arch. In the case of primary second molar and permanent first molar the values were recorded at the junction of the buccal developmental groove and the occlusal surface of the tooth³.

Gingival values

These values were recorded from a point located at a spot where a line from the occlusal point intersected the mesiodistal midpoint of the buccal cervical margin of the tooth to its counterpart in the same arch.

Alveolar values

These values were recorded from a point which was determined by extending the line joining the occlusal and gingival point to a spot on the alveolus 5 mm gingival to the cervical margin of the tooth to its counterpart in the same arch. If the permanent tooth had not erupted, occlusal or gingival values were not considered and they do not appear in the data. However, in such situations an alveolar measurement was made at the midpoint of the edentulous space which was 5mm gingival from a line joining the gingival margins of the teeth adjacent to the space.

The Frankel functional regulator (FR-III) used in this study was constructed according to the

description given by Rolf Frankel⁴. Bite registration was taken with the patient's mandible in the most comfortably retruded position with a vertical interocclusal clearance of 1-2 mm. The patient was instructed to wear the appliance full time.

Results:

After one year of full time wear of appliance, the following cephalometric changes were observed. SNA, SNB, ANB angle, effective mandibular length, effective maxillary length, lower anterior facial height, Wits appraisal, mandibular plane angle were increased. Facial axis angle remained the same. Angle of Inclination, lower anterior and posterior height ratio, upper incisor to SN, lower incisor to Go- Gn, upper lip to E line, lower lip to E line, were decreased. (Table no: 1)

Mean maxillary mandibular width changes for all 3 points on pre and post treatment study models are presented in table 2, 3A and, 3B, indicating an expansion of maxillary arch occurred with FR-III therapy. While the maxillary occlusal and gingival values showed significant changes, maxillary alveolar and almost all mandibular values showed no significant occlusal expansion because the maxillary posterior teeth erupt normally in the vertical and lateral direction, which in turn was influenced by the vestibular shields which kept away the buccal musculature from the dentition. Molar teeth exhibited bodily movement in buccal direction. This was due to the periosteal pull provoked by the vestibular fold.

Table no 2: Arch width changes

	Intermolar width		
	pre	Post	Treatment outcome
Maxilla	52mm	53mm	1mm
Mandible	45mm	46mm	1mm

Table no 3(A): Apical base width changes-Maxilla

	Maxilla					
	Inter canine width(c)			Inter molar width(6)		
	Pre treatment	Post treatment	Treatment outcome	Pre-treatment	Post-treatment	Treatment Outcome
Occlusal values	36mm	36mm	0mm	51mm	54mm	3mm
Gingival value	36mm	39mm	3mm	56mm	58mm	2mm
Alveolar values	36mm	38mm	2mm	58mm	61mm	3mm

Table no 3(B): Apical base width changes-Mandible

	Mandible					
	Inter molar width(E)			Inter molar width(6)		
	Pre-treatment	Post-treatment	Treatment outcome	Pre-treatment	Post-treatment	Treatment outcome
Occlusal values	40mm	40mm	0mm	46mm	46mm	0mm
Gingival value	57mm	57mm	57mm	57mm	57mm	0mm
Alveolar values	49mm	50mm	1mm	59mm	59mm	0mm

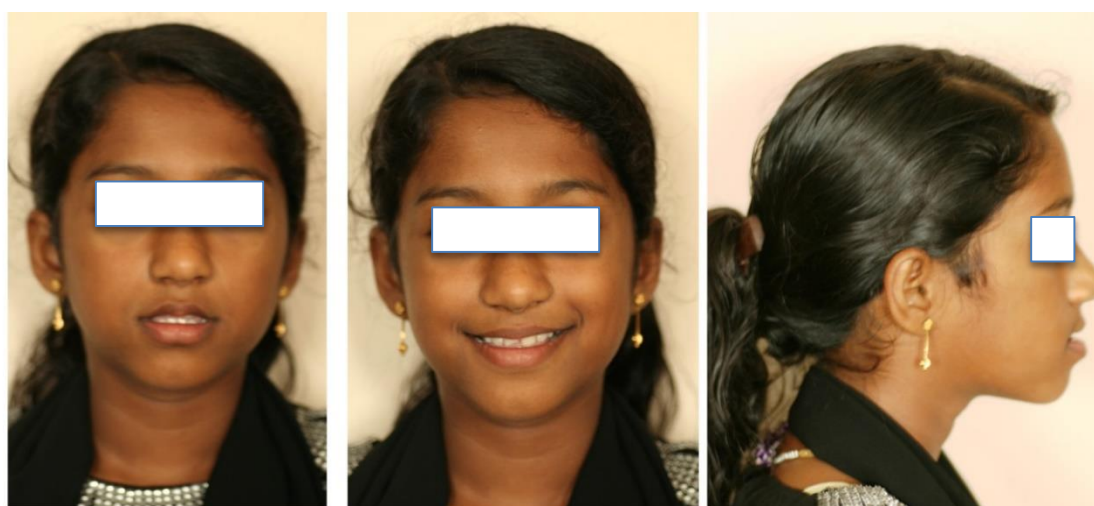

Fig 1: Pre treatment photographs

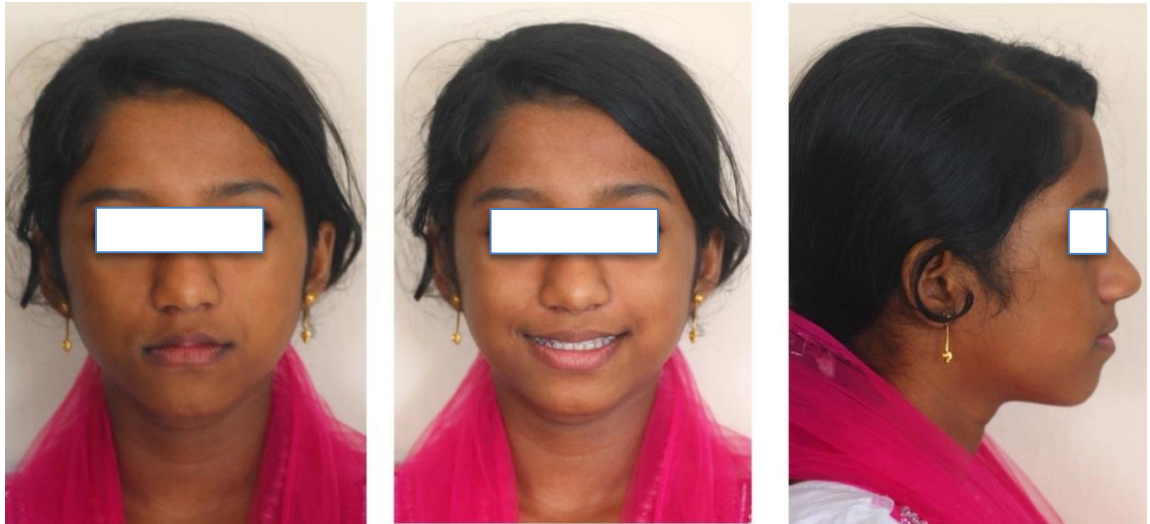

Fig 2: Post-treatment photographs

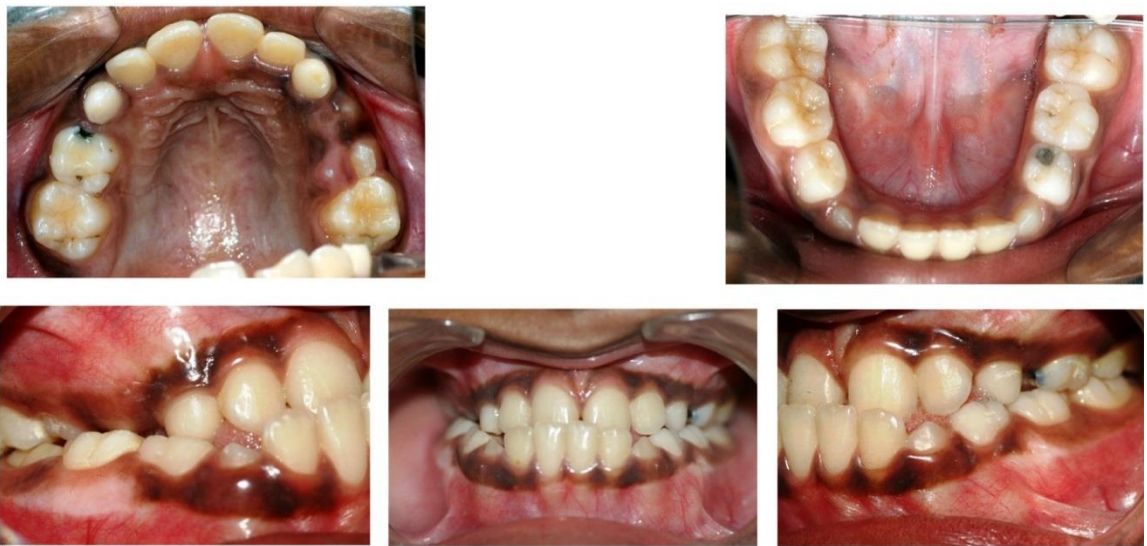

Fig 3: Pre-treatment intra oral view

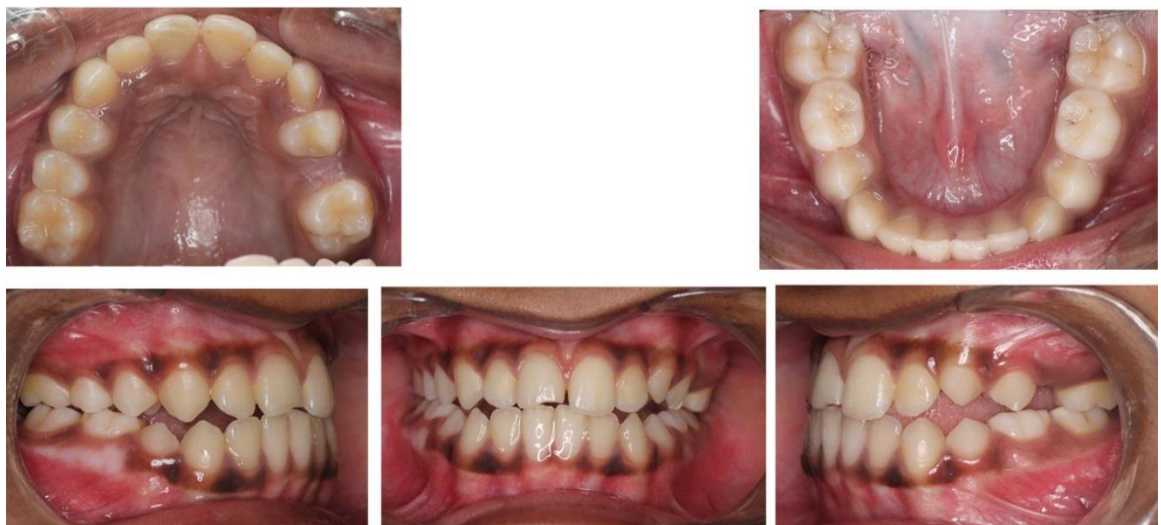

Fig 4: post-treatment intra oral view

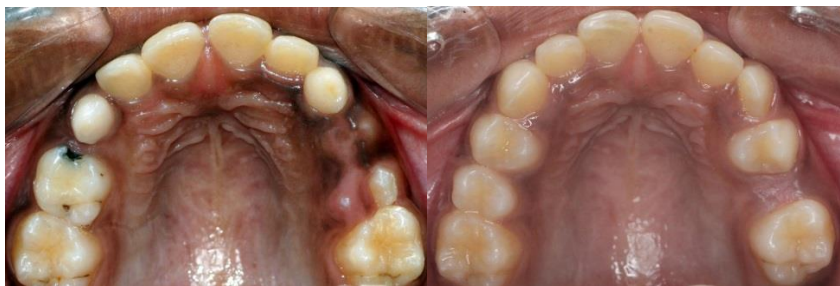

Fig 5: Pre and post treatment upper arch changes



Fig 6: Pre and post treatment upper arch changes in study models

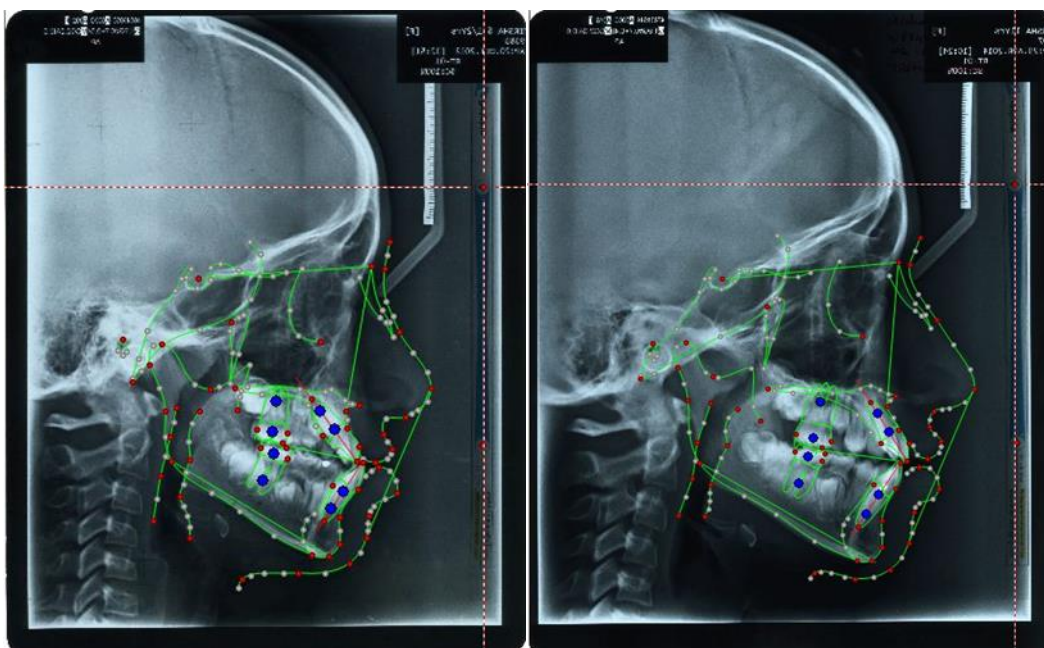


Fig 7: Pre and post Cephalometric changes

Discussion:

Clinically, patients with Class III malocclusion often present with a concave facial profile, a retrusive nasomaxillary area and a prominent lower third of the face. The lower lip is often protruded to upper lip. The result of this patient showed that FR-III appliance in the Class III malocclusion can result in beneficial effect on the

maxillofacial complex, skeletal and facial soft tissues.

Skeletal changes

The FR-III appliance has been known to restrict forces of associated soft tissues on the maxillary complex while transmitting these forces through the appliance to the mandible. This is

accomplished mainly through the lip pad, which eliminates the restrictive pressure of the upper lip on the underdeveloped maxilla, exerts tension on the tissue and periosteal attachment to stimulate bone growth, that results apposition of bone and advancement of maxillary skeletal base. It also controls mandibular growth to a backward and downward direction by delivering upper lip pressure to the lower labial wire. The ANB angle is one of the most important parameters to show the skeletal changes in the treatment of Class III malocclusion. The ANB angle, which was negative (-2.9°) at the beginning of the treatment, increased significantly (0°) at the end of the treatment.

The effect of FR-III treatment on SNA angle was less marked. Ulgen and Firatli, Kerr⁵ and Ten Have, and Kerr, Ten Have and McNamara also mentioned no significant difference in the increase of the SNA angle. However, Frankel claimed that the bone apposition at point an increase with the FR-III appliance. He compared the increase of the distance between occipital and point A. In this case SNA angle was increased from 78.8° to 80.8° at the end of the treatment.

Dental changes

The upper incisor proclination was improved (upper incisor to SN showed 5.9° improvement) whereas the lower incisor remained upright due to the presence of labial bow of the appliance. The reduction of upper incisor Proclination is the sum of the effects of the additive downward and backward rotation of mandible, increase in the ANB angle and retroclination of the lower incisor.

Soft tissue changes

Facial convexity angle showed the Class III relation in the beginning of the treatment (168°) and it became Class I relation (159°) at the end of the treatment. Various soft tissue changes combined to improve the Class III. A forward movement of upper lip, backward movement of lower lip, soft tissue chin thickness were contributed to the profile more convex related to Class III concave profile.

Arch width and apical base width

Numerous studies have been carried out to evaluate dentoskeletal and soft tissue changes in sagittal direction, and great number of them supported the idea that the FR-III appliance therapy produced a favorable growth effect on maxilla and surrounding soft tissue structures. However, the studies on transversal dentoalveolar changes are limited in number, and according to their finding, favorable dentoalveolar effects can be obtained with the FR-III appliance therapy.

Frankel³ claimed that the principle behind the transverse expansion is the functional matrix theory proposed by Moss. According to this theory,

non-skeletal tissues, organs or functioning spaces determine the growth, development and ultimate morphology of the skeletal tissue of the body. The vestibular shield and labial pads act as an artificial matrix by keeping away the orbicularis oris, buccinators, pterygomandibular raphe and superior constrictor of pharynx. Thus FR provides a larger functional matrix. The vestibular shields and labial pads act in a number of ways to bring about arch expansion

1. Restraintment of muscular forces: The shields keep away muscular forces from acting on the dentition. It is even said that the shields displace the muscular attachments in an outward direction.
2. Unapposed tongue pressure: Unlike most other functional appliance the lingual volume is reduced by bulky acrylic elements leading to unopposed tongue pressure within.
3. Periosteal pull: Another mechanical effect of vestibular shields is the tractions of our outer alveolar surface facing the apical third of the root. As cited by Frankel, the periosteum comes under a directionally altered strain leading to an altered inclination of the regional sub periosteal fibers and as a consequence, to an alteration in the orientation of the new sub periosteal trabeculae.
4. Guidance of eruption: Since the mandibular canine and premolars are covered buccally only by a thin bony layer, it is supposed that it can be easily bent outward by the growing and erupting teeth. Traction on the apical part of buccal cortical plate facilitates drift of the teeth in an outward direction.

The results indicate that expansion of maxillary arch was more than that of mandibular arch in general (table no: 2, 3A, 3B)

Conclusion:

1. The maxilla and surrounding soft tissues showed significant anterior movement, whereas mandibular and surrounding soft tissue growths were inhibited, and vertical dimensions were increased.
2. The Class III occlusion and reverse overjet were improved by means of skeletal changes in conjunction with upper incisor proclination and uprighting of lower incisor.
3. Frankel appliance therapy resulted in upper arch expansion in this case report. The Class III occlusion and reverse overjet were improved by means of skeletal changes in conjunction with upper incisor proclination and uprighting of lower incisors.

Reference

1. Pter Nagan, Annie M Hu, Henry W. Fields, Treatment of Class-III problem begins with differential diagnosis of anterior crossbites (Pediatric Dentistry-19:6,1997:386-395)
2. McNamara and Scott.A.Huge ,The functional regulator(FR-3) of Frankel, (AM J Orthod 88:409-424)
3. P.P.Biswas.K.Sadashiva Shetty and Ashima Valiathan. Arch expansion with Frankel appliance(JCO Vol 24:Number2, April,1993)
4. Rolf Frankel and Christine Frankel, Orofacial Orthopedics with the Function Regulator.
5. Musthafa Ulgen ,Sonmez Firatli,Dr.Med.Dent,Effects of the Frankel function regulator on class -3 malocclusion(AJO-DO,1998JUN,561-567)
6. R.R.Miethke,S.Lindenau and K.Dietrich, The effect of Frankel's function regulator type-III on apical base(EJO-25-,2003,311-318)
7. Kerr W J,Ten Have and McNamara ,A comparison of skeletal and dental changes produced by Function Regulator(FR-II and FR-III)(EJO1989,235-242)
8. Nihat Kilic, Mevlüt Celikoglu and Hüsametlin Oktay ,Effects of the functional regulator -III on transversal changes: a postero-anterior cephalometric and model study EJO33 (2011) 727–731)
9. Nihat Kilic, Mevlüt Celikoglu and Hüsametlin Oktay ,Effects of the functional regulator-III on profile changes in subjects with maxillary deficiency: EJO32 (2010) 729–734)
10. Xianrui Yang, Chunjie Li, Ding Bai, Tian Chen, Yang Xu, Treatment effectiveness of Frankel function regulator on class -3 malocclusion-Systematic review and metaanalysis(AJO-DO, VOL146,143-154).