

Fine Needle Aspiration Cytology of Maxillary Osteosarcoma - A Case Report

Vedita Bobde^{1,*}, Meena Pangarkar², Dinkar Kumbhalkar³, Rakha Patil⁴, Satish Helwatkar⁵

^{1,4}Assistant Professor, ^{2,5}Associate Professor, ³Professor and Head,
Dept. of Pathology, GMC, Nagpur

*Corresponding Author:

E-mail: vedita_golhar@rediffmail.com

ABSTRACT

Osteosarcoma (OS) is the most common primary malignant bone tumor. Craniofacial osteosarcoma is a rare entity comprising of 5-7% of all osteosarcoma. Chondroblastic subtype is most common in jaw lesions. FNAC findings along with characteristic radiological features can give definitive diagnosis for early management.

Key words: Maxilla, Osteosarcoma, Chondroblastic OS.

INTRODUCTION

Osteosarcoma(OS) is the most common primary malignant bone tumor of the jaw comprising of 5-7% of all osteosarcoma. The age incidence peaks one to two decades later than for skeletal OS. Of the two jawbones, Mandible is preferred site than maxilla. Equal sex incidence is reported. Majority of maxillary tumor are intramedullary type occurring at alveolar ridge. Microscopically chondroblastic variant is more common. Preoperative diagnosis allows for neoadjuvant chemotherapy. Multimodality therapy is state of art current therapy used for treatment similar to that used for osteosarcoma of the extremities.^{1,2} Cytology is helpful in early diagnosis and minimizes patient discomfort and time for histological diagnosis with accuracy more than 90%.^{3,4} We report a case of OS of maxilla in a 22 year old male.

region. **Figure 2-** CT scan head and PNS study. CT scan revealed cortical destruction with sunburst type of periosteal reaction involving the walls of maxillary sinus associated moderately heterogenous enhancing soft tissue component with intraorbital extension. Metastasis to other parts of body was ruled out by CT abdomen and chest. FNAC showed moderately cellular smears with chondromyxoid stromal fragments (magenta colour in Romanowsky stains) and pleomorphic tumor cells. Tumor cells were oval, spindle, polygonal with moderate cytoplasm and pleomorphic hyperchromatic nuclei with prominent nucleoli. Plenty of tumor giant cells were noted. Dense eosinophilic material corresponding to tumor osteoid adjacent to the chondromyxoid fragments was also noted. **Figure 3-4-** FNAC smears. Cytological diagnosis of osteosarcoma probably chondroblastic variant was given. Considering the destructive nature of the lesion, debulking radical maxillectomy was done. We received two tissue pieces comprising of tumor mass and tumor with partial maxillectomy. Tumor mass was showing myxoid appearance on gross. **Figure 5-** gross picture. Histopathology confirmed the diagnosis of chondroblastic OS showing arrangement of atypical mesenchymal tumor cells in lobules with variably mineralized osteoid. Few osteoclastic giant cells were also noted. **Figure 6-** histopathology image. Patient was alright after three months of surgery without any recurrence.

Access this article online	
Quick Response Code: 	Website: www.innovativepublication.com DOI: 10.5958/2394-6792.2015.00035.6

CASE

A 22 year old male patient presented with pain and rapidly increasing right cheek swelling since 1 month. Patient was unable to open right eye with watering since 15 days. No other symptoms were present. Patient was a chronic tobacco chewer since 4-5 years. On examination firm to hard, nontender, irregular, swelling, fixed to adjacent tissue, of size 5x5 cm in right malar region was noted. Overlying skin was normal. **Figure 1-** clinical photograph of patient. X ray showed radio-opacity in the maxillary



Fig. 1: Clinical photograph of patient. A hard mass in the right maxillary region with watering of right eye

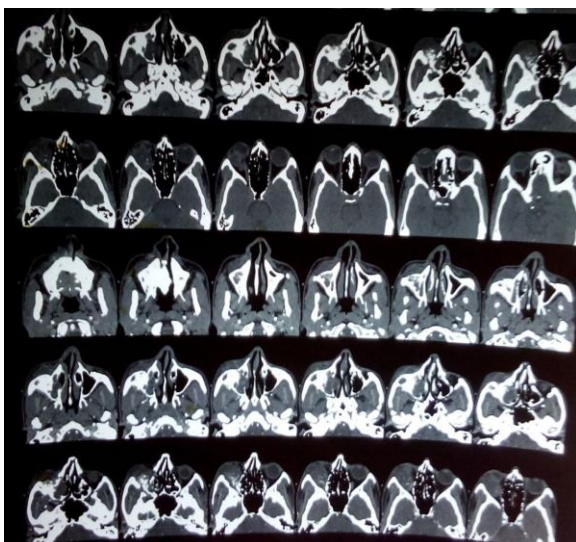


Fig. 2: CT scan head and PNS study. Cortical destruction with sunburst reaction involving the walls of maxillary sinus associated with soft tissue component with intraorbital extension

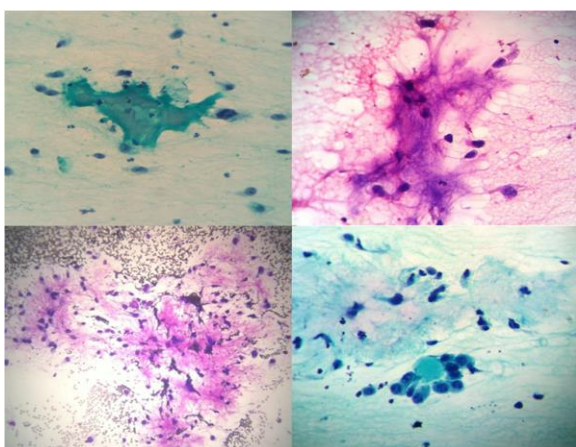


Fig. 3: FNAC smears- Neoplastic cells entangled in chondromyxoid background and surrounding dense osteoid material

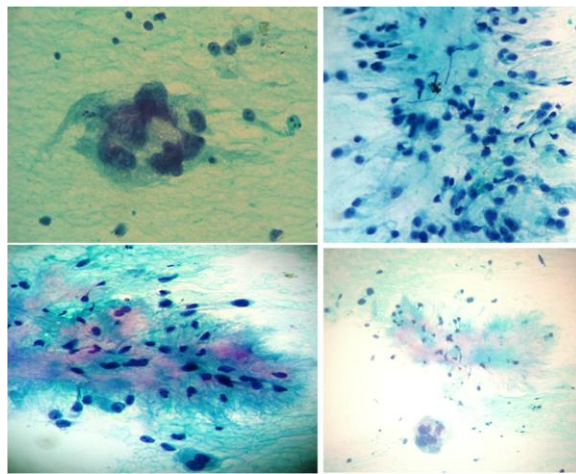


Fig. 4: FNAC smears- uninucleated, binucleated and multinucleated tumor cells in chondromyxoid material

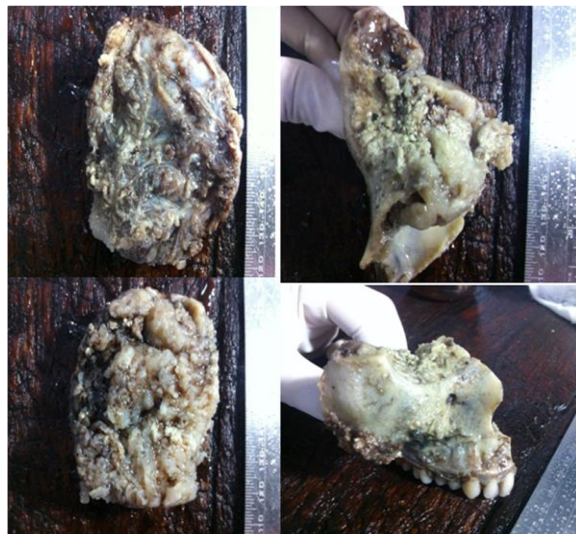

Fig. 5: Gross picture- Tumor mass multilobulated, showing necrotic and myxoid appearance on external and cut surface arising from the right maxilla

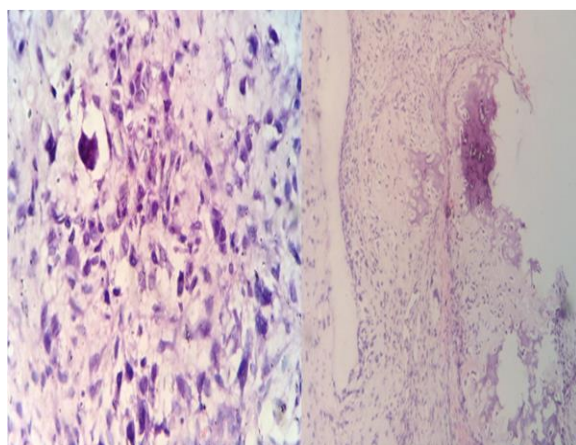


Fig. 6: Histopathology image. - Low and high power view showing chondroblastic variant of osteosarcoma with neoplastic tumor cells and tumor osteoid with varying degree of mineralization

DISCUSSION

OS of jaw bones are considered as distinct entity due to favourable biologic behavior. In most reported cases patients are typically older average age being 35 years at initial presentation.⁴ Some reported cases are below 20 years of age.^{5,6,7} Paget's disease, fibrous dysplasia and ionizing radiation are thought to be predisposing factors. Jaw OS represents only 4% of all OS reported.⁸ Most patients presents with continuous nonradiating pain aggravated with eating and yawning with rapidly increasing swelling in jaw region.⁹ Radiologically the lesion may range from purely lytic to virtually sclerotic. CT scan of the primary lesion helps in delineating the location and the extent of the tumor and is critical for surgical planning. MRI is the best method for assessing the extent of intramedullary disease.⁹ The conventional type has been sub-classified into osteoblastic, chondroblastic, fibroblastic and mixed types. Higher percentage of tumor presents with a lower histologic grade. Improved survival has been reported with the lower grade chondroblastic subtype. The malignant osteoid is often laid down in a lace like pattern with or without mineralization(calcification). It's close association with malignant osteoblasts or spindle cells is diagnostic of OS in appropriate radiological setting. Osteoid/bone, chondroid and hyaline cartilage appear tinctorially similar and absolute distinction is not always possible on FNAC.⁴ Neoplastic cartilage is usually hyaline but may be myxoid, particularly in jaw tumors. The malignant chondrocytes demonstrates severe cytologic atypia and reside in lacunar spaces in hyaline matrix, or floats singly or in cords in myxoid matrix. Chondroblastic OS can be confused with chondrosarcoma in FNAC and small biopsy if osteoid formation is not seen. Immunohistochemistry plays important role in differentiating between the two. Chondrosarcoma is positive for S100 and vimentin and negative for Cytokeratin and EMA. Chondroblastic OS is positive for Vimentin and EMA and rarely S100 and negative for Cytokeratin. Chondrosarcoma is a tumor of elderly but needs to be differentiated from OS as it has good prognosis. Clinical and radiologic correlation helps in diagnosis. The FNA findings of OS are subclassified into five types 1)pleomorphic, 2)epithelioid, 3)chondroblastic, 4)small cell and 5)mixed.¹⁰ Most of the lesions show pleomorphic subtype. Our case showed chondroblastic type of OS confirmed on histology similar to earlier reported cases which is also the most common variant in maxillary region.^{5,6,7,9} Wide local excision followed by chemotherapy is the mainstay of treatment.

CONCLUSION

Due to complexity of the anatomical site and close proximity to vital structures early diagnosis is

desirable in maxillary lesions. To save these vital organs from local invasion in malignant tumors cytology helps in avoiding painful and lengthy biopsy procedures for confirmation of diagnosis. Treatment can be planned accordingly for better prognosis in patients and longer survival. Osteosarcoma can be diagnosed on cytology with proper correlation with clinical and radiological findings.

Conflict of interest: No Conflict of Interest.

REFERENCES:

1. Rosai J. Rosai and Ackermans Surgical Pathology. Michael Houston, Mosby, Elsevier; Tenth Edition. 2011; Vol 1 : 265-89.
2. Brandwein M, Silverberg SG. Silverberg's Principles and Practice of Surgical Pathology and Cytopathology. Elsevier; Fourth edition. Vol 1:815-16.
3. Kilpatrick SE, Ward WG, Bos GD, et al: The role of Fine needle aspiration biopsy in the diagnosis and management of osteosarcoma. *Pediatr Pathol Mol Med* 2001;20:175.
4. Kilpatrick SE. Diagnostic Musculoskeletal Surgical Pathology clinicoradiologic and cytologic correlations. Saunders: first edition. Osseous tumors of bone and soft tissue:284-304.
5. Contar C, Dirschnabel A, Temele M, Maffei C, Martins W, Ribas M. Osteogenic Sarcoma of the Maxilla: Case Report. *Applied Cancer Research*. 2008;28(1):33-6.
6. Adwani D, Bhattacharya A, Adwani N, Adwani R, Sharma V. Massive Recurrent Chondroblastic Osteosarcoma of Maxilla:A rare case report. *Journal of Clinical and Diagnostic Research*. 2014;8(1):288-90.
7. Kumaravelu C, Satya Kumar D, Chakravarthy C, Kishore Kumar RV, Gali R, Reddy G, et al. Chondroblastic osteosarcoma of maxilla: a case report and review of literature. *J Maxillofac Oral Surg*. 2009;8(3):290-93.
8. Abdulmalak Al-Yahya, Abdulaziz BinAhmed, Talal Alshammari. Maxillary Osteosarcoma: Two Case Reports and Literature Review. *OHDM*. 2014;13(2):525-8.
9. Khadse SV. Chondroblastic Osteosarcoma of Jaw Bone. *Journal Of Case Reports*. 2013;3(2):480-84.
10. White VA, Fanning CV, Ayala AG, et al. Osteosarcoma and the role of fine needle aspiration. A study of 51 cases. *Cancer* 1988;62:1238-46.