

A Study of Fine Needle Aspiration Cytology of Thyroid Lesions with Histopathological Correlation

Ranjan Agrawal^{1,*}, Manoj Saxena², Parbodh Kumar³

¹Professor, Department of Pathology, Rohilkhand Medical College Hospital, Bareilly
²Assistant Professor, Teerthanker Mahaveer Medical College & Research Centre, Moradabad
³Professor & Head, Department of Pathology, Rohilkhand Medical College Hospital, Bareilly

*Corresponding Author:
E-mail: drranjan68@gmail.com

ABSTRACT

Background: Fine Needle Aspiration Cytology (FNAC) is important for pre-operative and pre-treatment diagnosis of benign and malignant thyroid lesions, thus decreasing the incidence of unwanted surgeries.

Objectives: The present study aims to classify various cytomorphological lesions of the thyroid according to The Bethesda System for Reporting of Thyroid Cytopathology (TBSRTC) and correlate these with histopathology wherever possible.

Material & Methods: A prospective study was conducted in a tertiary care centre of Western Uttar Pradesh to evaluate the diagnostic accuracy of FNAC in lesions of thyroid during a 2 year period. The cytological findings were classified according to the recent TBSRTC. Cyto-histopathological correlation was done in all the cases subjected to surgery.

Results: Out of total 281 cases studied, 247(87.90%) were benign, 4(1.42%) were neoplastic, 5(1.78%) were suspicious for malignancy, 7(2.49%) were suspicious for a follicular neoplasm, 11(3.91%) were Atypia of undetermined significance and 7(2.49%) were inadequate. Cyto-histopathologic correlation of 134 cases was done. Sensitivity, specificity and diagnostic accuracy of the study for malignant lesions were 96.7%, 100 % and 97.0% respectively.

Conclusions: FNAC is a safe, simple, highly accurate, economical and universally accepted modality for evaluation of thyroid lesions especially in developing countries such as India. FNAC helps in avoiding unwanted surgeries in patients diagnosed to have a benign pathology based on cytology. Those that are grouped in the suspicious or indeterminate category on cytology include lesions of uncertainty that are finally confirmed on histopathology.

Keywords: FNAC, Thyroid, Histopathology correlation, Diagnostic Accuracy, Sensitivity, Specificity.

INTRODUCTION

Fine-needle aspiration cytology (FNAC) plays a vital role in the evaluating patients with thyroid nodules. Thyroid nodules are a common clinical finding with reports of a prevalence ranging from 4–7% of population available in the literature.^[1,2] The vast majority of thyroid nodules are non-neoplastic lesions and only < 5% are malignant. Clinical features alone cannot distinguish between benign and malignant nodules.^[3] Thyroid cytology not only provides a definite diagnosis of malignancy but also the tumour type, thus enabling appropriate therapeutic surgery. Benign lesions can be managed conventionally. However, the incidence of thyroid malignancy is quite low and only 1 in 20 clinically identified nodules turn out to be malignant, thyroid FNAC helps in reducing the rate of surgery for benign thyroid diseases.^[1,4,5] Aspirations considered unsatisfactory or inadequate should be subjected to a

repeat aspiration since malignancy has been reported in 4-15 % of such cases.^[6]

AIMS & OBJECTIVES

The present study was undertaken with the aim of classifying the cytomorphology of palpable thyroid lesions by FNAC as per The Bethesda System for Reporting of Thyroid Cytopathology (TBSRTC)^[7] and correlate the results with histopathology wherever possible.

MATERIAL & METHODS

This was a prospective study of 281 diagnosed cases of thyroid lesions referred to the Cytopathology section for FNAC. The period of study was 2 years starting from January 2013 to December 2014. Information about the patient's age, sex, ultrasonography findings, and cytological report was recorded. Of these patients who underwent surgery for lobectomy or partial or total thyroidectomy were subjected to histopathological examination and then their diagnoses were recorded. Aspiration was done with full aseptic precautions using 23 gauge needle using a 10 ml syringe. Multiple smears were prepared from the aspirate and those immediately fixed in 95% ethanol were stained using Haematoxylin and Eosin (H&E) and Papanicolaou (Pap) stains and air dried smears were

Access this article online	
Quick Response Code:	Website: www.innovativepublication.com
	DOI: 10.5958/2394-6792.2015.00028.9

stained with May Grunwald Giemsa (MGG). Whenever the aspirate yielded fluid, it was cytocentrifuged and the smears were prepared from the sediment and stained using the above mentioned stains. TBSRTC was followed for reporting and cytological classification of the lesions. Cytological diagnosis was correlated with the histopathology report in all the cases that underwent surgery. Patients with other neck swellings were excluded from the present study. SPSS software was used for statistical analysis.

RESULTS

The present study included a total of 281 patients having thyroid lesions. The age range of patients was from 8 years to 76 years with a mean age of 38.24 years. Females were 227 and males were 54 with a F:M ratio of 4.2:1. The results were categorized as per the recent 2007 Bethesda classification into – I-Non-diagnostic or unsatisfactory; II-Benign; III – Atypia of undetermined significance (AUS) or follicular lesion of undetermined significance; IV-Follicular neoplasm or suspicious for a follicular neoplasm; V- Suspicious for malignancy and, V- Malignant categories [Table I; Figure 1]. Aspirates yielding insufficient or low

cellularity or those that were of poor quality were considered “unsatisfactory”. For thyroid FNAC specimens to be labelled as satisfactory for evaluation at least 6 groups of benign follicular cells are required and each group should be composed of at least 10 cells. This group also comprised of aspirates consisting of cyst fluid only aspirates. Aspirates classified as benign included colloid goitre, colloid or adenomatous nodule, hashimoto’s thyroiditis, sub-acute thyroiditis, and cysts of thyroglossal duct. Suspicious smears included follicular neoplasms, cellular adenomatoid nodules, hurthle cell proliferations and lesions suspicious for malignancy. Benign lesions comprised the maximum number of cases 247 (87.90%), followed by AUS in 11 (3.91%) cases. The patients mean age in the malignancy and the suspicious for malignancy category was higher as compared to that in the benign category. Cases that underwent lobectomy, partial or complete thyroidectomy were subjected to histopathological examination. The biopsy reports were correlated with the pre-operative cytology reports. (Table II) Comparison of the outcome of the present study with other previous studies available in the literature is shown in Table III.

Table I: Showing Age & Sex distribution of cases in different subtypes of Bethesda Classification

Cytological Diagnostic Category												
Age Group (Years)	I		II		III		IV		V		VI	
	M	F	M	F	M	F	M	F	M	F	M	F
< 10	-	-	-	4	-	-	-	-	-	-	-	-
11-20	-	1	3	30	-	3	-	-	-	-	-	-
21-30	-	-	24	40	-	3	-	-	-	1	-	1
31-40	-	1	12	64	1	2	-	2	-	1	-	-
41-50	-	2	8	42	-	2	-	3	1	1	-	2
51-60	1	1	2	17	-	-	-	1	-	1	-	-
> 60	-	1	1	1	-	-	-	1	-	-	1	-
Total	1	6	50	197	1	10	0	7	1	4	1	3
% Cases	2.49%		87.90%		3.91%		2.49%		1.78%		1.42%	
Average Age (Years)	46.86		34.91		31.64		49.71		43.57		47.50	

Table II: Cytohistopathological Correlation of Thyroid Lesions

Cytological Diagnosis	Histopathological Diagnosis											
	n	Thyroglossal Cyst	Colloid Goitre	Thyroiditis	Tubercular	Adenomatous Goitre	Follicular Adenoma	Follicular carcinoma	Hurthle Cell Adenoma	Papillary Carcinoma	Medullary Carcinoma	Anaplastic Carcinoma
Non-Diagnostic	3	1	2	-	-	-	-	-	-	-	-	-
Thyroglossal Cyst	2	2	-	-	-	-	-	-	-	-	-	-
Colloid Goitre	84	2	77	1	-	2	2	-	-	1	-	-
Adenomatous Goitre	9	-	1	-	-	6	1	1	-	-	-	-
Hashimoto's Thyroiditis	14	-	1	13	-	-	-	-	-	-	-	-
Granulomatous Thyroiditis	2	-	-	-	2	-	-	-	-	-	-	-
Suspicious of Malignancy	5	-	-	-	-	-	-	-	-	2	-	2
Follicular Neoplasm	7	-	-	-	-	1	4	2	-	-	-	-
Hurthle Cell Neoplasm	4	-	1	-	-	1	-	-	2	-	-	-
Papillary Carcinoma	1	-	-	-	-	-	-	-	-	1	-	-
Medullary Carcinoma	1	-	-	-	-	-	-	-	-	-	1	-
Anaplastic Carcinoma	2	-	-	-	-	-	-	-	-	-	-	2
Total	134	5	82	14	2	10	7	3	2	4	1	4

Table III: Table showing comparison of results of present study with the previous studies

Study	Year	Sensitivity	Specificity	Accuracy
Silverman JF ^[21]	1986	93.0	95.1	94.0
Gharib&Goellner ^[2]	1993	98.0	99.0	98.4
Afroze N ^[24]	2002	61.9	99.3	94.6
Uma H ^[6]	2008	97.0	100	98.5
Bukhari MH ^[26]	2008	90.0	87.5	87.0
Gupta M ^[4]	2010	80.0	86.6	84.0
Prakash HM ^[23]	2011	66.7	98.4	95.7
Sengupta A ^[25]	2011	90.0	100	98.9
Esmaili HA ^[15]	2012	91.6	100	97.0
Present Study	2015	96.7	100	97.0

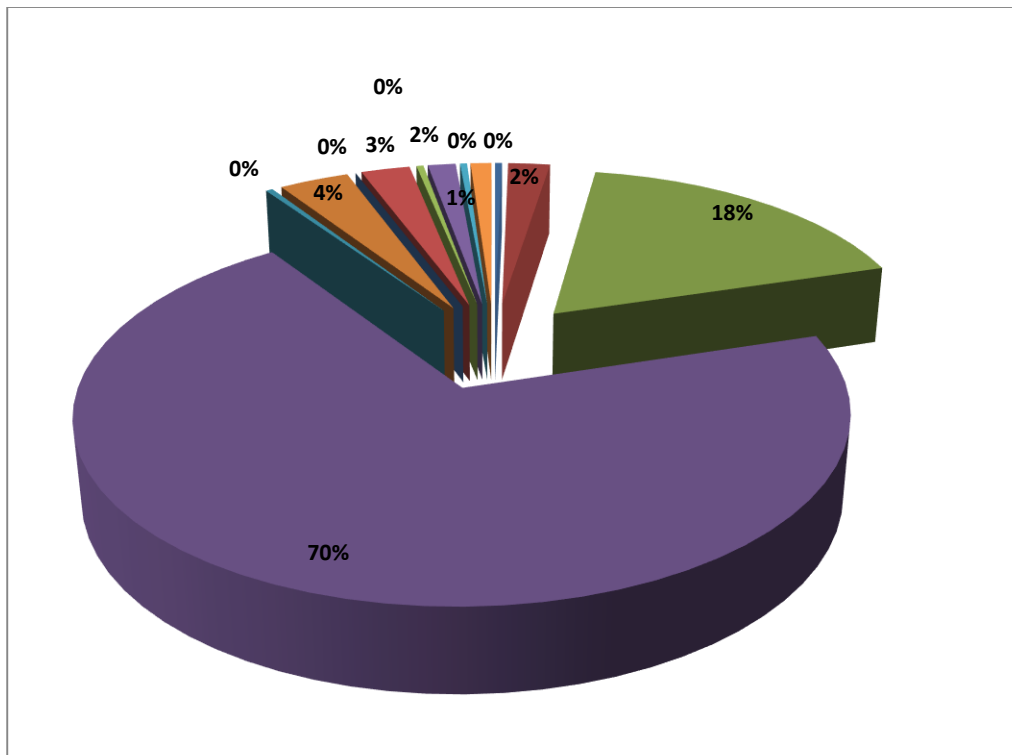


Fig. 1: Age and Sex wise distribution of Cases as per the Bethesda System

DISCUSSION

Thyroid FNAC was initially started by Martin and Ellis in 1930. The terminology used for reporting thyroid FNAC has shown significant inter-laboratory variations, creating confusions and also interfering with the data exchange among different centres. Keeping this in view in 2007 TBSRTC was evolved with the aim of forming a uniformity in the reporting of FNAC findings of thyroid that would facilitate effective discussion among cytopathologists and clinicians; facilitate correlation between cytopathology and histopathology, epidemiological studies, molecular genetics, and, diagnostic interpretation of thyroid diseases in particular neoplasia. It also ensured that the data between various laboratories and institutions could be shared without any specific interpretive mistakes.^[7]

Palpable thyroid nodules are present in approximately 4–7% of adults^[1,2] and are more common in females with a F:M ratio of 4.2:1.^[4-6] In the present study also there was a female predominance.^[8,9] Thyroid nodules may lead to either hypo or hyperthyroidism, cosmetic and compression problems, besides having the potential for malignancy. Accurate evaluation of thyroid nodules is thus crucial. In recent years, the role of FNAC is increasing regarding detection of thyroid nodules which are malignant. Thyroid gland carcinoma accounts for less than 1% of all cancers and is responsible for 0.5% of all cancer-related deaths.^[10] Early diagnosis of such cases is thus important for

aiming at higher life expectancy especially since thyroid gland cancers have a low malignant potential and also have a slow progressive property. Majority of the clinically diagnosed palpable thyroid nodules are non-neoplastic.^[4,5,7,11,12] Multiple aspirations avoid missing a neoplastic focus.

Every thyroid FNAC should be evaluated for adequacy of the smears. Smears that are inadequate for reporting are categorised as “non-diagnostic” (ND) or “unsatisfactory” (UNS) and include smears that show obscuring blood, are overly thick, those alcohol-fixed slides subjected to air drying, or those having an inadequate or less number of follicular cells in the slides. Specimens containing large amount of colloid is considered adequate and benign, even if 6 groups of follicular cells are not identified in the smears. Cyst-fluid-only (CFO) cases are considered to be a subset of ND/UNS. The risk of malignancy reported in the ND/UNS (not including CFO) category ranges from 1% to 5.5%.^[13-16] A repeat aspiration under high ultrasound guidance is recommended in such cases. However, some nodules remain persistently ND/UNS even on repeat aspirations and should be subjected to surgical excision.^[14,17,18] Non-diagnostic or insufficient samples are common in nodules that are calcified, sclerotic or in those that have undergone major cystic degeneration. As per the review of literature the rate of ND/UNS ranges between 16 to upto 20%.^[11, 12, 16, 18] In the present study, the rate of non-diagnostic tests

was 2.49%. Few authors suggest that the rate of non-diagnostic tests should be kept below 10%.^[19]

Some thyroid FNAC reports cannot be classified with ease into the benign, suspicious, or malignant categories and are reported as "atypia of undetermined significance" (AUS) or "follicular lesion of undetermined significance (FLUS)." This category includes a number of lesions that show morphological abnormalities of the follicular cells with or without presence of nuclear atypia. Benign cellular changes including lining cyst cells, focal Hürthle cell changes and, cellular changes following therapy with radioiodine should not be included in the category of AUS. As per the literature AUS constitutes about 3 to 6% of thyroid FNAC reports.^[17] AUS accounted for 3.91% of all the cases in our study. The recommended management of such lesions includes clinical correlation and repeat FNAC after an appropriate interval. Only about 20% of such nodules repeated for FNAC still remain as AUS. These cases are subjected to excision biopsy.

FNAC has a good diagnostic role in many thyroid lesions especially for papillary carcinoma (PTC) and lymphocytic thyroiditis. For thyroid follicular carcinoma, FNAC is considered as a "screening test" and these smears are reported as "follicular neoplasm" (FN) or "suspicious for a follicular neoplasm" (SFN). This category of Follicular neoplasm forms a gray zone with various differentials such as follicular carcinoma, follicular variant of papillary carcinoma, follicular adenoma and adenomatoid nodule. To label it as Follicular carcinoma, histopathology must show evidence of vascular and/or capsular invasion. In general, smears from adenomatous nodules show less number of cells, have presence of dispersed rather than tightly cohesive follicular cells and more colloid than those from follicular neoplasms. About 35% cases do not show any evidence of neoplasia but rather show hyperplastic proliferations of follicular cells, as in multinodular goitre.^[15,20] 15 to 33% of FN/SFN cases prove to be malignant of which a significant proportion is constituted by follicular variant of papillary carcinoma.^[2,13,15,17,18] Many a times the nuclear and architectural changes of some PTCs are patchy and not well discerned especially as seen in follicular variant of PTC, thus mimicking a benign follicular nodule on cytology. Nodules are resected by lobectomy or semi/total thyroidectomy.^[2,15,17] Follicular lesions are categorized histopathologically as benign by some authors, while others categorize them as malignant.^[11,12,16] Inclusion of such cases in the benign or malignant category imparts a significant difference in the sensitivity and specificity rates.

As in the available literatures, the benign lesions represented the majority of cases. In our study benign lesions constituted 247 (87.9%) cases. This is

in accordance to the previous other studies. The lesions included in the benign category were thyroglossal cyst, colloid goitre, adenomatous goitre, hashimoto's thyroiditis, and granulomatous lesions. Two cases diagnosed as granulomatous on FNAC were proved to be tubercular on histopathology. One of these had miliary tuberculosis, while in the other there was no evidence of tuberculosis elsewhere in the body. Cytologically all benign thyroid nodules need not be subjected to histopathological evaluation. In the present study the sensitivity for cytological diagnosis of neoplasia was 96.7%, specificity 100% and diagnostic accuracy of 97.0%, thus showing a good positive correlation with histopathology. Our results were comparable with the previous published data where FNAC of thyroid is reported to have sensitivity ranging from 40% to 100%, and a specificity of 45% to 100%.^[2, 19-26] Various Factors contribute to this wide range of sensitivity and specificity. It depends on the adequacy of samples, technique of sample collection, the experience of the pathologist interpreting the smears, presence of overlapping cytological findings between some benign and malignant thyroid lesions and, duration of follow-up of the patient. FNAC has an overall accuracy rate of around 90-100% in the detection of thyroid malignancy.^[6,23] The present study showed a rate of 100%.

Any and every diagnostic procedure has its own limitations and diagnostic fallacies. It includes the presence of false negative (FNR) and false positive results (FPR) particularly with small tumours and when there is simultaneous inflammatory or degenerative changes in the surrounding tissue. Some of the lesions showing overlapping features cannot be distinguished cytologically with full confidence such as cellular colloid goitre and follicular neoplasm. It is so especially when there are presence of microfollicular arrangement of the cells in the former.^[25,26] FNR usually occur following sampling errors, co-existence of benign and malignant lesions, or due to presence of cytomorphologic overlap between benign and low grade malignant tumours. These cases are of great importance more so since they indicate the potential of missing an underlying malignant pathology. It is very difficult to estimate the true FNR because only a handful of patients with benign cytological findings proceed further for surgery. FNR ranged from 1% to 16% in different series of publications and has been estimated to be usually less than 5%.^[21, 23] FNR can be minimised by clinical follow-up and repeat aspiration to obtain adequate aspirates. FPR are less common and were not found in any patient in our study. This finding is consistent with the other reports that cited variable rates ranging from 0-9%.^[23, 25] FPR are usually seen in cases of colloid nodule and nodular hyperplasia with numerous macropapillary structures, has-

himoto's thyroiditis, follicular or parathyroid or adenomas with atypia. The sensitivity and specificity rate of thyroid FNAC as compared to histopathology may vary depending on the FNR, FPR and also on whether the suspicious cases are included in the negative or positive category.

No single diagnostic method helps in providing a definitive diagnosis of cancer thyroid. However, FNAC is still the procedure of choice, particularly if ultrasound is used as an ancillary technique for better sample collection.^[18] This holds true in cystic lesions. The interpretation errors can be reduced by obtaining aspirates from different portions of the lesion, using ultrasound-guided FNA procedure, advanced imaging techniques, immunologic analysis, electron microscopy and reviewing of slides by more than one cytopathologist. Both the cytopathologists should not be aware of each other's diagnosis thus making it a blinded method of quality control. The less palpable or ill-defined nodules may best be aspirated using ultrasound guidance, lest the palpable nodules are aspirated using standard methods. Thyroid scintigram shows neoplastic nodules as cold nodules. The cytological findings at times in Medullary carcinoma showing presence of giant cells may mimic the cytological findings seen in anaplastic carcinoma. In such cases application of Calcitonin Immunohistochemical marker, or electronmicroscopy usually helps in solving the problem.^[22]

CONCLUSIONS

FNAC exhibits an adequate diagnostic correlation with the final histopathological examination and enables a comparison of results between different institutions. Our results are consistent with those available in the literature. If the cytology report is malignant, surgery is the recommended procedure; for suspicious lesions, repeat aspiration is required and for benign lesions no further immediate diagnostic studies are required. FNAC is an invaluable tool in the management of thyroid lesions with a high degree of accuracy. It is safe, simple, cost-effective procedure with absence of major complications and can be performed on out-patients with wide patient compliance. FNAC provides a more rapid and accurate diagnosis of thyroid lesions than any other combination of clinical laboratory tests.

REFERENCES

- Gita J, Orell SR. Thyroid. In: Orell SR, Sterrett GF, editors. *Fine Needle Aspiration Cytology*. 5th ed. Philadelphia: Churchill Livingstone; 2012.118-55.
- Gharib H, Goellner JR. Fine needle aspiration biopsy of the thyroid:an appraisal. *Ann Intern Med* 1993;118:282-9
- Sinna EA, Ezzat N. Diagnostic accuracy of fine needle aspiration cytology in thyroid lesions. *J Egypt Natl*
- Cancer Inst. 2012;24 (2):63-70. DOI:10.1016/j.nci.2012.01.001
- Gupta M, Gupta S, Gupta VB. Correlation of fine needle aspiration cytology with histopathology in the diagnosis of solitary thyroid nodule. *J Thyroid Res* 2010; 10:1-5. PMID: PMC2956979
- Chandanwale S, Singh N, Kumar H, Pradhan P, Gore C, Rajpal M. Clinicopathological correlation of thyroid nodules. *Int J Pharm Biomed Sci* 2012;3(3):97-102.
- Uma H, Sukant G, Harsh M, Nitin N. Role of fine needle aspiration cytology in diagnosis and management of thyroid lesions: A study on 434 patients. *J Cytol* 2008; 25(1):13-7.
- Cibas ES, Ali SZ. The Bethesda System for Reporting Thyroid Cytopathology. *Am J ClinPathol* 2009; 132(5):658-65.
- Richmond BK, O'Brien BA, Mangano W, Thompson S, Kemper S. The impact of implementation of the Bethesda System for reporting thyroid cytopathology on the surgical treatment of thyroid nodules. *Am Surg* 2012; 78:706-10.
- Crowe A, Linder A, Hameed O, Salih C, Roberson J, Gidley J, et al. The impact of implementation of the Bethesda system for reporting thyroid cytopathology on the quality of reporting, 'risk' of malignancy, surgical rate, and rate of frozen sections requested for thyroid lesions. *Cancer Cytopathol* 2011; 119:315-21.
- Roman SA. Endocrine tumors: Evaluation of the thyroid nodule. *Curr Opin Oncol* 2003; 15:66-70.
- Pandey P, Dixit A, Mahajan NC. Fine needle aspiration of the thyroid: A cytohistologic correlation with critical evaluation of discordant cases. *Thyroid Res Pract* 2012; 9:32-9.
- Bagga PK, Mahajan NC. Fine needle aspiration cytology of thyroid swellings: How useful and accurate is it? *Indian J Cancer* 2010; 47:437-42.
- Ravetto C, Colombo L, Dottorini ME. Usefulness of fine needle aspiration in the diagnosis of thyroid carcinoma: a retrospective study in 37,895 patients. *Cancer*. 2000; 90:357-363.
- Renshaw AA. Focal features of papillary carcinoma of the thyroid in fine-needle aspiration material are strongly associated with papillary carcinoma at resection. *Am J ClinPathol*. 2002;118:208-10.
- Yang J, Schnadig V, Logrono R, Wasserman PG. Fine-needle aspiration of thyroid nodules: A study of 4703 patients with histologic and clinical correlations. *Cancer* 2007;111:306-15.
- Esmaili HA, Taghipour H. Fine-needle aspiration in the diagnosis of thyroid disease: An appraisal in our institution. *ISRN Pathology [Internet]*. 2012 Jun [cited 2012 Aug 2]; 912728:[about 4 p.]. Available from: <http://downloads.hindawi.com/journals/isrn.pathology/2012/912728.pdf>.
- Yassa L, Cibas ES, Benson CB, Frates MC, Doubilet PM, Gawande AA, et al. Long-term assessment of a multidisciplinary approach to thyroid nodule diagnostic evaluation. *Cancer* 2007; 111:508-16.
- Amrikachi M, Ramzy I, Rubinfeld S, Wheeler TM. Accuracy of fine needle aspiration of thyroid: a review of 6226 cases and correlation with surgical and clinical outcome *Arch Pathol Lab Med* 2001; 125: 484-8.
- Ali SZ. Thyroid cytopathology: Bethesda and beyond. *Acta Cytol* 2011; 55:4-12.
- Baloch ZW, LiVolsi VA, Asa SL, et al. Diagnostic terminology and morphologic criteria for cytologic diagnosis of thyroid lesions: a synopsis of the National

- Cancer Institute Thyroid Fine-Needle Aspiration State of the Science Conference. *DiagnCytopathol.* 2008; 36:425-37.
21. Silverman JF, West RL, Larkin EW, Park HK, Finley JL, Swanson MS et al. The role of fine needle aspiration biopsy in the rapid diagnosis and management of thyroid neoplasm. *Cancer* 1986, 57:1164-70.
 22. Caraway HP, SniegeN, SamanNA. Diagnostic pitfalls in Thyroid Fine Needle Aspiration: a review of 394 cases. *Diagnostic Cytopathol* 1993; 9: 345–50.
 23. Prakash HM, Jyothi BL, Shankar SH, Kishanprasad HL, Ramswamy AS, Aravinda P. Aspiration biopsy cytology of solitary thyroid nodule. *NJBMS* 2011;1(3):150-3.
 24. Afroze N, Kayani N, Hasan SH. Role of fine needle aspiration cytology in the diagnosis of palpable thyroid lesions. *Indian J PatholMicrobiol.* 2002; 45(3):241-6. PMID: 12785159
 25. Sengupta A, Pal R, Kar S, Zaman FA, Sengupta S, Pal S. Fine needle aspiration cytology as the primary diagnostic tool in thyroid enlargement. *J Nat ScBiol Med* 2011; 2:113-8.
 26. Bukhari MH, Niazi S, Hanif G, Qureshi SS, Munir M, Hasan M, Naeem S. An updated audit of fine needle aspiration cytology procedure of solitary thyroid nodule. *DiagnCytopathol.* 2008;36 (2):104-12. doi: 10.1002/dc.20731. PMID: 18181183