

## PSEUDOHIRSCHSPRUNG'S DISEASE- A CLINICOPATHOLOGICAL CORRELATIVE STUDY

Sily Sreedharan<sup>1\*</sup>, Prema N S<sup>2</sup>

<sup>1</sup>Assistant Professor, Malabar Medical College, Calicut,  
<sup>2</sup>Additional Professor, Govt Medical College, Thiruvanthapuram

\*Corresponding Author:

E-mail: silysreedharan@rediffmail.com

### ABSTRACT

**Background:** *Intestinal obstruction in the neonate or infantile period poses problem in the management. The diagnosis and the management can be resolved by taking rectal biopsy and proving them as Hirschsprung's or Pseudohirschsprung's disease by histo-pathological examination. It helps in better patient management by avoiding unnecessary surgeries in cases of Pseudohirschsprung's disease.*

**Aim:** *To study the pathology of Pseudohirschsprung's disease and its staining pattern in immunohistochemistry with Neuron specific enolase (NSE) and S- 100.*

**Material & methods:** *Study included all cases with clinical diagnosis of Hirschsprung's disease, received in the department of pathology of a Govt. Medical college. Duration of study was 2 years from 2005-2007. A total of 90 cases were studied.*

**Results:** *Out of the 90 cases, 61(67.7%) were diagnosed as Hirschsprung's disease, 23 cases (25.60%) as Pseudohirschsprung's disease. Of the 23 cases of Pseudohirschsprung's disease, 7 cases showed hyperganglionosis, 7 cases showed hypoganglionosis and 9 cases showed normal ganglionic segment. Immunohistochemistry with NSE & S-100 in selected cases showed increased staining of sub mucosal nerve trunks.*

**Conclusion:** *One fourth of clinically diagnosed cases of Hirschsprung's disease were actually Pseudohirschsprung's disease. No definite IHC pattern could be clearly defined. Further studies are recommended for setting up standards for diagnosis of Pseudohirschsprung's disease, which will aid in better management of the cases.*

**Key words:** *Hirschsprung's Disease; Pseudohirschsprung's Disease; Rectal Biopsy*

### INTRODUCTION

The term Pseudohirschsprung's disease<sup>[1]</sup> is a clinical term which refers to patient who have apparent intestinal obstruction or severe chronic constipation in which ganglion cells are present in the rectal biopsy. These are broadly divided in to

1. Those with neural abnormalities: Intestinal Neuronal dysplasia.
2. Those with smooth muscle abnormalities.

Criteria for diagnosis of Pseudohirschsprung's disease were first laid down by Meier- Rugger<sup>[2]</sup> & later revised by Borchard<sup>[2]</sup> (TABLE-1). Usually Pseudohirschsprung's disease presents with same symptoms & radiological features as that of Hirschsprung's disease. Confirmation is by rectal biopsy which shows ganglionic segment in the case of Pseudohirschsprung's.

### AIM

To study the pathology of Pseudohirschsprung's disease and its clinicopathological correlation. To study the Immunohistochemistry staining pattern in Pseudohirschsprung's disease with Neuron specific enolase & S-100 in few selected cases.

### MATERIAL & METHODS

This study included all the cases received in the Department of Pathology, in a Gov. Medical College with clinical diagnosis of Hirschsprung's

disease. The study was conducted from May-2005 to Dec-2007, which included total of 90 cases. Appropriate clinical details, radiological findings including barium enema findings were also obtained. All specimens were categorized in to 2 groups.

1. Resected colectomy specimen
2. Biopsy: a) Sub mucosal biopsy b) Full Thickness biopsy.

The specimens were fixed in 10% formalin & anatomically oriented. The tissues in sub mucosal and full thickness biopsy were all embedded. Multiple sections were taken from representative areas in colectomy specimens. Tissue were processed, paraffin embedded & stained with H&E stain. Multiple serial sections were taken and studied. Histo-pathological findings were categorized in to

1. **Ganglionic Segment:** Presence of ganglion cells in intramural plexuses and Auerbach plexuses.
2. **Aganglionic Segment:** Absence of ganglion cells, but hypertrophied nerve bundles was noted.
3. **Transitional Zone:** Presence of both ganglion cells & hypertrophied nerve bundles in the intramural area.
4. **Material Inadequate:** Specimen in which intramuscular layer could not be visualized.

Those cases clinically diagnosed as Hirschsprung's disease with presence of ganglion cells and transitional zone findings in biopsy were discussed with the clinician, radio logically correlated & categorized in to pseudohirschsprung's disease. Such cases were further divided in to hypoganglionic, hyperganglionic & normal ganglionic depending on biopsy findings. Immuno- histochemistry for NSE & S-100 was done in selected cases using labeled streptavidin-biotin complex (LSAB) and DAB chromogen.

### OBSERVATION & RESULTS

A total of 90 cases were included with clinical diagnosis of Hirschsprung's disease. 23 cases out of 90 were categorized in to Pseudohirschsprung's disease (Fig-1). Out of the 23 cases, 7(30.4%) showed hypo ganglionosis (Fig-2), 7(30.4%) showed hyperganglionosis with 1 showing hyperganglionosis (Fig-3) and giant cells (Fig-4). Rest of the 9 cases showed normal ganglionic segments.

Most common age group was infants (77.7%) with male predominance of 2.5:1. Abdominal distension was the most common clinical presentation (37.7%).

Immunohistochemistry staining with NSE & S-100 in few cases of hypo ganglionic segment showed heavily stained sub mucosal nerve trunks, reduced size & number of ganglion cells & few fibers in muscularis mucosa propria (Fig-5). Hyper ganglionic segments showed increase in ganglion cells, larger in size with increase in nerve fibers in muscularis propria (Fig-6).

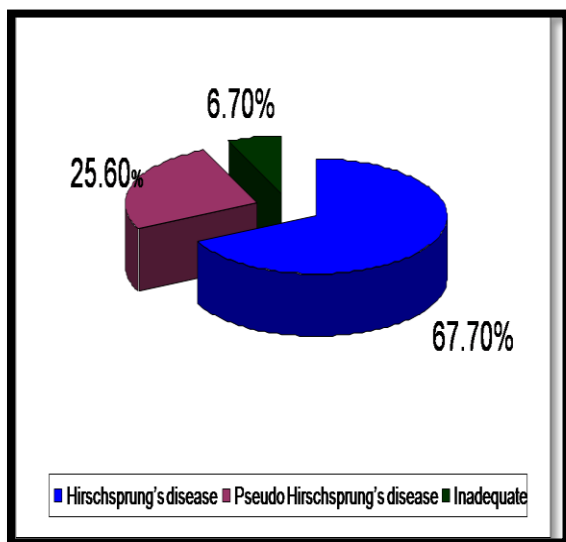


Fig 1: Distribution of Total Cases.

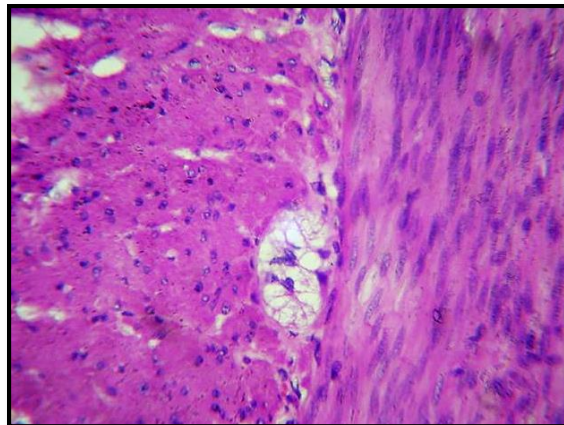


Fig. 2: H&EX400 Shows Hypo ganglionic Segment

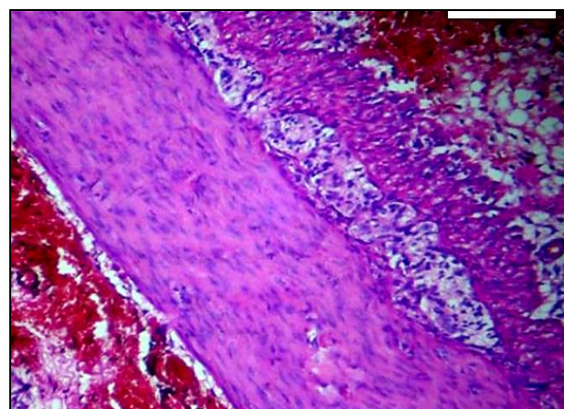


Fig. 3: H&Ex400 Shows Hyper ganglionic Segment

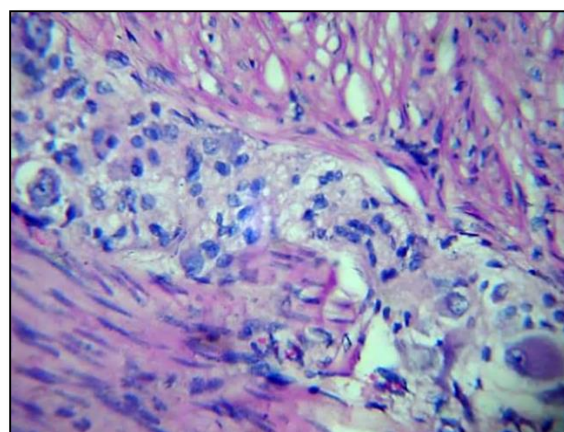
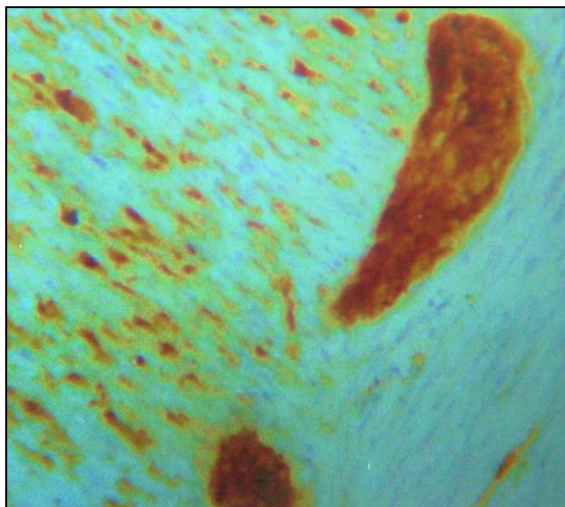
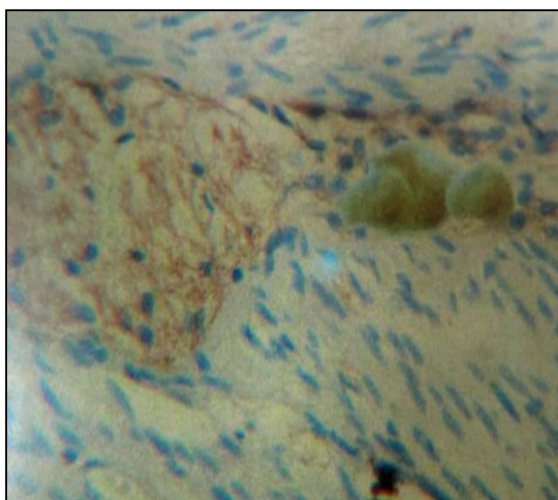


Fig 4: H&Ex400 Shows Hyper Ganglionic Segment with Giant Ganglion



**Fig 5: Nse – Shows Hypo ganglionic Segment With Hypertrophied Sub mucosal Nerve Trunks & In Myenteric Plexuses**



**Fig 6: S-100 Shows Hyperganglionic Segment with S-100 Positive Giant Gangli**

**Table 1: Meier Ruger Criteria for Intestinal Neuronal Dysplasia**

INTESTINAL NEURONAL DYSPLASIA- MEIER – RUGER CRITERIA
1. Hyperplasia of the submucosal & myenteric plexuses
2. Formation of giant ganglion
3. Proliferation of fine nerve fibers in lamina propria
4. Ectopic ganglia in the lamina propria & with in the muscularis propria

## DISCUSSION

Pseudohirschsprung's disease mimics Hirschsprung's disease clinically and radiologically. It is the histo-pathological study of the affected segment which helps in diagnosis and management, thus avoiding unwanted surgeries in such cases.

In our study, out of the 90 cases 23 (25.5%) were categorized in to Pseudohirschsprung's disease. The incidence of Pseudohirschsprung's disease varies from 0-22.5%<sup>[3,4]</sup> in different studies. Out of 23 cases, seven cases showed hypo ganglionosis; also termed as Intestinal Neuronal dysplasia, according to Nezelov & Meiger Ruge Criteria (Table-1). However all the cases could not fulfill all the criteria? There are no fixed criteria still in literature for diagnosis of Intestinal Neuronal Dysplasia. However Intestinal neuronal dysplasia have been classified in to type A & B.<sup>[5]</sup>

According to Bandyopadhyay<sup>[6]</sup> ganglioneuromatosis complex & giant ganglia were seen in 5 out of 9 cases, whereas our study showed only 1 such case. Weidel et al<sup>[2]</sup> reported 10 cases of hypoganglionosis; our study had seven such cases with reduced number & size of ganglion cells. Lake et al.<sup>[7]</sup> stated that majority of patients with Pseudohirschsprung's disease shows no morphological abnormality. There were 9 cases in our study which showed no morphological abnormality.

In case of Pseudohirschsprung's disease, no definite criteria or staining pattern have been described for immunohistochemistry, hence defining staining patterns in our study was also difficult. Ectopic ganglia characteristic of Intestinal Neuronal Dysplasia described by Meier Ruge<sup>[4]</sup> & Bandyopadhyay<sup>[6]</sup> were not seen in any of our cases. Giant ganglia noted in Bandyopadhyay studies were noted in only one case. However increased staining of muscularis mucosa & propria were noted in 5 cases of Pseudohirschsprung's disease comparable to the study of Borchard et al.<sup>[2]</sup>

## CONCLUSION

Some of the patients clinically diagnosed as Hirschsprung's disease are actually Pseudohirschsprung's disease, with rectal biopsy aiding in diagnosis. Further studies are recommended to set up a standard histological criteria and immunostaining patterns for the better understanding of disease and to avoid unnecessary surgeries in the affected children.

**REFERENCES**

1. Lynda G, B D Lake; Hirschsprung's disease & related disorders. *Pediatr. Surg.* 10 th ed; Vol-II, 535-538.
2. Dr. Smith V.V, Gregson N: Intestinal Neuronal density in child hood. A baseline for the objective assessment in hypo & hyperganglionosis. *Pediatr. Pathol.* 1993; 13:225-227.
3. Kobayashi H, Surana R: Intestinal neuronal dysplasia is a possible cause of persistent bowel symptoms after pull through. *J Pediatr Surg* 1995; 30: 253-259.
4. Smith VV, Milla, Casari, Brancholini: Intestinal pseudo obstruction in neonate caused by idiopathic muscle hypertrophy. *Histopathology* 1992;21:535-542.
5. Rintala R, Rapola J, Louhimo I: Neuronal Intestinal dysplasia. *Prog. Pediatr Surg* 24: 186-192, 1989.
6. Bandyopadhyay R, Chatterjee U, Basu AK: Intestinal Neuronal Disorder. A study of 7 cases. *Indian J Pathology Microbiology* 2004; 47(1): 4-7.
7. BD Lake, AE Nixon: Hirschsprung's disease & related disorders. *Text book of gastrointestinal pathology*, Vol-1(3): 327-338.