

A STUDY INTO IMMUNOFLOUORESCENCE PATTERNS OF PEMPHIGUS AND PEMPHIGOID AND CORRELATION OF INTENSITY OF FLUORESCENCE OF IMMUNOREACTANTS WITH THEIR SERUM LEVELS

Jyotsna Suri^{1,*}, Priya Gupta², Rita Kumari³

^{1,*}Associate professor, ^{2,3}Senior resident,
Department of pathology, Govt medical college jammu

***Corresponding Author:**

Email ID: jyotsnavivek_9@yahoo.co.in, jyotsnavivek9@gmail.com

ABSTRACT

Background: *Vesiculobullous disorders of the skin have well defined patterns of deposition of immunoglobulins (Ig) and complement, which can be demonstrated by immunofluorescence techniques, and help in making an accurate diagnosis of the same.*

Methods: *A clinicopathological study of 15 cases of vesiculobullous diseases diagnosed as Pemphigus and Pemphigoid was carried out. The study included six male patients and nine female patients. Light microscopy was done to see the level of cleavage of bullae and the diagnosis was further supported by direct immunofluorescence (DIF) findings. The correlation between intensity of fluorescence and the serum Ig & complement levels was studied.*

Result: *The patterns of deposition of immunoreactants were found to be in conformity with observations of the earlier studies and the Serum Ig & complement levels showed positive correlation with intensity of DIF positivity on skin biopsy.*

Conclusion: *Immunofluorescence has now been well established as a helpful technique in diagnosing bullous lesions which has a bearing on the treatment of these diseases which if not treated properly can prove fatal as a result of life threatening complications.*

Key Words: *Complement, Immunofluorescence, Immunoglobulin, Pemphigus, Pemphigoid.*

BACKGROUND

Immunofluorescence is a well-established immunohistochemical technique with a limitless capacity for detection of chemically specific material. It is a widely used tool in immunodermatology. In this, by the use of a specific antibody, subtle differences can be detected at the molecular level. Fluorescent markers such as fluorescein and rhodamine are used to detect combination of specific antibody with its particular antigen.^[1] This technique is sensitive and specific provided the appropriate technical parameters are observed, but they also have disadvantages inherent in the nature as lack of permanency of preparations and decay of fluorescence over time.

This technique was first used by Coons and his colleagues.^[2] In routine practice DIF is often used for examination of biopsy material from kidney, gut, skin and lymphoid tissue.

Bullous disorders of the skin have characteristic patterns of deposition of Ig & complement in epidermis & DEJ. The DIF findings of Pemphigus were defined by Beutner and Jordon in 1964^[3] whereas Civette and Tzanck ^[4] had outlined the histopathological criteria of intraepidermal splitting and acantholysis. The use of IF microscopy has proved to be of high diagnostic and prognostic value in these conditions and combined DIF and IDIF studies have completely restructured our concept of these immunologic diseases.^[5]

Vesiculobullous diseases present with blisters and vesicles involving widespread areas of skin. They can cause significant morbidity. When complicated by secondary infections and fluid loss, they can prove fatal. So they need to be diagnosed and treated in time. These conditions include pemphigus and pemphigoid, which have an immunological basis while others may be caused by non-immunologic mechanisms. The location of microscopic separation and

cleavage varies in different diseases. Line of investigation in such cases comprises of clinical examination, PBF, ESR, light and electron microscopy, DIF, IDIF and serum IgG and C3 level assays. The investigations help in differential diagnosis of similar appearing diseases which differ in their prognosis also.

AIMS AND OBJECTIVES

The study was undertaken for a period of one year with the objective of studying the staining pattern of pemphigus and pemphigoid on DIF and correlating the positive fluorescence with ESR, AEC, serum levels of Ig and C3.

MATERIALS AND METHODS

This study was carried out in the Department of Pathology Govt. Medical College Jammu in association with Department of Dermatology SMGSH and IIIM Jammu. Fifteen cases of vesiculobullous diseases clinically diagnosed as Pemphigus and pemphigoid were included in the study. These included newly diagnosed cases as well as previously diagnosed cases on treatment. A brief clinical and local examination of the patients along with investigations like Hb, PBF examination for TLC, AEC, ESR, Serum IgG, IgM, IgA, C3 level assays were done. Two skin biopsies were taken simultaneously. For routine light microscopy tissues were put in 10% solution of formalin, whereas for DIF, tissue was transported in PBS (pH 7.2). PBS was used as storage medium at -20° C upto 3-4 days whenever processing for DIF got delayed.

Elliptical biopsy was preferred because of better depth and inclusion of complete bulla without crushing and less chances of scarring. For light microscopy early lesions were preferred. Formalin fixed tissues were processed in auto-technicon, 4-6 micron sections were cut with microtome and collected on glass slides, precoated with eggalbumin. These sections were then dried for 45 min at 37° C and stained with H&E stain.

For DIF studies, biopsy was preferred from edge of blister, transported in ice cold

PBS (pH 7.2) and processed in cryostat. 5 micron sections were cut. 4-5 sections were taken on each of the 5 slides labeled as G, M, C, A and H&E respectively and were then stained as per method described in Bancroft^[6] using fluorescent conjugated antibodies (1:40 dilution) against IgG, IgM, IgA & C3. Interpretation of results was done as:

Bright Apple green fluorescence	
Positive	
Orange fluorescence	Auto
fluorescence	
No fluorescence	
Negative	

The slides were viewed immediately and relevant photographs of positive slides were taken. Interpretation of H&E slides: It was done depending on level of cleavage of bulla, changes in epidermis, abundance and type of inflammatory cells.

Interpretation of DIF antibody techniques included four main features:

1. Site of deposition of immunoreactant.
2. The class of immunoreactant.
3. The number of positive immunoreactants and if multiple the predominant immunoreactant.
4. Any deposits at sites other than the main lesion -perilesional area etc.

OBSERVATIONS

PEMPHIGUS

Total 10 cases of Pemphigus were diagnosed. 7 were of Pemphigus Vulgaris (PV), 1 of Pemphigus foliaceus (PF) & 2 cases in which sub typing of Pemphigus was not possible because of inadequate skin biopsy. These cases included 6 new and 4 old cases with relapse. Male: Female ratio was 2:3. Average age of patients was 40.2 years.

DIF showed intercellular staining pattern in 100% cases. Margins of acantholytic cells were showing apple green fluorescence in 70% cases diagnosed as PV. Band of fluorescence was seen at DEJ in 10% cases diagnosed as PF. Moderate to bright fluorescence positivity was seen in

new cases and weak to moderate positivity was seen in old cases. IgG was detected in 100% cases either alone or in combination with other immunoreactants like IgM, IgA, C3. In early untreated cases, C3 was often concomitantly bound usually to lower parts of epidermis and focally to areas where acantholytic process appeared to start. Complement was missing from the skin in patients already put on therapy.

The average values for various laboratory parameters were as shown in table 1. In old cases, value of ESR was appreciably increased varying from 38-50 mm 1st hr whereas newly diagnosed cases showed moderate increase in ESR varying from 20-30 mm 1st hr. Serum IgG was raised in half of the cases (4 new and 1 old case) & normal in half (including 2 new and 3 old cases). Serum C3 was raised in 60% cases (5 new and 1 old) and normal in the rest. Increased levels of IgG & C3 were seen more in newly diagnosed cases but were normal in

patients already put on treatment. These levels also showed correlation with clinical severity of the diseases. Cases with widespread/ generalized involvement had higher levels of serum IgG & C3 as compared to cases with eruption localized to face and scalp.

PEMPHIGOID

Final diagnosis of pemphigoid was given in 5 cases of bullous lesions in our study. These included 4 cases of bullous pemphigoid and one case of juvenile pemphigoid. 3 were newly diagnosed cases whereas 2 were old cases with fresh eruptions. DIF studies of normal appearing perilesional areas in these cases showed immune deposits of IgG & C3 in a linear continuous or interrupted granular band of fluorescence. 4 cases showed IgG & C3 deposits and one case showed only C3 deposits.

Average values of various laboratory parameters are as shown in Table 1

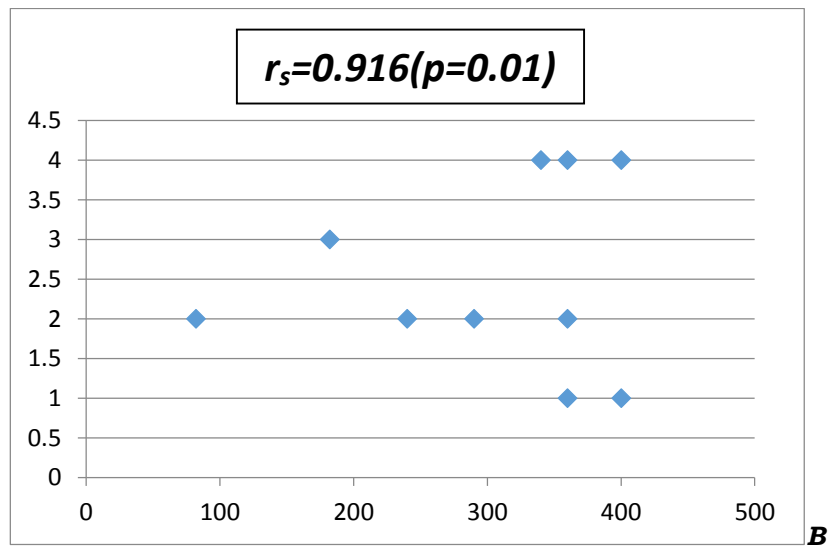
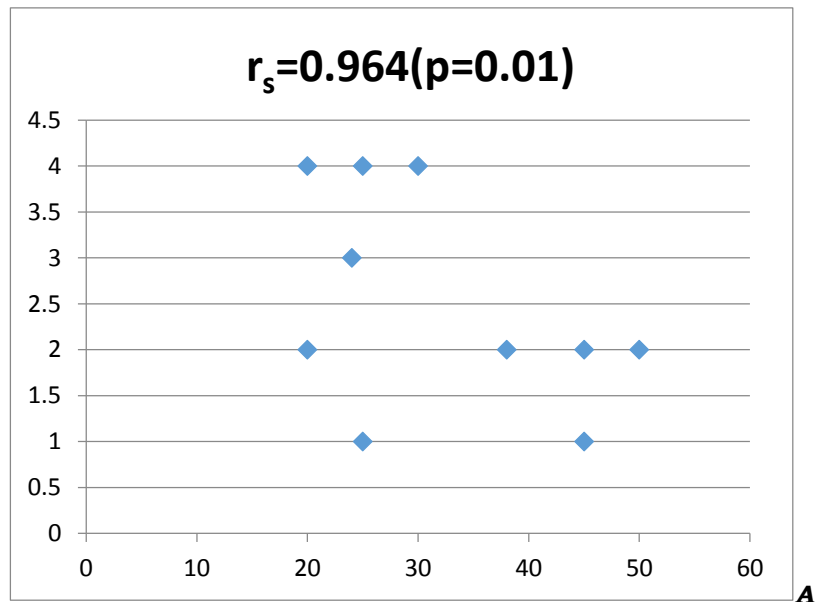
Table 1: Table showing the average values of various laboratory parameters in patients of pemphigus and pemphigoid.

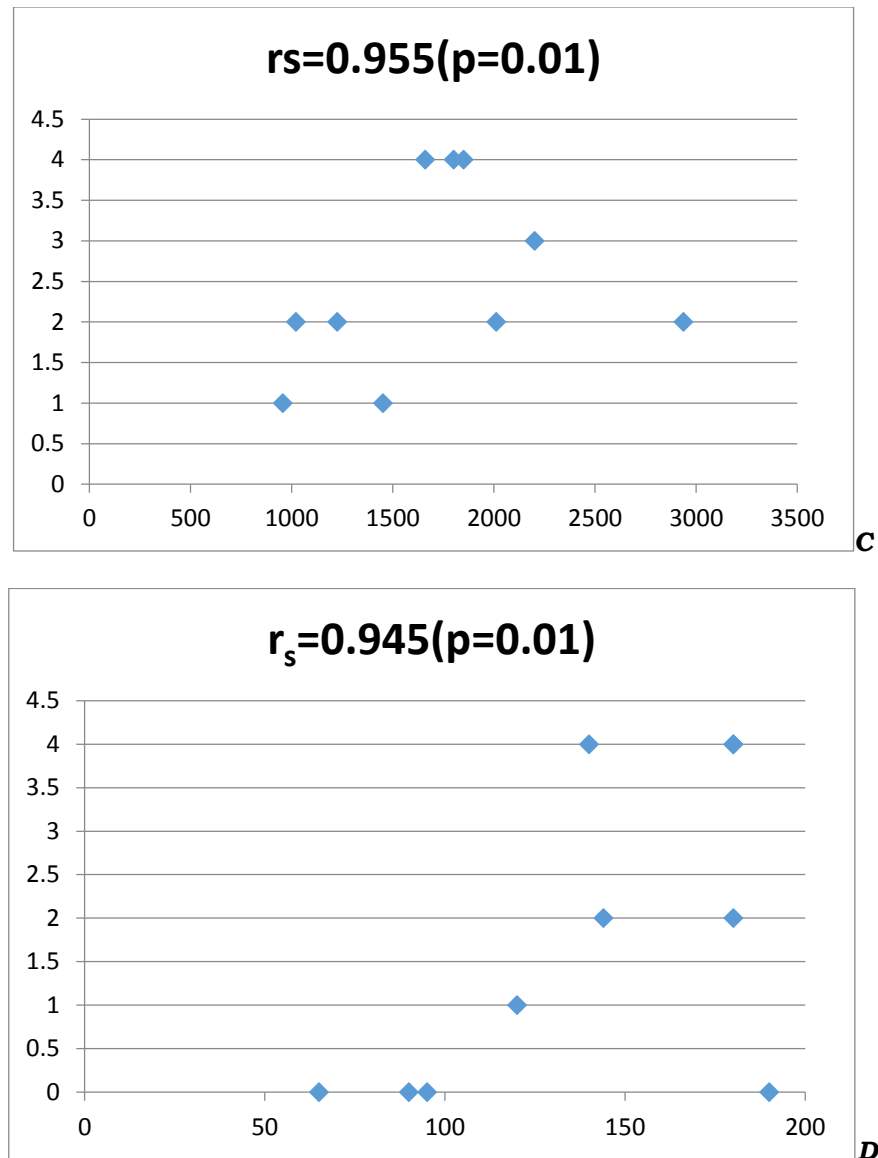
Parameter	Average values				Normal values ^[1,18]
	Pemphigus (new cases)	Pemphigus (old cases with relapse)	Pemphigoid (new cases)	Pemphigoid (old cases with relapse)	
Hb	9.13 gm% (±0.77)	8.77 gm% (±0.63)	7.5gm% (±1.32)	9.75 gm% (±0.35)	M:14.0-17.5gm% F:12.3-15.3 gm%
ESR	24 mm 1 st hr (±3.74)	44.5 mm 1 st hr (±4.93)	36.67 mm 1 st hr (±2.88)	42.50 mm/hr (±3.530)	M: 0-15 mm 1 st hr F: 0-20 mm 1 st hr
AEC	333 /cu mm (±77.63)	253/cu mm (±132.14)	515.34/ cu mm (±115)	307.5/cu mm (±116.67)	40-450/ cu mm
TLC	8750/cu mm (±880.34)	8300/cu mm (±476.09)	8867/ cu mm (±230.94)	8750/ cu mm (±353.55)	4000-11000 /cu mm
IgG	1828.33 mg/dl (±262.25)	1534.25 mg/dl (±941.51)	2066.33 mg/dl (±205.93)	1470 mg/dl (±381.83)	800-1700 mg/dl
IgA	127.5mg/dl (±24.44)	144 mg/dl (±45.28)	130 mg/dl (±31.22)	110 mg/dl (±14.14)	60-280 mg/dl
IgM	95.33 mg/dl (±14.16)	101.75mg/dl	100 mg/dl (±5)	100 mg/dl (±7.07)	80-490 mg/dl

		(±25.27)			
C3	155.83 mg/dl (±47.79)	112.25 mg/dl (±24.90)	160 mg/dl (±20)	90 mg/dl (±14.14)	55-122 mg/dl

In all new cases ESR was increased. Serum IgG & C3 levels were also raised. In old cases, previously treated for pemphigoid, ESR was moderately increased signifying chronicity of the lesion. Only one old case with relapse showed mild increase in value of serum IgG.

Spearman's Coefficient (r_s) indicated significant correlation between ESR, AEC, Serum IgG, C3 levels on one hand and intensity of DIF positivity on the other hand for all the cases of Pemphigus and Pemphigoid [Figure 1, Figure 2].



**FIG. 1****FOR CASES OF PEMPHIGUS**

Scatter diagram showing correlation of

A-ESR(mm/hr) with intensity of IgG DIF Positivity,

B- AEC(/cumm) with intensity of IgG DIF Positivity ,

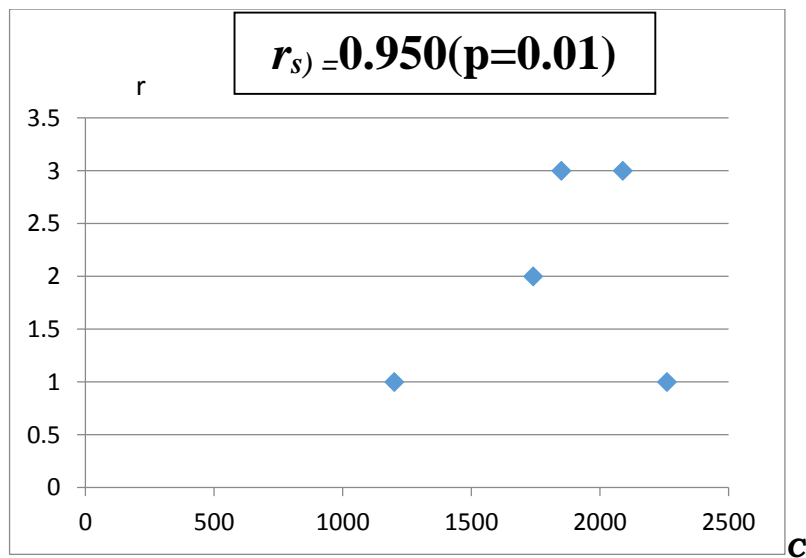
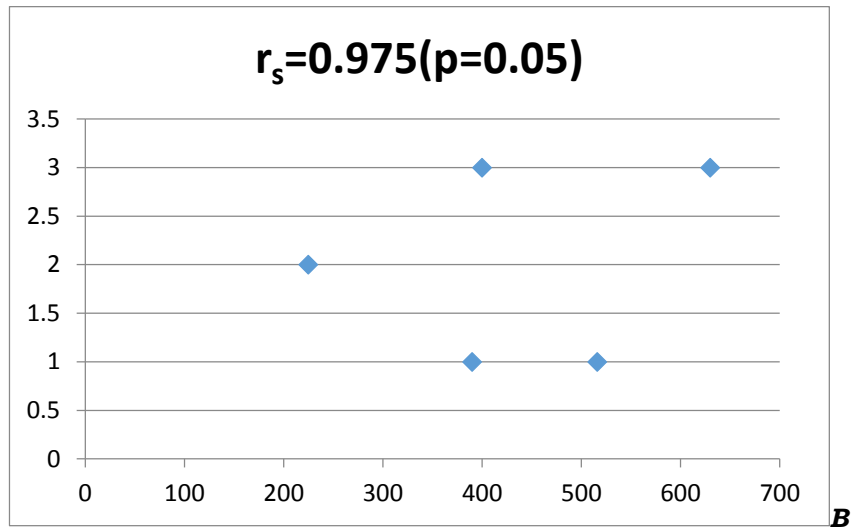
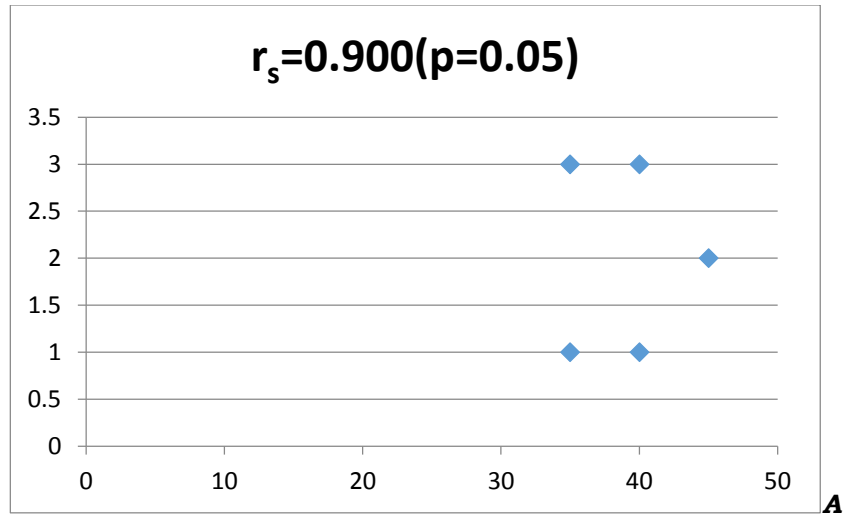
C-Serum IgG(mg/dl) with intensity of IgG DIF Positivity &

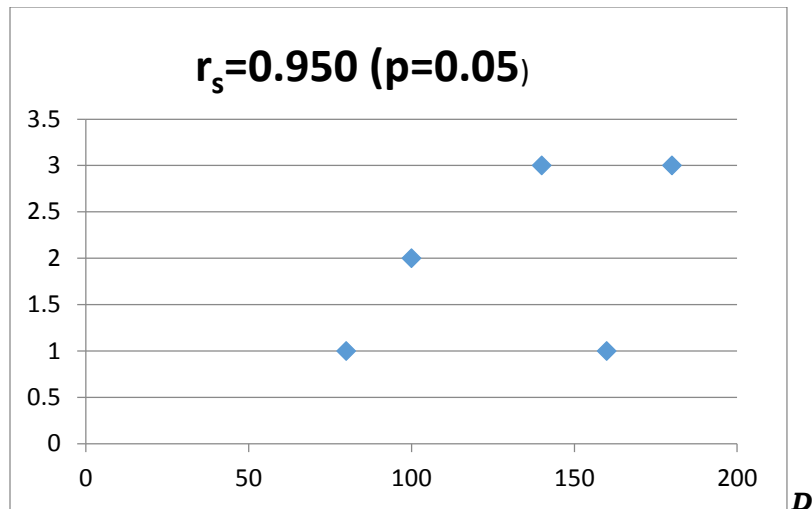
D- Serum C3 levels(mg/dl) with intensity of C3 DIF Positivity]

ESR, AEC ,Serum IgG & C3 levels are on X axis & intensity of DIF Positivity is on Yaxis

1 ,2, 3, 4 represent +,++,+++,++++

r_s denotes SPEARMAN's Coefficient



**FIG. 2****FOR CASES OF PEMPHIGOID**

Scatter diagram showing correlation of

A-ESR(mm/hr) with intensity of IgG DIF Positivity,

B- AEC(/cumm) with intensity of IgG DIF Positivity ,

C-Serum IgG(mg/dl) with intensity of IgG DIF Positivity &

D- Serum C3 levels(mg/dl) with intensity of C3 DIF Positivity]

ESR, AEC ,Serum IgG & C3 levels are on X axis & intensity of DIF Positivity is on Yaxis

1 ,2, 3, 4 represent +, ++, +++, +++++

r_s denotes SPEARMAN's Coefficient

DISCUSSION

The role of DIF in differential diagnosis and prognosis of vesiculobullous diseases is already established.^[7,8,9] The positive predictive value of DIF in the diagnosis of pemphigus is extremely high and approaches 100%. The negative predictive value is 85% to 90%. In patients with subepidermal bullous diseases, the positive and negative predictive values of DIF approach 100%. False-negative results may occur secondary to technical error (extremely rare) or poor sampling (biopsy specimen from inflamed or bullous lesions).^[10] The present study was carried out to study DIF staining pattern of patients with vesiculobullous diseases coming to dermatology OPD of GMC Jammu, to help in their further treatment and also to establish correlation of intensity of DIF positivity with ESR, AEC, Serum Ig G, C3 levels.

The DIF positivity in cases of Pemphigus was observed as apple green fluorescence around individual keratinocyte, both in cell margins of acantholytic cells in bullous cavity as well as intercellular areas of normal adjoining skin [Figure 3,4]. In one case diagnosed as PF, fluorescence was also seen at basement membrane zone. This pattern has been well documented in the literature.^[11] We observed IgG positivity in 100% cases of Pemphigus, IgM positivity in 40% cases, IgA positivity in none, C3 positivity in 60% cases. 66.73% new cases were positive for C3 as compared to old cases where it was seen in only 50% cases. Intensity of fluorescence was brighter in newly diagnosed cases as compared to old cases. These findings were in conformity with observations of David M et al.^[12]

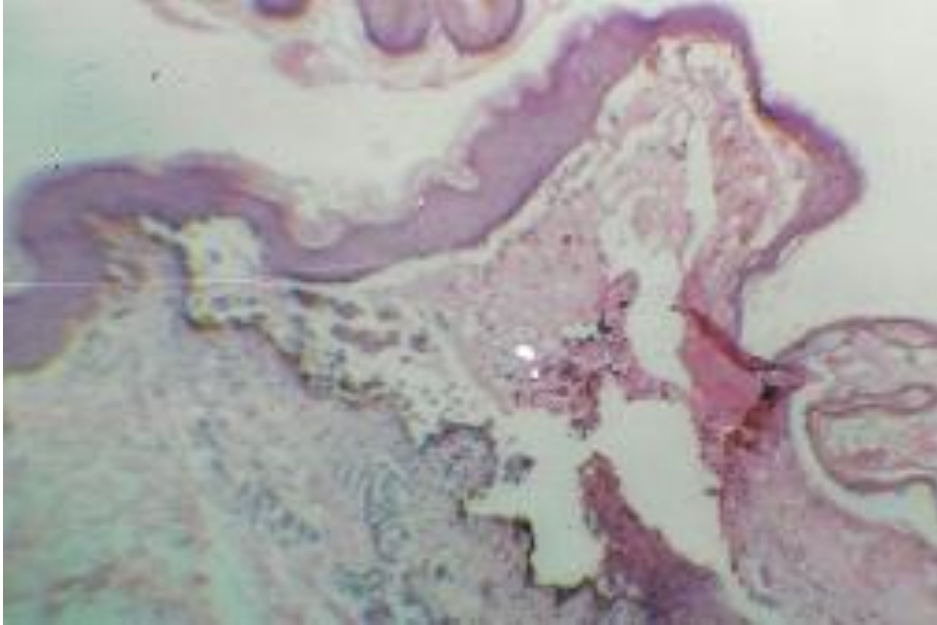


Figure 3: H&E Staining shows an acantholytic cleft separating upper part of epidermis from basal row of keratinocytes .(low power view)

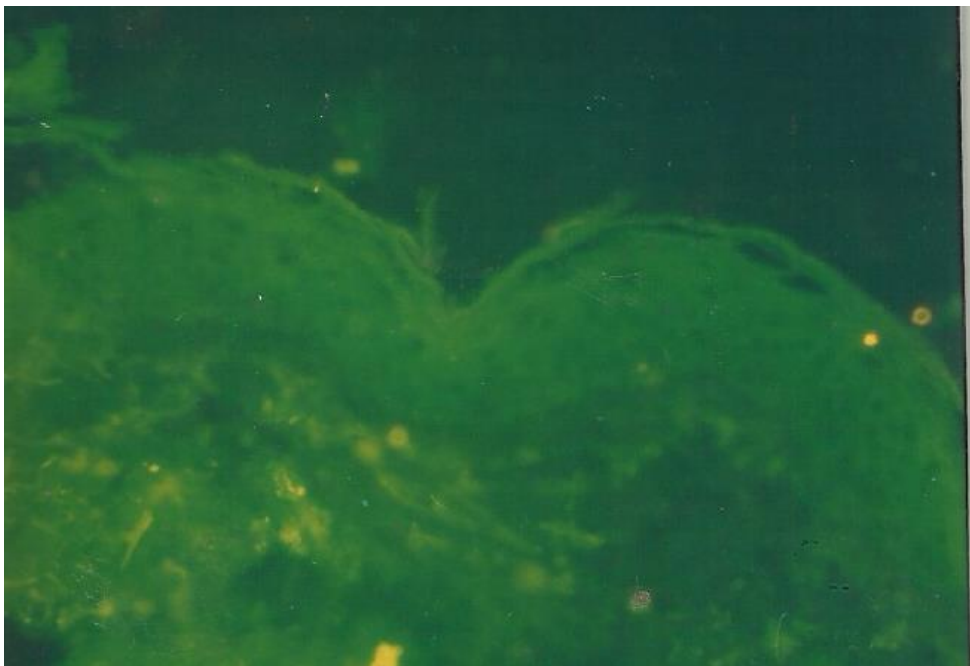


Figure 4: DIF of Perilesional skin stained with FITC anti IgG antibody

On comparison of our study with previous studies we concluded that IgG positivity is seen in 100% cases of pemphigus with active disease in ICS & around acantholytic cells & this is now considered as a diagnostic criterion for pemphigus.^[10] C3 positivity is more in cases with active disease as compared to cases in clinical remission. This observation highlights the possible role of C3 in

pathogenesis of pemphigus. David M et al.^[12] have also emphasized that C3 may have a predictive role in prognosis. Our study included one case of PF which showed sub corneal bulla on HPE and fluorescence positivity for IgG at ICS & DEJ. DEJ fluorescence may be due to development of secondary changes in the lesion. Increase in serum IgG levels was appreciably increased in new cases with active disease as

compared to old cases. These observations were in conformity with the observations of Tuffanelli DL^[13] and supported positive correlation of serum IgG with severity of the disease. Serum C3 levels were also increased in six out of ten cases. Our observations supported observations of Tuffanelli DL et al^[14] & David M et al^[12] that serum IgG & C3 levels show a positive correlation with activity of disease.

Out of 5 cases of Pemphigoid (4 cases of BP, 1 case of Juvenile pemphigoid) IgG positivity was seen in 80% cases & C3 positivity was seen in 100% cases [Figure

5,6]. Fluorescence was intense and bright in new cases as compared to old cases. Similar findings have been reported in earlier studies.^[3,15] Tuffanelli^[13] in his study demonstrated deposits of IgG at DEJ in 60 out of 67 cases of BP. Rest seven cases were either treated or inactive. He emphasized that immunopathological studies of the biopsy material are more sensitive diagnostically than serological studies and are positive in 90% of the cases. This pointed to the importance of DIF staining in BP as a diagnostic aid in the absence of circulating antibodies.

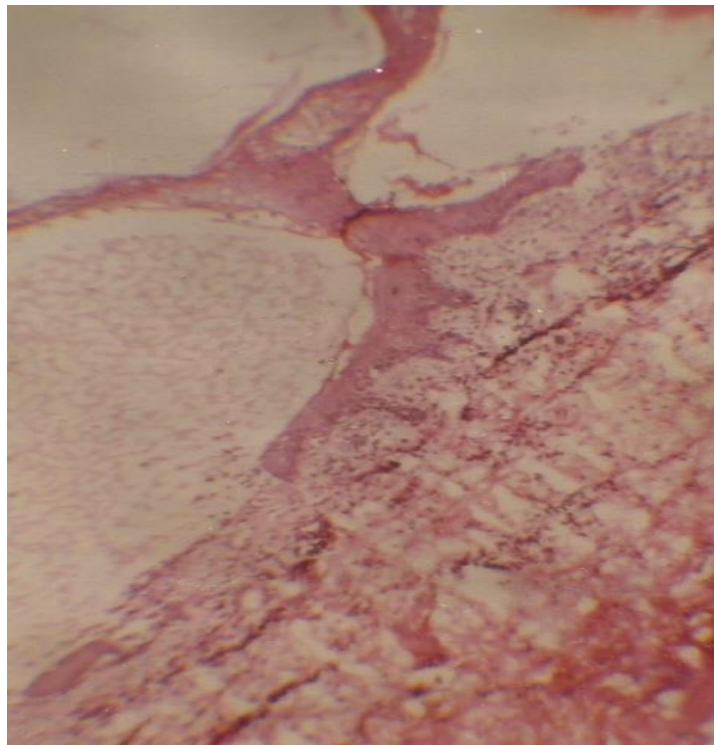


Figure 5: Bullous Pemphigoid : Subepidermal blisters with one edge showing regeneration of epidermis at the floor of bulla

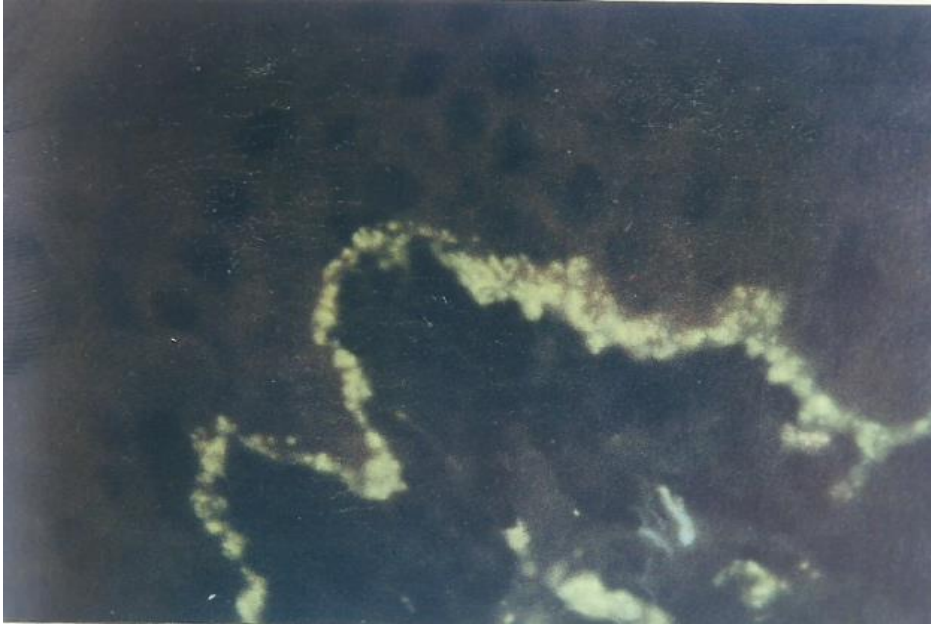

Figure 6: DIF of lesional skin biopsy showing distinct granular fluorescence in the DEJ with FITC anti IgG

Anhalt^[16] in his review article quoted WR Gammon for stressing on proper biopsy technique and site for carrying out DIF in cases in cases of pemphigoid. He said that the best specimens for DIF studies in patients of pemphigoid are obtained from perilesional skin or urticarial, unblistered skin. In his study, IgG and C3 positivity was detected in 90% and 100% of the cases respectively. He stressed upon the observation that linear deposits of IgG and C3 are not specific for BP and are also seen in CP, HG, EBA, Bullous SLE. So, definite diagnosis of BP requires corroboration of DIF studies with light microscopic findings.

Serum values of IgG and C3 were increased in new cases with active disease and showed correlation with activity of the disease and intensity of fluorescence. Single case of juvenile pemphigoid diagnosed in our study showed bright IgG positivity as linear continuous band at the BMZ which was similar to other studies.^[17]

CONCLUSION

The vesiculobullous diseases of skin may have overlapping clinical and histological features. DIF studies are a valuable diagnostic tool in dermatology practice and provide information about

diagnosis and prognosis of the disease. DIF is helpful in confirming a suspected diagnosis or in distinguishing among closely related diseases particularly when histopathology fails to give much information about the level of cleavage of bullae, type of inflammatory infiltrate and thus it reduces the spectra of clinical possibilities and helps in proper management of these patients.

LIST OF ABBREVIATIONS

AEC: absolute eosinophil count
 BMZ: basement membrane zone
 BP: bullous pemphigoid
 CP: cicatricial pemphigoid
 DEJ: dermoepidermal junction
 DIF: direct immunofluorescence
 EBA: epidermolysis bullosa acquisita
 ESR: erythrocyte sedimentation rate
 Hb: haemoglobin
 HG: herpes gestationalis
 H&E: hematoxylin and eosin
 ICS: intercellular space
 IDIF: indirect immunofluorescence
 PBF: peripheral blood film
 PBS: phosphate buffer saline
 PF: pemphigus foliaceus
 PV: pemphigus vulgaris
 SLE: systemic lupus erythematosus
 TLC: total leukocyte count

References:

1. Colvin RB, Bhan AK, McCluskey RT: *Diagnostic immunopathology*. 2nd edition. New York. Raven Press; 1995.
2. Maciejewski W :Annular erythema as an unusual manifestation of chronic Disseminated lupus erythematosus.*Arch Dermatol* 1980, 116(4): 450-453
3. Beutner EH, Jordan RE, Chorzelski TP: The immunopathology of pemphigus and bullous pemphigoid.*J Invest Dermatol* 1968 ,51(2):63-80
4. Marsden RA, Mckee PH, Bhogal B et al: "A study of benign chronic bullous dermatosis of childhood and comparison with dermatitis herpetiformis and bullous pemphigoid occurring in childhood."*Clinical and experimental dermatology* 1980, 5 : 159-172.
5. Beutner EH, Chorzelski TP, Kumar V: *Immunopathology of the Skin*. 3rd edition. New York. Wiley; 1987.
6. Carlton SJ. Immunofluorescent techniques. In *Theory and practice of histological techniques*. 5th edition. Edited by Bancroft JD, Gamble M. Churchill Livingstone 2002: 579-591.
7. Inchara YK, Rajalakshmi T : Direct immunofluorescence in cutaneous vesiculobullous lesions. *Indian J Pathol Microbiol* 2007,50(4):730-2.
8. Arbache ST, Nogueira TG, Delgado L, Miyamoto D, Aoki V: Immunofluorescence testing in the diagnosis of autoimmune blistering diseases: overview of 10-year experience. *An Bras Dermatol* 2014, 89(6):885-9
9. Pohla-Gubo G, Hintner H. Direct and indirect immunofluorescence for the diagnosis of bullous autoimmune diseases.*Dermatol Clin*2011,29(3):365-72
10. Mutasim DF, Adams BB. Immunofluorescence in dermatology.*J Am Acad Dermatol* 2001,45:803-22.
11. Muramatsu T, Shirai T, Sakamoto K, Ikeda S, Ogawa H. Pemphigus foliaceus with anti-intercellular and anti-basement membrane zone antibodies. Blocking immunofluorescence and Western immunoblotting studies.*Dermatologica* 1988,177(6):354-9
12. David M, Katzenelson V, Hazaz B, Ben-Chetrit A, Sandbank M: Determination of IgG subclasses in patients with pemphigus with active disease and in remission. *Archives of dermatology*1989,125(6): 787-790.
13. Tuffanelli, DL: Cutaneous immunopathology: Recent observations.*J Invest Dermatol* 1975, 65: 143-153
14. Tuffanelli DL, Kay D, and Fukuyama K. Dermal-epidermal junction in lupus erythematosus.*Arch Dermatol* 1969, 99: 652-662
15. Jordan RE, Triftshauser CT, Schroeter AL: Direct immuno- fluorescent studies of pemphigus and bullous pemphigoid. *Arch Dermatol* 1971,103:486-91
16. Anhalt GJ: Pemphigoid. Bullous and cicatricial. *Dermatol Clin* 1990 ,8(4):701-16.
17. Gajic-Veljic M, Nikolic M, Medenica L: Juvenile bullous pemphigoid: the presentation and follow-up of six cases.*J Eur Acad Dermatol Venereol* 2010, 24(1):69-72
18. Mc Pherson RA, Pincus MR. *Henry's clinical diagnosis and management by laboratory methods 21st edition*. Elsevier 2007