



## PEDIATRIC UROLOGY CASE REPORTS

ISSN: 2148–2969

Journal homepage: <http://www.pediatricurologycasereports.com>

## Megameatus with intact prepuce (MIP) hypospadias variant applied tubularized incised plate (TIP) urethroplasty: A rare case report

**Bahattin Aydogdu, Mehmet Hanifi Okur, Hikmet Zeytun, Selcuk Otcu***Department of Pediatric Surgery, Faculty of Medicine, Dicle University, Diyarbakir, Turkey*

**Abstract** A megameatus with intact prepuce (MIP) is an unusual variant of an anterior hypospadias that accounts for 3% of hypospadias repairs. It is characterized by a widely splayed coronal or subcoronal meatus, a deep glanular groove, a normally conformed prepuce, and no chordee. In this case, good cosmetic and functional outcomes, such as achievement of a straight urine stream and patient satisfaction, were achieved using the tubularized incised plate (TIP) procedure. However, each case of MIP is unique, and a suitable procedure should be tailored to individual cases.

**Keywords** Megameatus; tubularized incised plate (TIP); urethral reconstruction.

*Copyright © 2015 pediatricurologycasereports.com.*

**Corresponding Author:** Mehmet Hanifi Okur, M.D.,

*Department of Pediatric Surgery, Faculty of Medicine,  
Dicle University, Diyarbakir, Turkey*

*E mail: [mhanifi-okur@hotmail.com](mailto:mhanifi-okur@hotmail.com)*

*Accepted for publication: 15 October 2015*

### INTRODUCTION

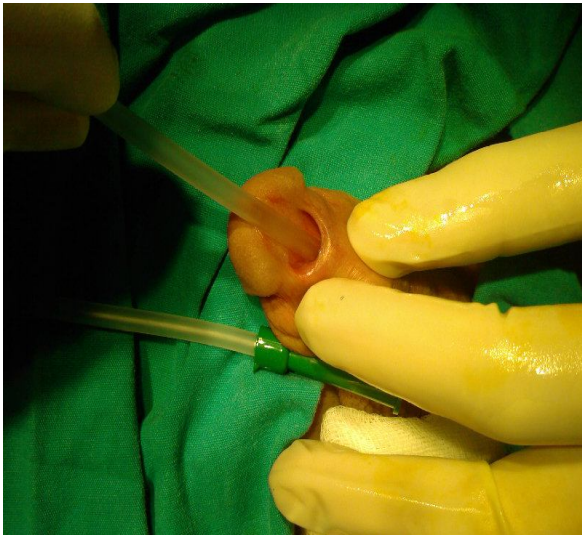
A megameatus with intact prepuce (MIP) is an unusual variant of an anterior

hypospadias that accounts for 3% of hypospadias repairs [1,2]. Duckett and Keating first described MIP in 1989 [3]. It is characterized by a widely splayed coronal or subcoronal meatus, a deep glanular groove, a normally conformed prepuce, and no chordee [1–3]. Additionally, there is a deficiency of spongiosum, resulting in thin

and relatively immobile tissue on the ventral portion of the urethral meatus [4]. Hence, surgical reconstruction of MIP has distinct challenges. There is usually no effect on the micturition or sexual physiology [4]. Several technical approaches are used for MIP reconstruction, including the glanular approximation procedure (GAP), the pyramid procedure, and tubularized incised plate (TIP) urethroplasty [3,5,6].

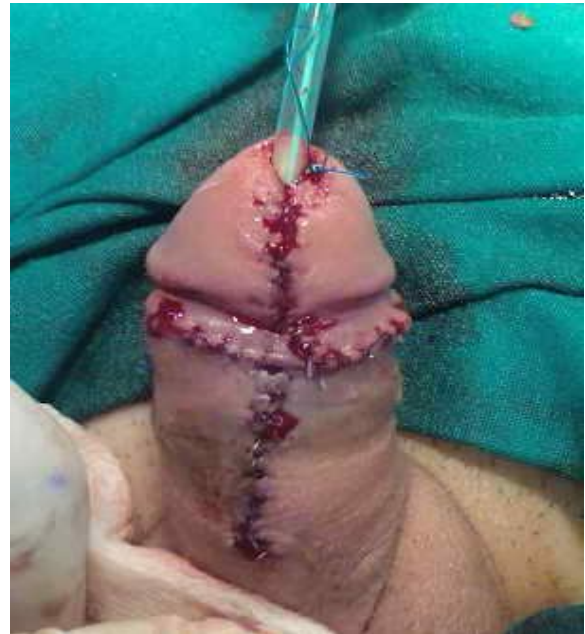### CASE REPORT

An 8-year-old boy presented with MIP. He had undergone ritual neonatal circumcision, and his parents reported that the prepuce appeared normal before the circumcision. The meatus was coronal (Fig. 1).



**Fig. 1.** Megameatus intact prepuce (MIP) variant of hypospadias in an 8-year-old boy, with the characteristic wide mouth coronal meatus.

A TIP urethroplasty technique was performed using magnification loupes, needle tip cautery, and 6–7/0 polyglactin absorbable sutures (Fig. 2). The silicone stent was removed 7 days after surgery.



**Fig. 2.** Appearance after surgery.

The urethral meatus was positioned near the tip of the glans penis, and there was no evidence of meatal stenosis or urethrocutaneous fistula. Satisfactory cosmetic and functional results were achieved in this patient.

### DISCUSSION

The incidence of MIP has been reported as approximately 1 in 10,000 or 1–3% of patients with hypospadias; however, the condition may be even more common [3].

The embryological origins of MIP is unclear, but it appears to be a variant of megalourethra [7,8]. As most patients are circumcised, the penile skin is usually thin and scarred. A dissection of the wide meatus and urethral plate may result in thin glanular wings that are more prone to dehiscence and urethral fistula formation [6,9]. It has no effect on micturition or sexual physiology. Its appearance, however, may disturb a child's psychology, and cosmetic remodeling is usually indicated.

Techniques of hypospadias and megameatus repair have improved significantly during the past two decades. In the repair of megameatus, it is important to recognize the full extent to which the distal urethra is widened to avoid inadvertent urethrotomy during mobilization of the glans wings and skin immediately proximal to the glans [4]. Nonomura et al. [10] reported satisfactory cosmetic and functional results using perimeatal-based flaps in previously circumcised patients. Similarly, other authors have used the meatal advancement and glanuloplasty (MAGPI) technique in distal glanular MIP and with the GAP technique for the remaining glanular defects with equally good results [11,12]. In a series reported by Bar Yosef et al. [6], they presented their experiences in 24 patients with MIP variant and their approaches to the

surgical management, including the MAGPI, GAP, and TIP urethroplasty techniques. They believed that the suitable procedure for each patient should be tailored according to the location of the meatus and the anatomic features; no single technique is appropriate for all cases and variants of MIP hypospadias. Additionally, they suggested that TIP urethroplasty could be successfully used in the more severe, proximal forms of MIP. In a case report, Faasse et al. [4] suggested the need for a strategy to restore normal anatomy during the repair of megameatus, incorporating aspects of the pyramid and TIP urethroplasty techniques in a modified, patient-specific approach.

In this case, good cosmetic and functional outcomes, such as achievement of a straight urine stream and patient satisfaction, were achieved using the TIP procedure. However, each case of MIP is unique, and a suitable procedure should be tailored to individual cases.

## Acknowledgements

The author(s) declare that they have no competing interests and financial support.

## REFERENCES

1. Juskiewenski S, Vaysse P, Guitard J, Moscovici J. Treatment of anterior hypospadias. Place of balanoplasty. *Chir Pediatr*. 1983;24(1):75–9.
2. Attalla MF. Subcoronal hypospadias with complete prepuce: a distinct entity and new procedure for repair. *Br J Plast Surg*. 1991;44(4):122–5.
3. Duckett JW, Keating MA. Technical challenge of the megameatus intact prepuce hypospadias variant: the pyramid procedure. *J Urol*. 1989; 141(6):1407–9.
4. Faasse MA, Dray EV, Cheng EY. Repair of megameatus: a modified approach. *J Pediatr Urol*. 2015;11(2):100–1.
5. Zaontz MR. The GAP (glans approximation procedure) for glanular/coronal hypospadias. *J Urol*. 1989;141(2):359–61.
6. Bar-Yosef Y, Binyamini J, Mullerad M, Matzkin H, Ben-Chaim J. Megameatus intact prepuce hypospadias variant: application of tubularized incised plate urethroplasty. *Urology*. 2005;66(4):861–4.
7. Duckett JW. Hypospadias. In Campbell MF, Walsh PC and Retik AB (Eds.), *Campbell's Urology*, 7th Ed. Philadelphia: Saunders, 1998. Pp. 2093–2119.
8. Peretz D, Westreich M. Pseudo-iatrogenic hypospadias: the megameatus intact-prepuce hypospadias variant. *Plast Reconstr Surg*. 2003;111(3):1182–5.
9. Hill GA, Wacksman J, Lewis AG, Sheldon CA. The modified pyramid hypospadias procedure: repair of megameatus and deep glanular Groove variants. *J Urol*. 1993; 150(4):1208–11.
10. Nonomura K, Kakizaki H, Shimoda N, Koyama T, Murakumo M, Koyanagi T. Surgical repair of anterior hypospadias with fish-mouth meatus and intact prepuce based on anatomical characteristics. *Eur Urol*. 1998;34(4):368–71.
11. Pieretti RV, Pieretti A, Pieretti-Vanmarcke R. Circumcised hypospadias. *Pediatr Surg Int*. 2009;25(1):53–5.

12. Elbatarny AM, Shehata SM, Ismail KA. Megameatus intact prepuce variety of hypospadias:tips for repair using the modified glanular approximation procedure. Annals of Pediatric Surgery 2011;7(2):82-7.

**Access this article online**

<http://pediatricurologycasereports.com>

**Quick Response Code**

