



## Bilateral large congenital periureteral bladder diverticula in a child:

### A case report

Hulya Ozturk<sup>1</sup>, Emine Dagistan<sup>2</sup>, Gulzade Ozyalvacli<sup>3</sup>

<sup>1</sup>Department of Pediatric Surgery, Abant İzzet Baysal University, Medical School, Bolu, Turkey

<sup>2</sup>Department of Radiology, Abant İzzet Baysal University, Medical School, Bolu, Turkey

<sup>3</sup>Department of Pathology, Abant İzzet Baysal University, Medical School, Bolu, Turkey

#### Abstract

Congenital bladder diverticula (CBD) are an outpouching of the mucosa through the muscular wall of the bladder. Large CBD may be presented with a serious urological problem in childhood. A 6-year-old boy was admitted with the complaint of recurrent urinary tract infection and urinary retention. Voiding cystourethrogram revealed a bilateral large CBD. Cystoscopy was performed before surgery to rule out bladder neck pathology, for direct visualization of diverticula, and to see the opening of the ureters. Transvesical diverticulectomy is a reliable technique for surgical treatment, if necessary, and can effectively be combined with the management of associated other pathology.

**Key Words** Bladder diverticulum; congenital; child; diverticulectomy.

Copyright © 2015 [pediatricurologycasereports.com](http://www.pediatricurologycasereports.com).

**Corresponding Author:** Hulya Ozturk, M.D.

Department of Pediatric Surgery, Abant İzzet Baysal University Medical School, Bolu, Turkey

E mail: [hulya\\_ztrk@yahoo.com](mailto:hulya_ztrk@yahoo.com)

Accepted for publication: 26 August 2015

#### INTRODUCTION

Congenital bladder diverticula (CBD) are revealed by mucosal and submucosal

herniation through the muscular wall of the urinary bladder [1,2]. CBD are not commonly found in children – an incidence of 1.7% was reported in a series of cases diagnosed by voiding cystourethrogram (VCUG) [3] – but when they are found, they are seen more commonly in boys, with a predominance of 9:1 [4,5]. The exact

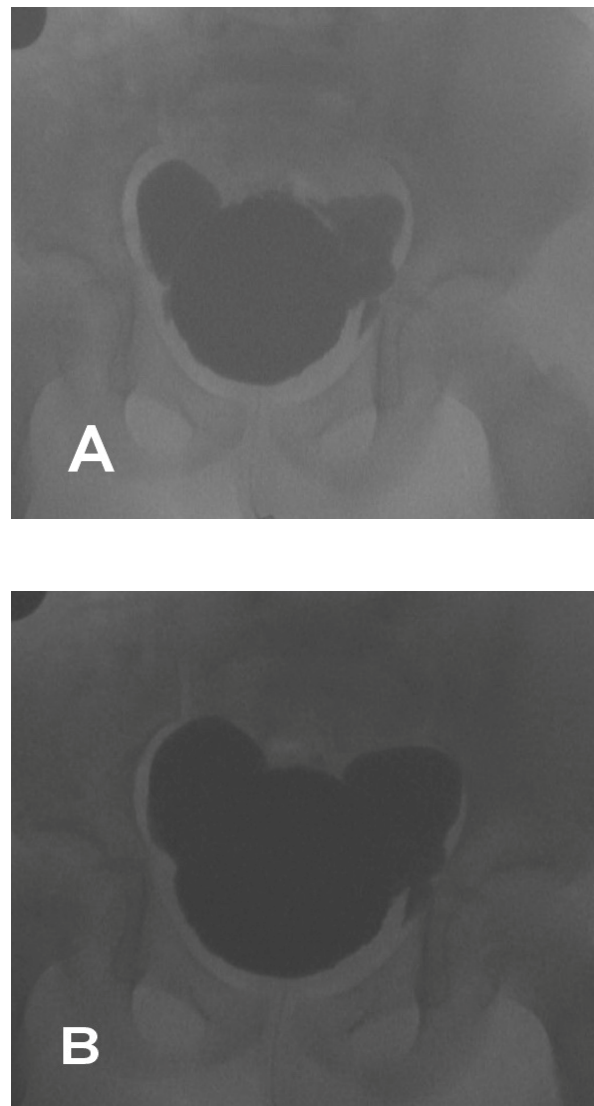
etiology of CBD is not known, but they are thought to be formed by a primary defect in the Waldeyer fascia, which may be combined with an intrinsic weakness in the bladder wall [1,6,7]. Diverticula are often asymptomatic and discovered accidentally during an examination for other health problems [3,8]; however, some patients may present with urinary tract infections, obstructions, hematuria, gallstones, dysfunctional voiding and frequent voiding [5,8,9]. Most CBD can be found in single, unilateral, and paraureteral/posterolateral locations [9]. The second most frequent cases are double diverticula, which are rarely found in the nonobstructive polydiverticular bladder [7].

In this case, we present an experience in the clinicopathology and management of bilateral large CBD.

### CASE REPORT

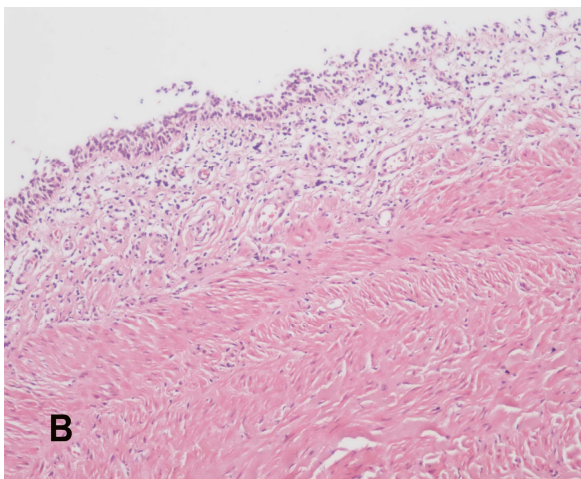
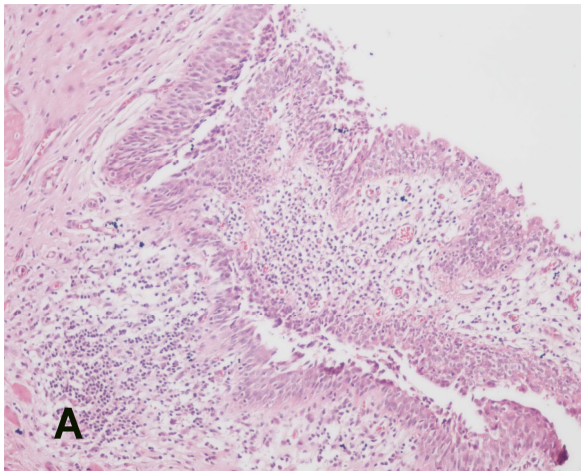
A 6-year-old boy presented with a history of recurring urinary tract infections and urinary retention. His renal function test results were normal, and his renal ultrasound was normal. VCUG findings showed large bilateral CBD with no vesicoureteral reflux (VUR) (Fig. 1A,B). An urethrocytoscopy was performed before surgery to rule out bladder neck pathology, for direct visualization of diverticula, and to see the

opening of the ureters. At the urethrocytoscopy phase, we visualized the left and right large bladder diverticula located above and lateral to the ureteral meatus. The bilateral diverticulectomy was achieved by intravesical dissection.



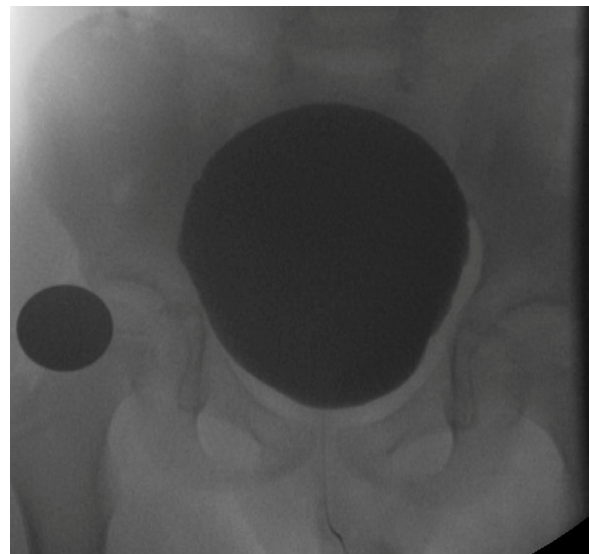
**Fig 1.** A, B. Voiding cystourethrogram demonstrates a right and left large bladder diverticulum.

During the histopathology examinations of the tissues, in the majority of the diverticulum areas were seen a loss of the muscularis propria layer. There were chronic inflammation in lamina propria and variable degrees of smooth muscle hypertrophy under the mucosa adjacent to the diverticula (Fig. 2A, B).



**Fig. 2.** (A) Mucosa covered with transitional epithelium herniating to the bladder wall and moderate chronic inflammatory cell infiltration in lamina propria (H/E, x100). (B) Prominent smooth muscle hypertrophy under the mucosa adjacent to the diverticula (H/E, x100).

The patient's 3-month postoperative VCUG results were normal (Fig. 3).



**Fig. 3.** Postoperative voiding cystourethrogram demonstrates normal bladder.

### DISCUSSION

Bladder diverticula may be congenital, acquired, or iatrogenic. CBD are not frequently found in children [7,10], but are more often found in males. In this pathology, the patient's detrusor layer may have been either abnormally thin or only partially developed, allowing for the outpouching of the bladder mucosa through the inadequate muscularis wall [6,11,12]. Kelalis described it as a bladder protrusion with a diameter of greater than 2 cm [13]. The relationship between the ureter and the diverticula may be changed. Approximately 90% of CBD occur in areas where the

Waldeyer's sheath covers the space between the intravesical ureter and detrusor, which explains the common association between the CBD and ureteral orifice [8,14]. A diverticulum involving the ureteral orifice is called a paraureteral diverticulum; a diverticulum with a separate orifice in the bladder is called a periureteral diverticulum [6]. When the bladder fills and the size of the diverticulum increases, the ureter drains into the paraureteral diverticula; vesicoureteral reflux is often associated with this. Large paraureteral diverticula can cause subvesical obstructions by compressing the urethra. It has been suggested that the kidney is more anomalous when the ureteral orifice is located paraureterally. When the ureteral orifice opens completely into a diverticulum, there is a single investment of fascia and a common embryologic origin. When the ureteral orifice opens separately into the bladder, there is a separate fascial investment and a different etiology [15].

The remaining 10% of CBD are found in posterolateral locations. In these patients, the CBD are not related to the location of the ureteral orifice or associated with VUR [16]. CBD are single in most patients and occur mostly in males. The second most frequent cases are double diverticula, which are rarely found in the nonobstructive polydiverticular bladder [17].

CBD are usually asymptomatic and are discovered accidentally. A diverticulum may present with a urinary obstruction; a recurrent infection due to the retention of urine in the diverticulum; or the development of calculi, hematuria, and micturition disturbance [1,3,9,14]. Urinary infection is the most common presentation, followed by urinary retention. Acute urinary retention is rare [18]. It has been reported that there is a chronic inflammation in 37%–81% of diverticula cases [1,4,19,20]. Chronic urine stasis within a diverticulum may cause the malignant change of its urothelium [21,22].

VCUG remains the gold standard for diagnosing CBD, which reveals a possible accompanying VUR [9,14]. Diverticula may be seen on an ultrasound, computed tomography urogram, or intravenous pyelogram [9,14]. Urodynamic studies are useful to rule out any associated obstructive or functional pathology [7].

The indications for surgery are the large size of the diverticula (>2–3 cm), persistent or recurrent urinary infections, the presence of stones or tumors in the diverticula, vesicoureteral reflux, ureteral obstruction and diverticular rupture [14,23,24]. The complete excision of the CBD has been proposed as a suitable treatment method in all patients requiring surgery; watchful

waiting has been suggested for asymptomatic cases because of the possibility of recurrence [14,21]. Surgical treatment may be administered by intravesical and/or extravesical treatment. Laparoscopic diverticulectomy also has been successfully performed [25], and endoscopic correction of vesicoureteric reflux by subureteric injection of dextranomer/hyaluronic acid has been successfully applied, even in the presence of a primary paraureteral diverticulum [26].

CBD can be found as large, bilateral bladder diverticula without vesicoureteral reflux. Urinary infection and urinary retention are the most frequent presentations, as it was in

our case. It is important to preoperative cystoscopy. Its treatment, in all symptomatic cases, is surgical and involves a transvesical diverticulectomy combined with the management of the associated surgical pathology.

#### **Acknowledgements**

The author(s) declare that they have no competing interests and financial support.

#### **REFERENCES**

1. Idrees MT, Alexander RE, Kum JB, Cheng L. The spectrum of histopathologic findings in vesical diverticulum: implications for pathogenesis and staging. *Hum Pathol.* 2013;44(7):1223-32.
2. Kong MX, Zhao X, Kheterpal E, Lee P, Taneja S, Lepor H, Melamed J, Deng FM. Histopathologic and clinical features of vesical diverticula. *Urology.* 2013;82(1):142-7.
3. Blane CE, Zerlin JM, Bloom DA. Bladder diverticula in children. *Radiology.* 1994;190(3):695-7.
4. Gerridzen RG, Futter NG. Ten-year review of vesical diverticula. *Urology.* 1982;20(1):33-5.
5. Melekos MD, Asbach HW, Barbalias GA. Vesical diverticula: etiology, diagnosis, tumorigenesis, and treatment. Analysis of 74 cases. *Urology.* 1987;30(5):453-7.
6. Hutch JA. Saccule formation at the ureterovesical junction in smooth walled bladders. *J Urol.* 1961;86:390-9.
7. Garat JM, Angerri O, Caffaratti J, Moscatiello P, Villavicencio H. Primary

- congenital bladder diverticula in children. *Urology*. 2007;70(5):984-8.
8. Akbulut S, Cakabay B, Sezgin A, Isen K, Senol A. Giant vesical diverticulum: a rare cause of defecation disturbance. *World J Gastroenterol*. 2009;15(31):3957-9.
  9. Rawat J, Rashid KA, Kanojia RP, Kureel SN, Tandon RK. Diagnosis and management of congenital bladder diverticulum in infancy and childhood: experience with nine cases at a tertiary health center in a developing country. *Int Urol Nephrol*. 2009;41(2):237-42.
  10. Bogdanos J, Paleodimos I, Korakianitis G, Stephanidis A, Androulakakis PA. The large bladder diverticulum in children. *J Pediatr Urol*. 2005;1:267-72.
  11. Hernanz-Schulman M, Lebowitz RL. The elusiveness and importance of bladder diverticula in children. *Pediatr Radiol*. 1985;15(6):399-402.
  12. Barrett DM, Malek RS, Kelalis PP. Observations on vesical diverticulum in childhood. *J Urol*. 1976;116(2):234-6.
  13. Kelalis PP. Obstructive uropathy: Bladder. In: Kelalis PP, King LR, editors. 1st ed. *Clinical pediatric urology*, Vol. 1. Philadelphia: Saunders; 1976. p. 282-91.
  14. Psutka SP, Cendron M. Bladder diverticula in children. *J Pediatr Urol*. 2013;9(2):129-38.
  15. Wickramasinghe SF, Stephens FD. Paraureteral diverticula. Associated renal morphology and embryogenesis. *Invest Urol*. 1977;14(5):381-5.
  16. Tokunaka S, Koyanagi T, Matsuno T, Gotoh T, Tsuji I. Paraureteral diverticula: clinical experience with 17 cases with associated renal dysmorphism. *J Urol*. 1980;124(6):791-6.
  17. Wickramasinghe SF, Stephens FD. Paraureteral diverticula: associated renal morphology and embryogenesis. *Invest Urol*. 1977;14(5):381-5.
  18. Pieretti RV, Pieretti-Vanmarcke RV. Congenital bladder diverticula in children. *J Pediatr Surg*. 1999;34(3):468-73.
  19. Peterson LJ, Paulson DF, Glenn JF. The histopathology of vesical diverticula. *J Urol*. 1973;110(1):62-4.
  20. Tamas EF, Stephenson AJ, Campbell SC, Montague DK, Trusty DC, Hansel DE. Histopathologic features and clinical outcomes in 71 cases of bladder diverticula. *Arch Pathol Lab Med*. 2009;133(5):791-6.
  21. Khemakhem R, Ghorbel S, Jlidi S, Nouira F, Louati H, Douira W, et al.

- Management of congenital bladder diverticulum in children: A report of seven cases. *Afr J Paediatr Surg.* 2013;10(2):160-3.
22. Mak DK, Macharia E, Wragg R, Parashar K. Congenital bladder diverticulum with benign bladder wall lesion resembling rhabdomyosarcoma. *JSCR.* 2010;4:7.
23. Shukla AR, Bellah RA, Canning DA, Carr MC, Snyder HM, Zderic SA. Giant bladder diverticula causing bladder outlet obstruction in children. *J Urol.* 2004;172(5 Pt 1):1977-9.
24. Shigehara K, Taya T, Hisazumi H. Primary adenocarcinoma in the bladder diverticulum. *Scand J Urol Nephrol.* 2008;42(5):481-3.
25. Kok KY, Seneviratne HS, Chua HB, Yapp SK. Laparoscopic excision of congenital bladder diverticulum in a child. *Surg Endosc.* 2000;14(5):501.
26. Perez-Brayfield M, Kirsch AJ, Hensle TW, Koyle MA, Furness P, Scherz HC. Endoscopic treatment with dextranomer/hyaluronic acid for complex cases of vesicoureteral reflux. *J Urol.* 2004;172(4 Pt 2):1614-6.

**Access this article online**

<http://pediatricurologycasereports.com>

**Quick Response Code**

