



PEDIATRIC UROLOGY CASE REPORTS

ISSN: 2148–2969

Journal homepage: <http://www.pediatricurologycasereports.com>**Epispadias with intact prepuce: A case report****Mete Kaya, Serpil Sancar, Esra Ozcakir***Sevket Yilmaz Education and Research Hospital, Department of Pediatric Surgery, Bursa, Turkey*

Abstract Isolated epispadias is rare congenital anomaly. An uncommon variation of this anomaly may present with intact prepuce, and it may not be recognized until later during childhood. Herein, we aim to report a case of isolated epispadias with intact prepuce who underwent modified Cantwell-Ransley repair because of rarity.

Key Words Epispadias; male; child; intact prepuce; epispadias repair.

Copyright © 2015 pediatricurologycasereports.com.

Corresponding Author: Mete Kaya, M.D.

Sevket Yilmaz Education and Research,

Department of Pediatric Surgery, Bursa, Turkey

E mail: kayamete@yahoo.com

Accepted for publication: 25 August 2015

INTRODUCTION

Epispadias is a rare congenital malformation of the penis, often a part of exstrophy of the bladder, and characterized by a dorsal urethral defect where it is replaced by a broad mucosal strip lining the dorsum of the penis extending toward the bladder. Isolated epispadias is rare with an incidence of around 1 in every 120 000 births. Isolated epispadias can be seen at the glandular,

coronal, shaft or penopubic levels. [1,2]. In the distal types, bladder neck is rarely affected, the everted urethral plate begins at the penile shaft or involves the glans only, and, rarely, the development of prepuce in this types of epispadias is entirely normal [3]. It is very uncommon to see an epispadias with intact prepuce.

We aim to report a case of epispadias in a boy with an intact prepuce, who underwent urethroplasty by modified Cantwell-Ransley repair technique.

CASE REPORT

A 3-year-old boy was referred to our department for treatment of epispadias that

was incidentally discovered during physical examination by his family doctor. There was no complains of urinary symptoms such as frequency and urgency, dysuria, and suprapubic pain. On physical examination, a normal penoscrotal development was noted, the testes were located in the scrotum, and a normal uncircumcised penis was seen (Fig. 1).




Fig. 1. Photo showing the uncircumcised penis.

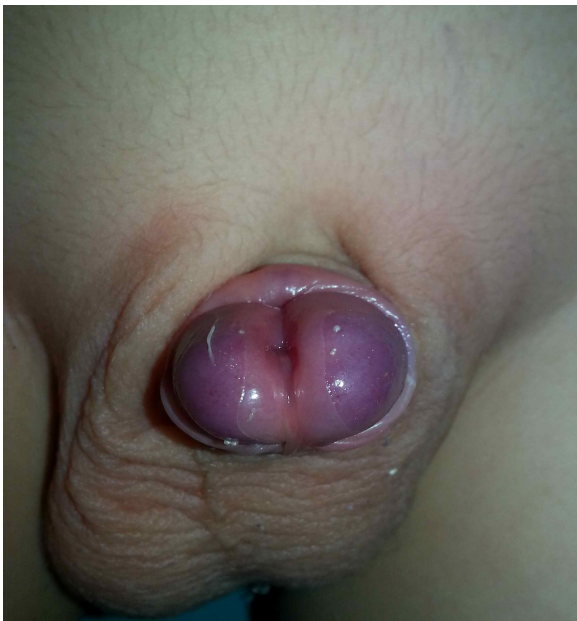

Fig. 2. Distal epispadias discovered after retraction of the prepuce.

Retraction of prepuce revealed a distal epispadias (Fig.2). Preoperatively the patient underwent urinalysis, urine culture, imaging studies, including urinary ultrasonography, voiding cystourethrography, and an urodynamic study. All of them were within normal range. At that time, it was decided to repair this penile anomaly on elective conditions. The patient was given preoperative antibiotic, and operated under general anesthesia.

The modified Cantwell–Ransley technique was used for primary urethroplasty as described in detail previously [4]. In brief, the penile shaft was degloved after a circumferential scalpel incision from the preputial mucosa 0.5 cm proximal to the coronal sulcus, around the epispadiac meatus and urethral plate (Fig. 3).

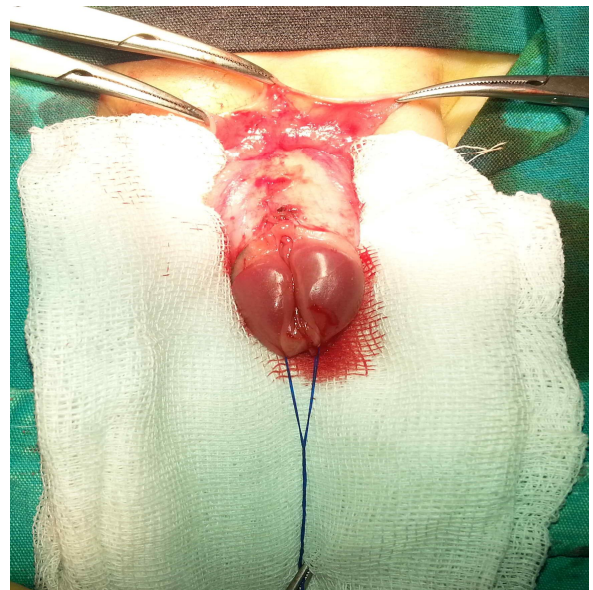


Fig. 3. Degloved penis after circumferential incision and neurovascular bundle are seen.

Then, the urethral plate was partially dissected off the corpora, remaining attached to the glans on its distal aspect. After that, the urethral plate was tubularized by using a running 7-0 PDS suture over a 8 Fr catheter, the mobilized glans wings were approximated medially with interrupted 7-0 PDS sutures and the neourethra was transposed ventrally (Fig. 4).

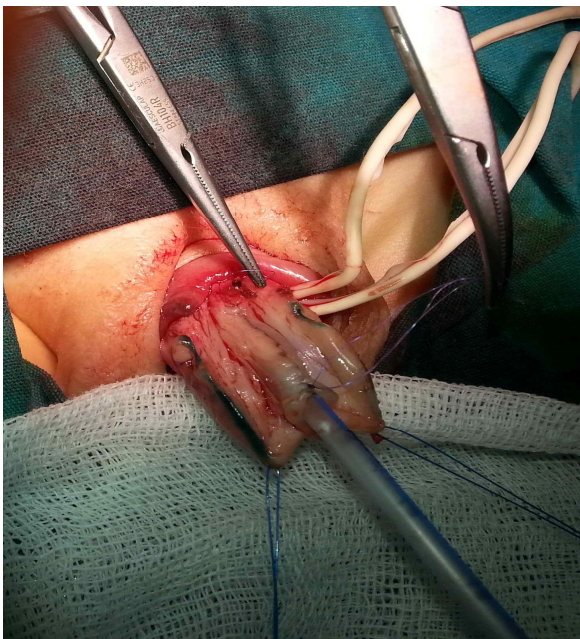

Fig. 4. Creating neourethra with tubularization of dorsal urethral plate after degloving.

Mild dorsal penile curvature was corrected by corpoplasty (internal rotation of the corpora) without cavernocavernostomy after dissection of the neurovascular bundle. Skin closure was easily achieved with sufficient redundant penile skin (Fig. 5). The dressing was opened on the 5th postoperative day and he voided with good stream after removal of the catheter on the

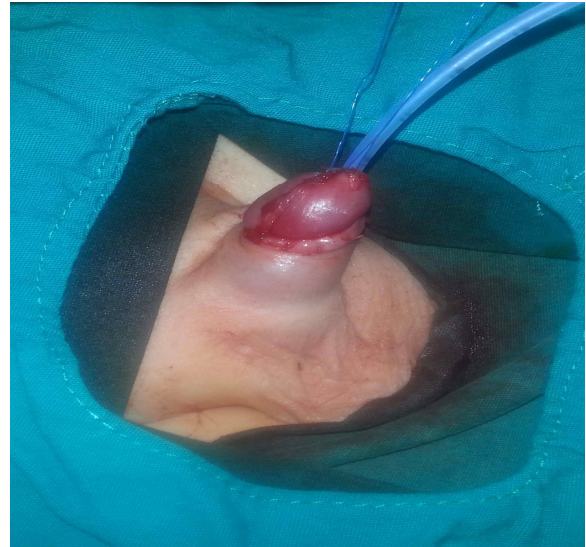

Fig. 5. The lateral aspect of the penis at end end of surgery without requiring any skin flap.

7th postoperative day. Patient was followed up in the outpatient clinic at intervals, at nine months post repair, he was still good volitional voids without incontinence, the patient was satisfied with excellent cosmetic result except mildly torsion (Fig. 6).




Fig. 6. Appearance of the penis on postoperative sixth month

DISCUSSION

In the patient with isolated epispadias, the prepuce skin is usually absent dorsally and hangs as a tag of redundant tissue on the ventral aspect of the penis [3,5]. There are limited case-reports of epispadias with intact prepuce in the literature. Baskin has explained the development of the prepuce with the active growth of mesenchyme between the preputial fold and the glandular lamella, which transports the fold distally until it covers the glans completely [6]. Raghavaiah has suggested that the development of prepuce continues until the completion since the foreskin is usually originated from the fold of ectodermal at the level of the coronal sulcus [7]. McCahill et al. stated that the developing prepuce beside the dorsal urethral defect is partially diverted over the defect [8]. Despite the different theories, it still remains difficult to explain the development of epispadias with an intact prepuce.

If epispadias does not appear directly in the first presentation, diagnosis is easily overlooked. Although, such a broad-based, tent-like or spade-like glans on physical examination could lead to suspicions of epispadias, a correct diagnosis may be delayed until circumcision because this form of the epispadias is rare [3]. The lesion in our patient was also discovered incidentally

during circumcision. The primary goals of treatment of epispadias are to: correct the dorsal chordee, create the sufficient length and a straight of the penis, and create functionality and cosmetically acceptable external genitalia [2]. Mostly, a neourethra was created from dorsal urethral plate with glanular tubularization without using prepuce in epispadias patients. A simple rotational corporoplasty is needed for straightening mild dorsal curvature. Various operations have been devised in attempt to achieve these goals. Modified Cantwell-Ransley repair and Mitchell repair are the most popular surgical techniques, and address numerous technical aspects of these goals [4,9-11]. Complete penile disassembly for epispadias repair (the Mitchell technique) has a lower complication rate and facilitates bladder and bladder neck repair. Cantwell-Ransley technique consists a partial disassembly of the penis and placement of the urethra in a more normal position. We have applied partial disassembly method which is in accordance with the modified Cantwell-Ransley technique. A glanular tubularization with using dorsal plate was carried out with a simple rotational corporoplasty. Although, the patient had no postoperative complications and had excellent cosmetic results, but it is still not clear which method to have provide better

results in the cases of the distal epispadias with intact prepuce. It is proposed that, for penopubic or midshaft epispadias, or even in glanular types, the presence of dorsal curvature may need for a more aggressive approach and the incomplete distal disassembly sometimes prevents ideal corporal rotation and, accordingly, urethral tube ventralization [10]. We have not encountered any difficulties while performing a corporoplasty and urethral ventralization, but a mild degree residual penile torsion was seen after surgery. In fact, it has been present since birth, and it could have been overcome by asymmetric corporal rotation. We still do not know whether partial penile disassembly causes residual penile torsion. Complete or partial disassembly is a different issue to be discussed on a case-by-case basis. On the other hand, a complete disassembling of the corporas in these cases may carry the risk of injury to the neurovascular bundle and corporal devascularization. Mokhless et al. have stated that in treating cases of isolated epispadias, unlike cases of associated

exstrophy, complete disassembly with dissection of the corpora proximal to the penopubic region will not add real advantages [11].

In conclusion, epispadias with an intact prepuce is a very rare congenital anomaly. Diagnosis may be delayed until later childhood or it may be diagnosed incidentally. Although a complete penile disassembly with dissection of the corpora proximal to the penopubic region is essential to obtain easy medial rotation of the corpora with proper ventralization of the tubularized urethral plate, we believed that partial penile disassembly would be enough in patients with distal epispadias.

Acknowledgements

The author(s) declare that they have no competing interests and financial support.

REFERENCES

1. Bos EM, Kuijper CF, Chrzan RJ, Dik P, Klijjn AJ, de Jong TP. Epispadias in boys with an intact prepuce. *J Pediatr Urol.* 2014;10(1):67-73.
2. Grady RW, Mitchell ME. Management of epispadias. *Urol Clin North Am.* 2002;29(2):349-60.

3. Merlob P, Mor N, Reisner SH. Epispadias with complete prepuce and phimosis in a neonate. *Clin Pediatr (Phila)*. 1987;26(1):43-5.
4. Gearhart JP, Leonard MP, Burgers JK, Jeffs RD. The Cantwell-Ransley technique for repair of epispadias. *J Urol*. 1992;148(3):851-4.
5. Sina A, Alizadeh F. Concealed male epispadias: a rare form of penile epispadias presenting as phimosis. *Urol J*. 2011;8(4):328-9.
6. Baskin, L.S. Basic science of the genitalia. In: Docimo SG, Canning DA, Khoury AE (eds.) *Kelalis-King-Belman Textbook of Clinical Pediatric Urology*. 5th ed. Florida: CRC Press; 2007. Pp. 1117–1125.
7. Raghavaiah NV. Epispadias associated with phimosis. *J Urol*. 1976;116(5):671-2.
8. McCahill PD, Leonard MP, Jeffs RD. Epispadias with phimosis: an unusual variant of the concealed penis. *Urology*. 1995;45(1):158-60.
9. Kureel SN, Gupta A, Singh CS, Rawat J. A novel skin management scheme in surgery of epispadias undergoing Cantwell-Ransley repair: a technique to improve the aesthetics and minimize complications. *Urology*. 2013;82(6):1400-4.
10. Yachia D. Epispadias. In: Yachia D (ed). *Text atlas of penile surgery*. First ed. London: Informa Healthcare; 2007. pp. 107-114.
11. Mokhless I, Youssif M, Ismail HR, Higazy H. Partial penile disassembly for isolated epispadias repair. *Urology*. 2008;71(2):235-8.

Access this article online

<http://pediatricurologycasereports.com>

Quick Response Code

