



PEDIATRIC UROLOGY CASE REPORTS

ISSN: 2148–2969

Journal homepage: <http://www.pediatricurologycasereports.com>

Testicular fibrous hamartoma: A case report

Asuman Kilitci¹, Fahri Yilmaz², Serdar Yanik³, Hulya Ozturk⁴

¹Ahi Evran University Education and Research Hospital, Department of Pathology, Kırşehir, Turkey

²Abant İzzet Baysal University, Faculty of Medicine, Department of Pathology, Bolu, Turkey

³İskenderun State Hospital, Department of Pathology, Hatay, Turkey

⁴Abant İzzet Baysal University, Faculty of Medicine, Department of Pediatric Surgery, Bolu, Turkey

Abstract Fibrous hamartoma (FH) of childhood is uncommon benign tumor. They are generally seen in the head and neck region, gastrointestinal system and lung. As in the case we report, they may also occur in other unusual sites such as groin and testis. The clinical presentation is almost always a mass or swelling. We hereby report a case with FH in atrophic testis which is unusual location and clinical presentation.

Key Words Testis; fibrous hamartoma; childhood; testicular atrophy.

Copyright © 2015 [pediatricurologycasereports.com](http://www.pediatricurologycasereports.com).

Corresponding Author: Asuman Kilitci, M.D.,

Ahi Evran University

Education and Research Hospital,

Department of Pathology, Kırşehir, Turkey.

E mail: dr.asuk@gmail.com

This article has been presented in part at the 24th European Congress of Pathology at Prague, held at September 8-12, 2012.

Accepted for publication 4 August 2015

INTRODUCTION

Prepubertal testicular tumors are different from those that appear during adulthood [1]. Historically, most of these tumors have been considered malignant, but more recent studies indicate that there are more cases of benign testicular tumors than malignant tumors during infancy and childhood.

Fibrous hamartoma (FH) is a benign, soft tissue growth, which was described by Reye

in 1956 [2]. This uncommon benign tumor is a focal malformation resembling a neoplasm, composed of an overgrowth of mature cells and tissues that normally occur in the affected area. Nevertheless, these mature cells and tissues are disorganized [3]. Although they are generally reported in the head and neck region, gastrointestinal system and lung, it seldom may involve genitourinary anatomical sites. The most common clinical presentation of the cases with FH is almost always a mass or swelling.

We hereby report a pediatric case of FH which located in atrophic left testis.

CASE REPORT

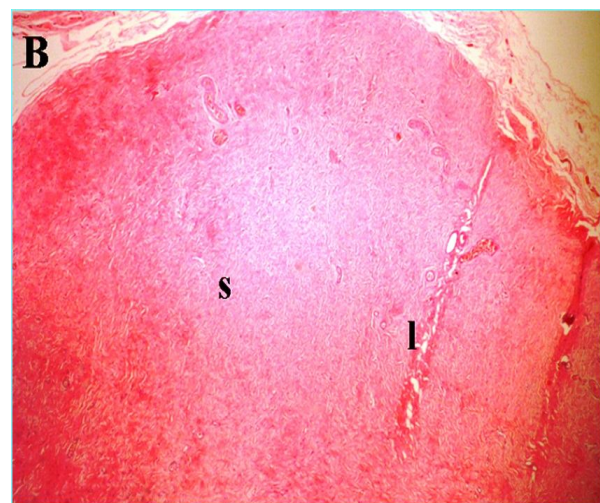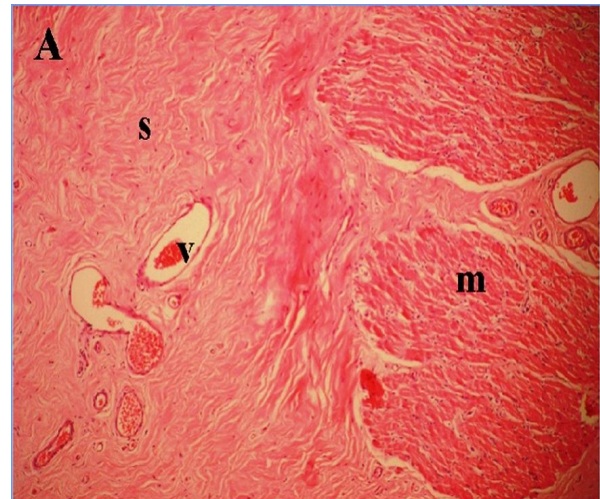
A 7-year-old boy presented to department of pediatric surgery at Abant Izzet Baysal University Hospital. The major symptom of the patient was left testicular atrophy. There was no history of previous scrotal swelling, trauma, fever or loss of weight.

In the ultrasound examination, size of left testis was smaller compared to the right one and contained hypoechoic, oval shaped areas. Testicular tumor's markers and results of hematological and biochemical analysis were within normal limits. Left orchiectomy was performed.

In macroscopic examination, testis dimension was 1.5x1.3x0.4 cm. Its cut

surface was smooth and dirty-white. The histological section prepared from the material showed, disorganized mature tissue that composed of fibrocollagen stroma, vessels, muscular and adipose tissue (Fig. 1A, B, C and D). Neither evidence of a malignant lesion nor intratubular germ cell neoplasia was detected on histological assessment.

The histological findings were consistent with testicular fibrous hamartoma (TFH).



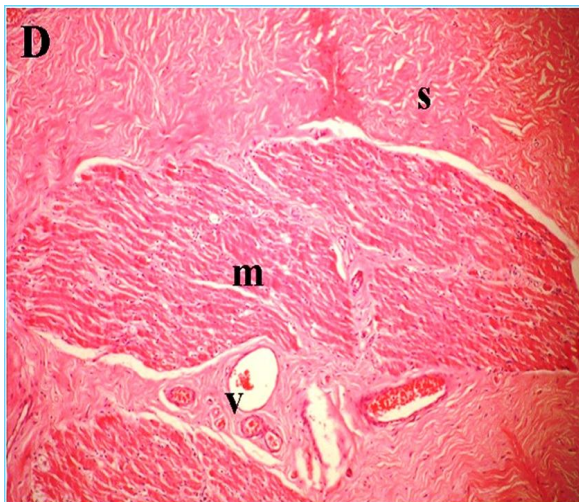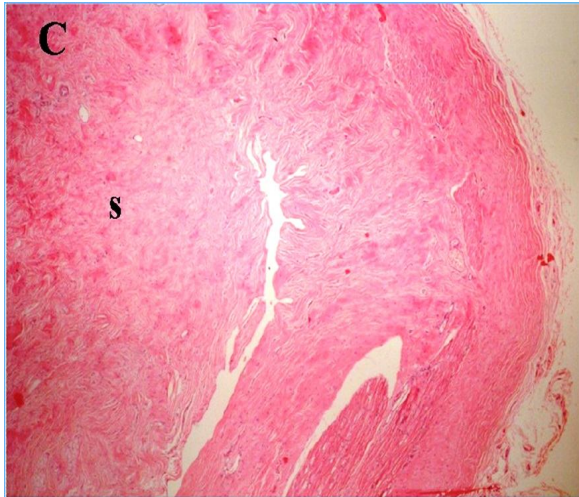


Fig. 1 A,B,C,D. Testicular mass composed of fibrocollagen stroma (s), irregular muscle bundles (m), vessels (v) and adiposus tissue (l) (A: H&E, X100; B: H&E, X40; C: H&E, X40; D: H&E,X100).

DISCUSSION

Hamartomas may be seen anywhere in the body and are often seen in infancy and childhood. Hence, it has been believed that lesions are developmental aberrations [4].

They are commonly seen in boys and rarely occur under two years of age [5]. Our case was seven years old.

The tumor has been reported to occur in different sites of the body, but it is generally found in the upper torso. Genitourinary sites were unusual locations. An extensive review of the literature found only 8 reports of FH in the genital region [6].

The paratesticular area is a complex anatomical area and histogenetically this area is composed of a variety of epithelial, mesothelial and mesenchymal components. Neoplasms arising from this region therefore form a heterogeneous group of tumors with different behavioral patterns and have a extensive differential diagnosis. The clinical presentation is often a mass or swelling [7]. This clinical finding doesn't help to distinguish tumor from other situations, even our case was admitted to our hospital because of testicular atrophy.

Benign tumors of testis are as common as malignant ones in pediatric age group. Bujons et al in 24 years period, reported 15 testicular tumors in children<13 in which 12 (80%) were benign lesions and the remaining 3 were malignant. The most common benign lesion was the epidermoid cyst, a far greater percentage than the 3% described in literature. Other benign lesions

included teratom, hemangioma, fibrous hamartoma, splenogonadal fusion [1].

In another study, in 13 years period, Jimenes et al informed 14 testicular tumors. Mean age was 2.54 years. The most frequent tumor was the yolk sac tumor (36%), followed by mature teratoma (29%), Leydig cell tumor, epidermoid cyst, paratesticular fibrous hamartoma, paratesticular neuroblastoma and paratesticular rhabdomyosarcoma (7% each) [8].

So far several TFH cases have been reported in English literature. The first case was reported by Srigley and Hartwick, in a two years old child [3]. They described that the tumor consisted of a disorganized cluster of tubules embedded in a loose connective tissue stroma and tubules were lined by cells that were cytologically similar to normal rete testis. This tumor is called as hamartoma of rete testis and is

morphologically different from fibrous hamartoma [9].

In conclusion, TFH should be in consideration in cases with testicular atrophy. TFH should be included in the differential diagnosis of childhood testicular lesions such as testicular torsion, incarcerated hernia, malignant neoplasm, etc in order to allow a proper diagnosis and prevent insufficient treatment.

Acknowledgements

The author(s) declare that they have no competing interests and financial support.

REFERENCES

1. Bujons A, Caffaratti J, Pascual M, Angerri O, Garat JM, Villavicencio H. Testicular tumours in infancy and children. *Actas Urol Esp.* 2011;35(2):93-8.
2. Reye RD. A consideration of certain subdermal fibromatous tumours of infancy. *J Pathol Bacteriol.* 1956;72(1):149-54.
3. Srigley JR, Hartwick RW. Tumors and cysts of the paratesticular region. *Pathol Annu.* 1990;25 Pt 2:51-108.
4. Maitra A, Kumar V. Diseases of infancy and childhood: In: Kumar V., Abbas AK, Fausto N (Editors). *Robbins and Cotran Pathologic Basis of Disease.* International edition; Elsevier Saunders, 2005, pp. 469-510.

5. Ferro F, Caterino S, Boldrini R, Bosmann C, Cavallini M. Fibrous hamartoma of infancy in the scrotum. *Pediatr Surg Int.* 1988; 4: 71-3.
6. Sengar M, Mohta A, Manchanda V, Khurana N. Paratesticular fibrous hamartoma in an infant. *Singapore Med J.* 2012; 53(3): e63-5.
7. Lioe TF, Biggart JD. Tumours of the spermatic cord and paratesticular tissue. A clinicopathological study. *Br J Urol.* 1993;71(5):600-6.
8. Jiménez Isabel MA, Gómez Fraile A, Aransay Brantot A, et al. Testicular tumors in childhood. Review of cases in the course of 13 years. *Cir Pediatr.* 1996;9(1):13-6.
9. Akpolat N, Cihangiroğlu G, Atikeler MK, Paratesticular fibrous hamartoma in an adult: Case report and review of the literature. *Firat Tıp Dergisi.* 2008; 13(4): 283-5.

Access this article online

<http://pediatricurologycasereports.com>

Quick Response Code

