



PEDIATRIC UROLOGY CASE REPORTS

ISSN: 2148–2969

Journal homepage: <http://www.pediatricurologycasereports.com>**An unusual localization: Preputial hemangioma****Cansu Unden Ozcan¹, Teoman Ozcan¹, Banu Yaman², Selcuk Yazici³**¹Department of Pediatric Surgery and ²Pediatrics, Balikesir University, Medical Faculty, Balikesir, Turkey³Department of Pathology, Ege University, Medical Faculty, Izmir, Turkey

Abstract Hemangiomas are the most common tumor of infantile period and usually involved sites are head and neck (%50), followed by trunk and extremities. Hemangioma is rarely described in genitals. We report a 17-months-old patient with a hemangioma of the preputium penis. The tumor was completely removed surgically and histological examination revealed an infantile hemangioma.

Key Words Hemangioma; child; prepuce; circumcision.

Copyright © 2015 [pediatricurologycasereports.com](http://www.pediatricurologycasereports.com).

Corresponding Author: Cansu Unden Ozcan, M.D.
Balikesir University, Medical School,
Department of Pediatric Surgery, Balikesir, Turkey
E mail: pedsurg35@gmail.com
Accepted for publication: 21 Jul 2015

INTRODUCTION

Infantile hemangiomas are benign proliferations of endothelial tissue and represent the most common tumors arising in the neonatal period. They represent localized or regional areas of abnormal vascular development and proliferation [1]. Hemangiomas may occur anywhere on the

skin and mucosal surfaces approximately %50 head and neck [2]. Scrotal and penile (genital) hemangiomas are unusual anomalies and comprise less than 1% of all hemangiomas [3]. Management of infantile hemangiomas include active non-intervention, treatment of ulceration, local medical therapies (intralesional corticosteroids, topical corticosteroids, topical betablockers, topical imiquimod), systemic therapies (systemic corticosteroids, systemic betablockers), surgical and laser therapy [1].

CASE REPORT

A 17-months-old boy was admitted to our department with a circumcision demand. On physical examination there was a 0.5x0.5x0.5cm ovoid, soft and purple hemangioma on the left of the foreskin which was first noted at the age of one month and a gradual enlargement of the tumor was detected by his family (Fig. 1).



Fig. 1. Preputial hemangioma.

There was no history of trauma. Routine laboratory examinations were normal and no other abnormalities present. The mass had no connection with the corpus cavernosum penis and so the lesion was totally excised during circumcision under general anesthesia without any complication. Histological examination showed an infantile hemangioma (Fig. 2). The postoperative follow-up was problem free.

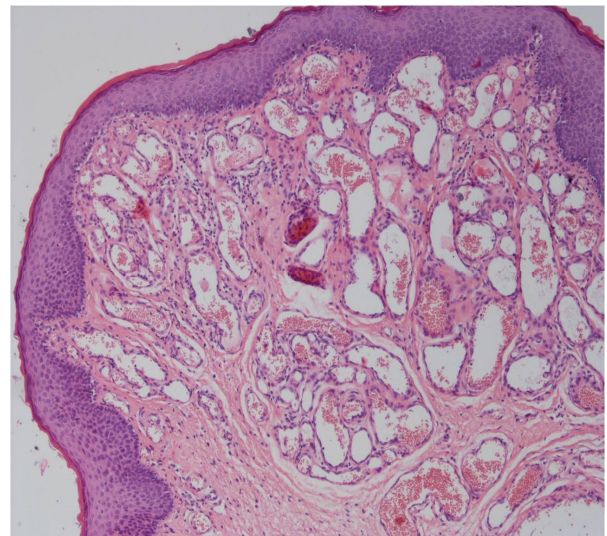


Fig. 2. Histopathology of the lesion: Dilated vascular spaces fulfilled with erythrocytes (H&E X100).

DISCUSSION

Hemangioma is the most common benign vascular tumor that originates from proliferation of immature capillary vessels. Urogenital hemangiomas are usually seen at the kidneys and the bladder. Also, hemangiomas have been reported in the urethra, genital skin, and prostate. This disorder is rarely described at the genitalia [4]. Only a few cases of hemangiomas at preputium penis have been reported in the world literature [5-7]. The majority of infantile hemangiomas do not require any specific treatment, usually observation and reassurance of the parents are enough [8]. Besides, there is no well-defined algorithm

for treatment of genital hemangiomas because of the rarity of the pathology [9]. In the literature a variety of treatment methods have been applied for glans penis hemangiomas as laser, sclerotherapy or surgical excision [10].

Nevertheless, for the preputial hemangiomas totally excision of the tumor by circumcision was preferred [5-7]. Infantile hemangiomas have a characteristic life cycle of rapid growth in the first year of life (proliferative phase) followed by spontaneous regression from ages 1 to 7 years (involuting phase). Once involuted, they never recur [11].

Our patient was in the involution phase, however, he was admitted with a circumcision demand and because this procedure is preferable as a religious and a traditional treatment in our country and would be done sooner or later, we applied a

totally surgical removal of the tumor by circumcision.

As a result, treatment options of hemangiomas vary with patient age, localization of the lesion, rapid growth, local and endangering complications, social factors and a regular scheduled follow-up is essential [11]. But circumcision may be the first treatment option for a preputial hemangioma free of complications and recurrence and satisfaction with aesthetic results.

Acknowledgements

The author(s) declare that they have no competing interests and financial support.

REFERENCES

1. Haggstrom AN, Garzon MC. Infantile hemangioma. In: Bologna JL, Jorizzo JL, Scahffer JV. *Dermatology*. 3 rd ed. Elsevier Saunders; 2012. pp .1691-1709.
2. Hemangioma Investigator Group: Haggstrom AN, Drolet BA, Baselga E, et al. Prospective study of infantile hemangiomas:demographic, prenatal and perinatal characteristics. *J Pediatr*. 2007;150(3):291-4.
3. Lin Y, Sun GH, Yu DS, et al. Intrascrotal hemangioma. *Arch Androl*. 2002;48(4):259-65.
4. Ulker V, Esen T. Hemangioma of the glans penis treated with Nd:YAG laser. *Int Urol Nephrol*. 2005;37(1):95–6.
5. Kim CJ, Okada Y, Konishi T, Kounami T, Pak K, Tomoyoshi T, et al. Cavernous hemangioma of the penis: report of a case immunohistochemically

- studied. Hinyokika Kyo. 1990; 36(9):1085-8.
6. Senoh H, Ichiwaka Y, Okuyama A, Takaha M, Sonoda T. Cavernous hemangioma of scrotum and penile shaft. Urol Int. 1986;41(4):309-11.
 7. Santos E, Sarma D. Hemangioma of the Prepuce. The Internet Journal of Dermatology. 2006;4(1):1.
 8. Margileth AM, Museles M. Cutaneous hemangiomas in children: Diagnosis and conservative management. JAMA. 1965;194(5):523-6.
 9. Casale AJ, Menashe DS. Massive strawberry hemangioma of the male genitalia. J Urol. 1989;141(3):593-4.
 10. Yildirim I, Irkilata C, Sumer F, Aydur E, Ozcan A, Dayanc M. Fibroepithelial polyp originating from the glans penis in a child. Int J Urol. 2004;11(3):187-8.
 11. Smithers C.J, Fishman S.J. Vascular anomalies. In: Aschraft K.W, Holcomb G.W, Murphy J.P. Pediatric Surgery. 4th ed. Elsevier/Saunders; 2005. pp.1038-1053.

Access this article online

<http://pediatricurologycasereports.com>

Quick Response Code

