



Transperitoneal laparoscopic nephrectomy of non-functional horseshoe kidney that could not be identified preoperatively in a child

Soner Coban¹, Ali Riza Turkoglu¹, Muhammet Guzelsoy¹, Seyda Efsun Ozgunay², Dursun Unal¹, Tuncay Ozgunay¹, Murat Demirbas¹

¹ Sevket Yilmaz Research and Educational Hospital, Department of Urology, Bursa, Turkey

² Sevket Yilmaz Research and Educational Hospital, Department of Anesthesia, Bursa, Turkey

Abstract Horseshoe kidney is the most common congenital fusion anomaly. Ureters being stuck between the isthmus and the intestines cause urinary stasis and lead to more common development of urinary tract infection and urolithiasis compared to a normal kidney. If not treated, kidney function may be gradually lost. Although the condition is usually diagnosed with ultrasound screening, the diagnosis may be overlooked in patients with a non-functional kidney due to the lack of renal vascularization. We aim to present a 6 years old boy who have non-functioning kidney which is a part of undiagnosed horseshoe kidney. We emphasize that horseshoe kidney should be suspected when live renal parenchyma tissue passing the midline is observed during laparoscopic nephrectomy of a non-functional kidney that could not be preoperatively diagnosed as a horseshoe kidney in this presentation.

Key words Non-functioning kidney; laparoscopy; nephrectomy; horseshoe kidney.

Copyright © 2015 [pediatricurologycasereports.com](http://www.pediatricurologycasereports.com).

Corresponding Author: Soner Coban, M.D.,
Sevket Yilmaz Research and Educational Hospital,
Emniyet Street, Yildirim, Bursa, Turkey
E mail: sonercoban75@myynet.com

Accepted for publication: 24 March 2015

INTRODUCTION

Horseshoe kidney is the most common renal fusion anomaly with an incidence of 1 in 400. It is two times more common in males [1,2]. The rotation is not full and there is high ureteric insertion point and abnormal course of the ureters the because of its variable blood supply and the presence of an isthmus [3]. Urinary drainage may be impaired due to these anomalies and stasis. Although patients with the horseshoe kidney are usually asymptomatic, they can be found more commonly with urinary tract infection, stone disease, ureteropelvic junction obstruction and renovascular hypertension [4,5]. The diagnosis can usually be made with ultrasound screening but the horseshoe kidney may be overlooked when there is a non-functioning kidney without perfusion. Laparoscopic nephrectomy in the patients with non-functioning kidney is currently preferred due to its advantages such as less post-operative pain, shorter hospitalization duration, small incision and better cosmetic results. We present a patient who underwent laparoscopic nephrectomy of a horseshoe kidney that had become non-functional due to urinary tract infection and could not be diagnosed preoperatively.

CASE REPORT

A 6-year-old boy patient was referred from another center due to left flank and

abdominal pain and intermittent fever. Renal function tests, hemogram and urine culture results were normal. Magnetic resonance imaging (MRI) was taken at another center, the patient was admitted to us with MRI examination, and these images did not show the horseshoe kidney appropriately. The ultrasonography (US) was revealed a markedly hydronephrotic left kidney together with a thin renal parenchyma. The contrast uptake could not be seen in the left kidney. Therefore, the borders of the left kidney could not be distinguished intravenous pyelogram (IVP) in the inspection (Fig. 1).

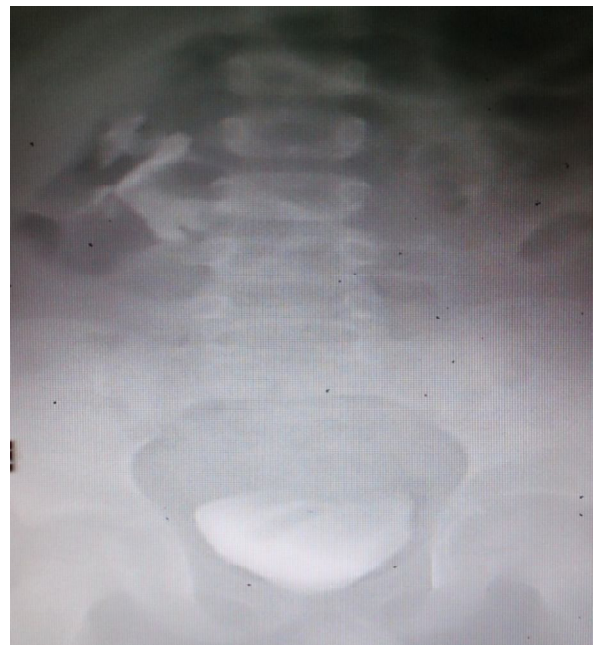

Fig. 1. IVP: Left kidney contours could not be selected on IVP and no contrast matter was seen in the left renal area. Grade 2 hydronephrosis plus blunt calyces were also seen in the right kidney.

Ureterohydronephrosis was found in the right kidney. The left kidney contributed only 7% to renal function on MAG 3 (mercaptoacetyltriglycine) scintigraphy (Fig. 2).

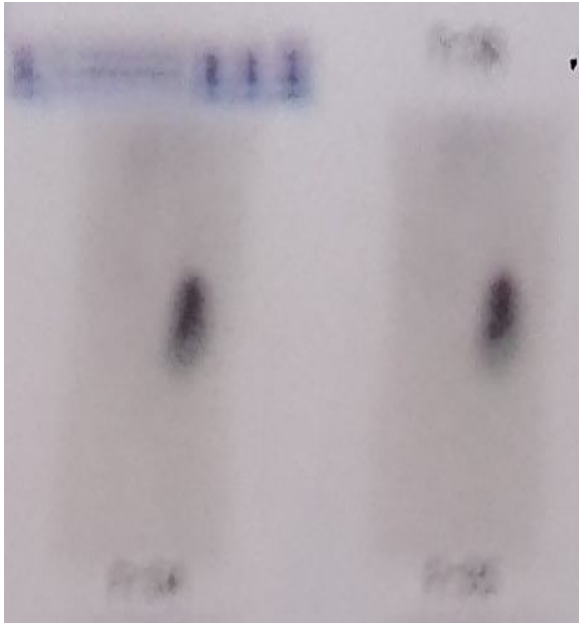


Fig. 2. MAG 3 kidney scintigraphy image.

There was no reflux after voiding cystourethrography (VCUG). The patient was taken to surgery for right retrograde pyelography and left laparoscopic nephrectomy, with diagnoses of left non-functioning kidney and right hydronephrosis. A right retrograde pyelography (RGP) was performed during the surgery but no pathology explaining the etiology of the right renal obstruction was seen. We think that it was a rotational anomaly (Fig. 3). The same procedure was then performed on the left side. The patient was then placed in the 60° lateral flank

position and an incision of about 1 cm was made from the upper umbilicus edge. The peritoneal cavity was entered with a Veres needle. After making sure with the syringe that the peritoneum had been entered, a 10 mmHg pneumoperitoneum was created and a 10 mm trocar was placed.

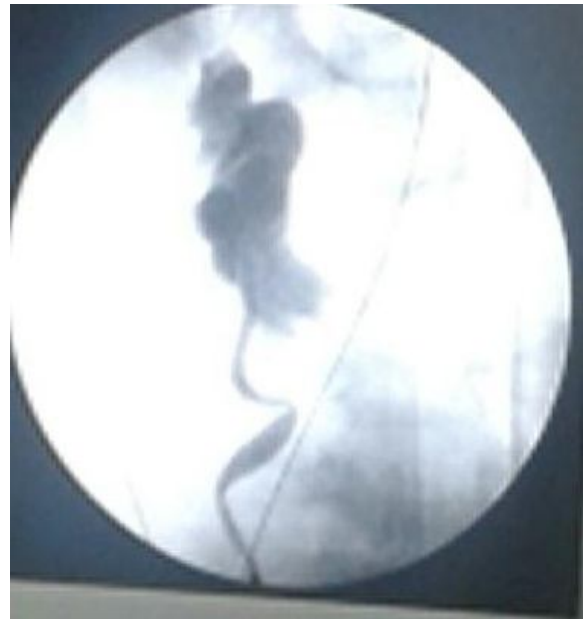

Fig. 3. Pre-operative right retrograde pyelography: A right retrograde pyelography was performed during the surgery but no pathology explaining the etiology of the right obstruction was seen. As we mentioned before, there was neither ureteral stone nor UPJ obstruction; therefore we concluded as rotational anomaly.

The abdominal cavity was viewed using a 0 degree camera placed through the umbilical trocar and two trocars of 10 and 5 mm were added. The intestines were medialized and the retroperitoneum was opened. The ureter draining the non-functional kidney was determined and carefully dissected up to the

renal hilum. The renal artery and vein were cut after being connected with Hem-o-Lock clips. The kidney lower pole did not mobilize easily during dissection and the parenchymal structure was seen to be still alive. Therefore, we have decided to open surgery because of the suspected a horseshoe kidney (Fig. 4).

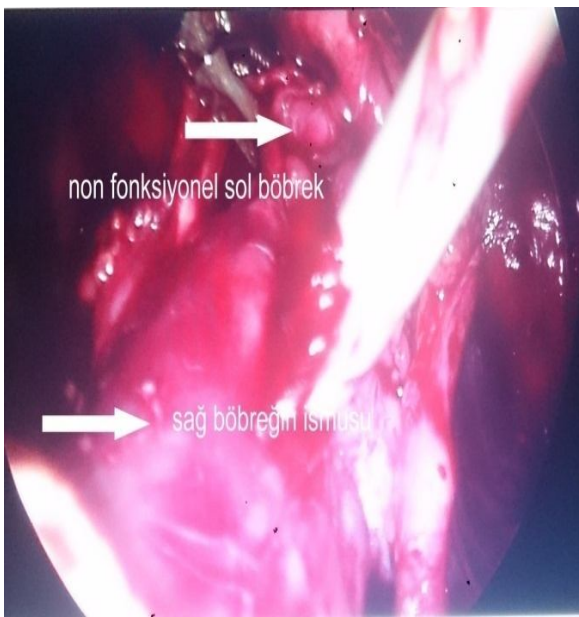


Fig. 4. Isthmus of right kidney and left kidney from which the pre-operative hydronephrosis has been aspirated.

Once we saw that it actually was a horseshoe kidney, isthmectomy was performed and the non-functional kidney was removed. A drain was placed after bleeding control and the procedure was ended. Postoperative course was uneventful, the drain removed at the 3th postoperative day, the patient discharged on 5th day. He is

still asymptomatic on four months follow-up period.

DISCUSSION

Laparoscopy in pediatric urology is currently preferred approach for its advantages such as less post-operative pain, shorter hospitalization duration, small incision and better cosmetic results. The main indications of laparoscopy in children are vesicoureteral reflux, multicystic dysplastic kidney, pyelonephritis and non-functioning kidney. The transperitoneal or retroperitoneal approaches are accepted as the first choices for this procedure [6-8]. In our institution, laparoscopic nephrectomy is primarily preferred method in the patients with non-functioning kidney.

Horseshoe kidney is one of the most common congenital urinary anomalies, and also a fusion defect where the upper or lower poles of both kidneys are combined at the midline. The fusion is at the lower region of the kidneys in 95% of the cases. The vascularization of the horseshoe kidney is also quite variable. A single renal artery is present in 30% of the cases and there may be double or triple blood supply in one or both kidneys [9]. In our case, a double renal artery was found.

Most of the patients with horseshoe kidney are asymptomatic and the most common

finding leading to the diagnosis is urinary system infections [9-12]. The case presented herein had been treated medically by primary care physician for the last 2 years due to flank pain, abdominal pain, and intermittent fever.

Approximately one third of patients with horseshoe kidney remain asymptomatic and the pathology is discovered incidentally during physical examination or CT and US. Although US and CT are normally adequate in diagnosing horseshoe kidney, the diagnosis may be overlooked due to the lack of perfusion in the region with a non-functioning kidney. IVP and pre-operative RGP may show different shapes and anterior rotation of renal pelvis and calices. So some kinds of congenital renal anomalies including horseshoe kidney could be suspected. In our case, left kidney contours could not be selected on IVP (Fig. 1) and no contrast matter was seen in the left renal area, because of the nonfunctioning kidney on the left side. However, the localization of blunted lower pole calyces close to the midline in IVP and prominent medial location with respect to right ureter were two main findings to be suspicious about a malrotated or cross ectopic or horseshoe kidney. The presence of a non functioning parenchyma in left kidney is the main reason why it is not seen on IVP and scintigraphy

which is a classic limitation. These images in all the radiologic examinations including the rotational anomaly and the blunt calyces have thought us the presence of any renal abnormality but we did not consider these evidences in terms of the horseshoe kidney. We performed RGP preoperatively it made us to think that it was a rotational anomaly rather than horseshoe kidney.

Complicated urinary tract infection is more common in horseshoe kidney due to the anatomical deformation. Investigating the underlying causes of recurrent urinary tract infections is important in terms of avoiding irreversible kidney damage.

The laparoscopic treatment approach can be used in anomalous kidneys as a horseshoe kidney [7,8,13]. However, it was not possible to make a diagnosis with preoperative investigations in the presented case. We returned to the open surgery method when we saw kidney parenchyma passing the midline during surgery. We encountered with a situation that can not be diagnosed before surgery. Additionally, we had not taken any preliminary measures to avoid the potential complications of partial nephrectomy.

In conclusion, the horseshoe kidney diagnosis can be overlooked due to the lack of renal perfusion during radiological imaging in patients scheduled for surgery

with a diagnosis of non-functional kidney. Therefore further examination should be either a contrast enhanced CT or MRI which reveals renal anatomy in detail. It would be useful to consider horseshoe kidney before forcing the tissue when live parenchyma

passing the midline is observed during surgery.

Acknowledgements

The author(s) declare that they have no competing interests and financial support.

REFERENCES

1. Salas M, Gelet A, Martin X, Sanseverino R, Viguier JL, Dubernard JM. Horseshoe kidney: the impact of percutaneous surgery. *Eur Urol.* 1992; 21(2): 134-7.
2. Jones DJ, Wickham JE, Kellett MJ. Percutaneous nephrolithotomy for calculi in horseshoe kidneys. *J Urol.* 1991;145(3): 481-3.
3. Esuvaranathan K, Tan EC, Tung KH, Foo KT. Stones in horseshoe kidneys: Results of treatment by extracorporeal shock wave lithotripsy and endourology. *J Urol.* 1991;146(5): 1213-5.
4. Fekak H, Mezzour MH, Rabii R, Joual A, Bennani S, El Mrini M. Management of horseshoe kidney based on a series of 36 cases. *Prog Urol.* 2004;14(4): 485-8.
5. Bozic B, Persec Z, Persec J, Borkovic Z, Galesic K. Diagnostic and treatment of renovascular hypertension in the patient with horseshoe kidney. *Acta Med Croatica.* 2005; 59(2): 137-42.
6. Borzi PA. A comparison of the lateral and posterior retroperitoneoscopic approach for complete and partial nephroureterectomy in children. *BJU Int.* 2001; 87(6): 517-20.
7. Bonnard A, Fouquet V, Carricaburu E, Aigrain Y, El-Ghoneimi A. Retroperitoneal laparoscopic versus open pyeloplasty in children. *J Urol.* 2005; 173(5): 1710-3.
8. El-Ghoneimi A, Farhat W, Bolduc S, Bagli D, McLorie G, Khoury A. Retroperitoneal laparoscopic vs. open partial nephroureterectomy in children. *BJU Int.* 2003; 91(6): 532-5.
9. Koikawa Y, Naito S, Uozumi J, Uemura T, Goto K, Ueda T, Kumazawa J. Percutaneous endopyelotomy for ureteropelvic junction obstruction in a horseshoe kidney. *Scand J Urol Nephrol.* 1996;30(2):145-7.
10. Cascio S, Sweeney B, Granata C, Piaggio G, Jasonni V, Puri P. Vesicoureteral reflux and ureteropelvic

- junction obstruction in children with horseshoe kidney; treatment and outcome. *J Urol.* 2002; 167(6): 2566-8.
11. Wilson C, Azmy AF. Horseshoe kidney in children. *Br J Urol.* 1986;58(4):361-3.
 12. Yilmaz E, Guney S. Giant hydronephrosis due to ureteropelvic junction obstruction in a child; CT and MR appearances. *Clin Imag.* 2002; 26(2):125-8.
 13. Yeung CK, Tam YH, Sihoe JD, Lee KH, Liu KW. Retroperitoneoscopic dismembered pyeloplasty for pelviureteric junction obstruction in infants and children. *BJU Int.* 2001; 87(6): 509-13

Access this article online

<http://pediatricurologycasereports.com>

Quick Response Code

