



Congenital anterior urethrocutaneous fistula: Report of two rare cases

Jayalaxmi Shripati Aihole, Narendrababu Munianjanappa, Gowrishankar

Department of Pediatric Surgery, IGICH Bangalore, Karnataka, India

Abstract Isolated congenital anterior urethrocutaneous fistula (CAUF) is a rare anomaly. CAUF can be defined as a fistula of the penile urethra associated with a normal foreskin, in which urethral meatus and prepuce are intact. Additionally, it may be associated with other anomalies such as congenital hernias and anorectal malformations. Treatment of CAUF is individualized according to site of fistula, associated anomalies and condition of the distal urethra. We are reporting our experience of two cases that had abnormal openings on the ventral aspect of distal penis with normal foreskin without hypospadias and chordee.

Key Words Penis; anterior urethra; congenital; urethrocutaneous fistula.

Copyright © 2015 [pediatricurologycasereports.com](http://www.pediatricurologycasereports.com).

Corresponding Author: Jayalaxmi S Aihole, M.D.,
Assistant Professor. Department of Pediatric surgery.
IGICH Bangalore, Karnataka, India.

E mail: jayalaxmisaihole@yahoo.com

Accepted for publication: 19 March 2015

INTRODUCTION

Congenital anterior urethrocutaneous fistula (CAUF) is an extremely rare anomaly and its earliest description was done by Campbell in 1951[1]. CAUF can be defined

as a fistula of the penile urethra associated with a normal foreskin, in which the urethra and external urethral meatus are intact, typically with intact prepuce and no history of any penile trauma including surgical trauma [2,3]. Only 41 cases have been reported in the English literature till date. It has also been described as an unusual type of hypospadias called cryptospadias [2,3]. CAUF is also associated with anorectal and

genitourinary anomalies. Most of CAUF are found in the localization coronal/subcoronal [3]. Surgical repair is required for all cases and is based on the principles of hypospadias repair. We report 2 cases of this rare anomaly with a review of the literature.

CASE REPORT

Case 1

A 1,5-years-old boy presented with passing urine from two orifices, one from the tip and other from the under surface of penis since birth. There was no history of surgical operation or trauma in the past. Physical examination revealed normal looking penis with a small (5mm x 4mm) fistula like opening under the ventral surface at distal penile area just distal to coronal sulcus (Fig. 1A).

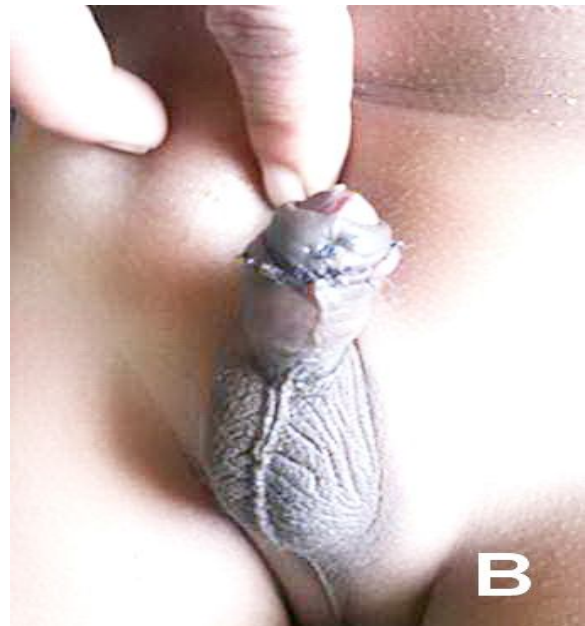
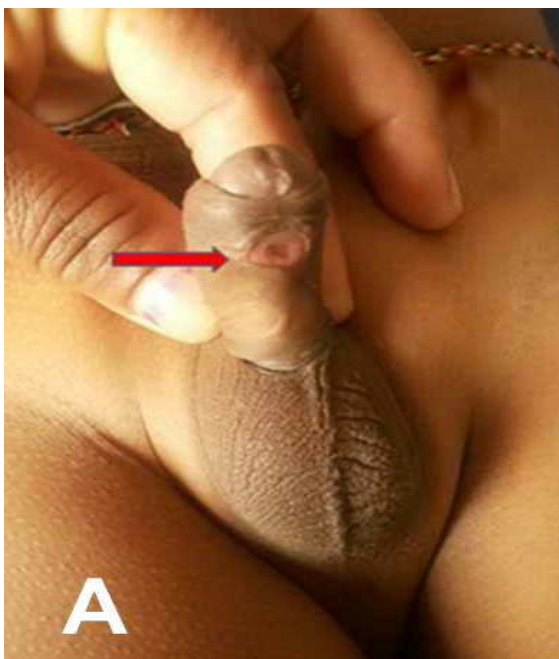

Fig.1. (A) Preoperative appearance of the case 1. Red arrow pointing at CAUF. (B) Postoperative appearance of the penis.

Glans penis and the prepuce were unremarkable without chordee. Further evaluation did not reveal any associated anomaly. Treatment included per-operative diagnostic cystoscopy which was normal and primarily closure of the fistula in multiple layers using local tissues. Postoperative period was uneventful and resulted in excellent outcome (Fig. 1B). Patient is doing well at 7 years follow up.

Case 2

A 3 years 9 months male child presented to our clinic with history of passing urine from under surface of penis since birth. No past history of trauma or any surgical procedures.

Patient was passing urine mostly from the fistula and had poor stream from the external meatus. He was otherwise healthy and had no other anomalies. Penile length, glans and prepuce were unremarkable without chordee. Ventrums of penis at its distal site (subcoronal) showed 8×4mm fistulous opening (Fig. 2A).

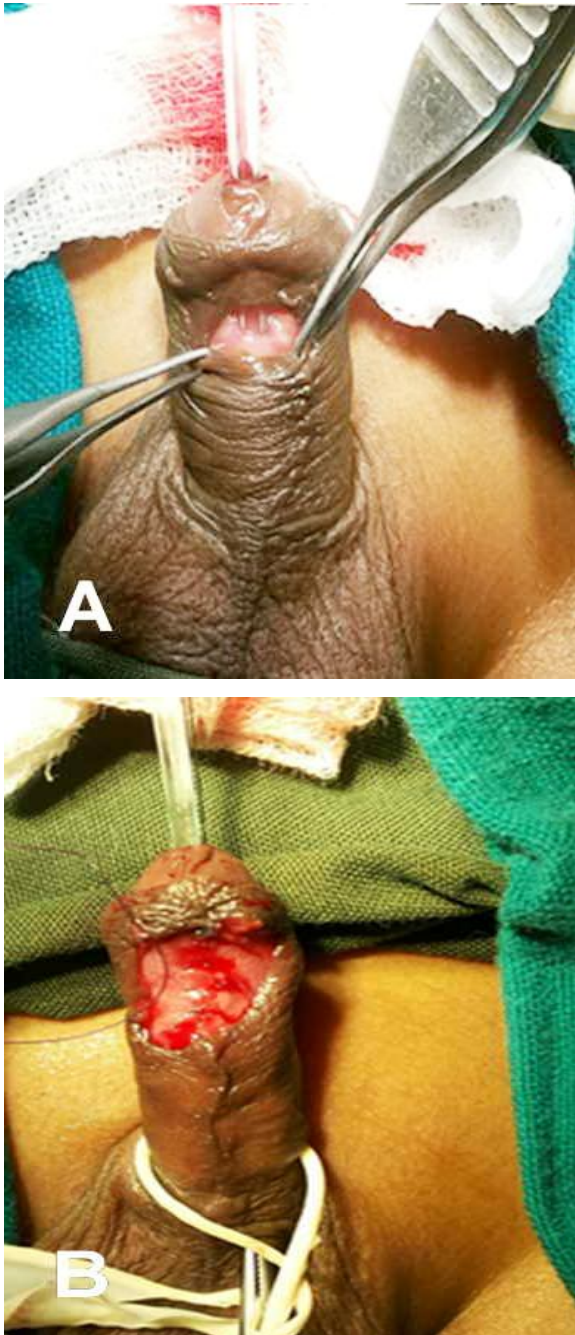


Fig. 2. (A). Fistula of case 2 before spongioplasty. (B). Appearance of the penis after spongioplasty.

Diagnostic cystoscopy was normal. Fistula was closed in a multilayer fashion with 6/0 vicryl over 10 Fr infant feeding tube (Fig. 2B). Catheter was removed on post-op day 7 and had good cosmetic appearance. He is doing fine at six months follow up.

DISCUSSION

Although the etiology of CAUF is not yet well established, to explain the pathogenesis several theories have been suggested. According to Campbell [1], CAUF describe congenital or embryonal urethral blowouts behind a distal congenital obstruction. Ritchey et al. [4] have suggested that the fistula resides in a focal or temporary defect in the urethral plate that prevents fusion of the urethral folds. Another proposal is pressure atrophy leading to pressure necrosis of urethra caused by the heel of the baby's foot [5,6]. Goldstein theorized that there is a transient deficiency or inhibition of the local effect of testosterone leading to the failed closure of the urethral groove [7]. Olbourne [8] proposed that a focal defect in the urethral plate results in arrested distal migration of the urethral plate or a localized deficiency of a portion of the plate. Mutations of activating

transcription factor (ATF3) and sonic Hedge Hog (SHH), fibroblast growth factor (FGFs) 8 and 10, an estrogens responsive gene, Ephrin-B2 and receptors have been implicated in the genesis of CAUF [9,10].

There are two types of CAUF. The first type is isolated fistula, which is associated with a normal foreskin, no chordee or hypospadias and an intact distal urethra and spongiosum as in our cases. The other type is associated with hypospadias-like characteristics, that is, chordee, a dorsal hood with or without distal urethra or spongiosal defect. Additionally, CAUF is uncommon as compared with posterior urethrocutaneous fistula, which usually represents Y-type duplication of the urethra with anorectal atretic malformations [11].

The diagnosis of CAUF is mainly clinical and it should be evaluated for other anomalies. Both of our patients were diagnosed clinically and did not have any other associated anomalies. The other diagnostic tool cystourethroscopy is used to rule out urethral duplications presenting as congenital urethral fistula. Cystourethroscopy was done per-operatively in both of our patients which was essentially normal.

The choice of surgical treatment depends on the location and the size of the fistula and other associated abnormalities. For isolated

cases of CAUF, simple closure like hypospadias fistula gives excellent results. Those cases of CAUF with varying spectrum of hypospadias require to be repaired as per principles of hypospadias [12]. Most commonly described procedures are Thiersch-Duplay tubularization or tubularization and incision of the urethral plate technique, pedicled island preputial tube or onlay urethroplasty, buccal mucosa urethroplasty, modified Denis Browne urethroplasty or direct closure [2,3,12-14]. In two cases presented in this study, primary closure was used for repair with success. In large fistulas, a flap may be better to avoid from recurrent fistula. The incidence of recurrence following repair is approximately 17% as per the reported literature [8,11,12]. As a result, isolated congenital anterior urethral fistula is extremely rare a congenital anomaly. Type of repair depends on the individual patient local anatomy. Additionally, anomalies associated with CAUF should be excluded before deciding surgical correction. Treatment is simple and straightforward in most of cases with excellent outcome.

Acknowledgements

The author(s) declare that they have no competing interests and financial support.

I would like to thank entire department of pediatric surgery, IGICH for the support and encouragement.

REFERENCES

1. Campbell M. Embryology of the Genito Urinary tract. In: Campbell M, editor. Clinical Paediatric Urology, 1st edn. Philadelphia: WB Saunders Co; 1951. pp. 531–6.
2. Caldamone AA, Chen SC, Elder JS, Ritchey ML, Diamond DA, Koyle MA. Congenital anterior urethrocutaneous fistula. *J Urol.* 1999; 162(4):1430-2.
3. Alhazmi HH. Congenital anterior urethrocutaneous fistula: Two case reports and review of literature. *Urol Ann.* 2014; 6(3):239-41.
4. Ritchey ML, Sinha A, Argueso L. Congenital fistula of the penile urethra. *J Urol.* 1994;151(4):1061–62.
5. Hutson JM. Congenital fistula of the penile urethra. *Br J Urol.* 1997;80(5):837.
6. Cook WA, Stephens FD. Pathoembryology of the urinary tract. In: King LR (ed.). *Urologic Surgery in Neonates and Young Infants.* Saunders, Philadelphia; 1988. p. 123.
7. Goldstein M. Congenital urethral fistula with chordee. *J Urol.* 1975;113(1):138-40.
8. Olbourne NA. Congenital urethral fistula. *Plast Reconstr Surg.* 1976;57(2):237-9.
9. Dravis C, Yokoyama N, Chumley MJ, et al. Bidirectional signaling mediated by ephrin-B2 and EphB2 controls urorectal development. *Dev Biol.* 2004;271(2):272-90.
10. Kalfa N, Liu B, Klein O, Wang MH, Cao M, Baskin LS. Genomic variants of ATF3 in patients with hypospadias. *J Urol.* 2008;180(5):2183-8.
11. Karnak I, Tanyel FC, Hiçsönmez A. Congenital urethrocutaneous fistula: a case report and literature review, with a nomenclature proposal. *J Pediatr Surg.* 1995;30(10):1504-5.
12. Bhatnagar A, Upadhyaya VD, Kumar B. Congenital urethrocutaneous fistula: Case report with review of literature. *Indian J Plast Surg.* 2012; 45(3):563-5.
13. Spinelli C, Pucci V, Menchini C, et al. A congenital anterior urethrocutaneous fistula in a boy whose mother was exposed to ionizing radiations: case report and literature review. *Case Rep Urol.* 2013; 2013:525386.

14. Ozdemir T, Karagozoglu A, Sayan A, Koyluoglu G. Congenital fistula of the penile urethra: A case report. *Ped Urol Case Rep.* 2014;1(3):6-9.

Access this article online

<http://pediatricurologycasereports.com>

Quick Response Code

