

Severe, chronic and recalcitrant atopic dermatitis associated with *Tinea capitis*: Diagnostic approach and effects of topical *Vernonia amygdalina* Del. extracts

Nlandu Roger Ngatu^{*}, *****, Mimi Mukuamu^{**}, Ryoji Hirota^{*}, Luzitu Severin Nangana^{***}, Benjamin Longo-Mbenza^{***} and Narufumi Suganuma^{*}

^{*} Department of Environmental Medicine, Kochi University Medical School, Nankoku, Japan

^{**} Service de Dermatologie, HopitalGénéral de Kinshasa, RépubliqueDémocratique du Congo

^{***} Centre hospitalierNdeko-Basile, Kinshasa, RépubliqueDémocratique du Congo

^{****} Department of Health Sciences, Walter Sisulu University, Mthata, South Africa

^{*****} Disaster Nursing Global Leader doctoral Program (DNGL), Graduate School of Health and Nursing Science, University of Kochi, Kochi, Japan

Received March 11, 2014; Revised April 21, 2014; Accepted May 1, 2014; Published online June 30, 2014

Abstract

We report on a 5-year old girl from Mbanza-Ngungu (formerly Thysville), a Congolese rural city, who developed atopic eczema skin lesions during infancy and which, later on, became recalcitrant despite a long period treatment with some steroid preparations, zinc oxide and also local ethnomedicine products. She was first diagnosed with psoriasis by the first doctor 4 years before. At the admission, she presented with severe lichenification, oozing, swelling and hyperpigmentation on large areas of upper and lower limbs and trunk. Her skin condition has seriously affected her quality of life and she had an associated *Tinea capitis*. After a careful history taking, physical examination and use of the Haniffin and Rajka AD diagnostic criteria while considering the localization of skin lesions, the diagnosis of severe and recalcitrant atopic eczema was considered. She was treated with a twice daily application of 10% *Vernonia amygdalina* extracts, an African edible plant that exerts anti-itch and antiallergic activities. And *Tinea capitis* was successfully treated with 3 week topical 2% *Miconazole*. A marked improvement of eczema area severity index (EASI) and dermatological life quality index (DLQI) was noted 3 weeks later, with reduction of total serum IgE, eosinophilia and erythrocytes sedimentation rate (ESR) at day40 of treatment. An improvement of the country's health system and provision of specialized health care in the rural areas could help to prevent misdiagnosis of treatable diseases in poor settings.

Key words : Atopic eczema, *Tinea capitis*, inflammation, itch, lichenification, *Vernonia amygdalina* extracts

1. Introduction

Atopic dermatitis (AD) is an itchy, inflammatory skin condition with a predilection for skin flexures. In the chronic stage, the disease is characterized by erythema, edema, vesicles and weeping and skin lichenification or thickening (Williams, 2005; Aoki *et al.*, 1992). AD is a complex disease that relies on the interplay of several factors; and, both environmental (allergens and other triggers) determinants and genetic factors are reported to play an important role in the disease onset and aggravation, and 15-20% of children are affected in developed countries (Nemoto-Hasebe *et al.*, 2009; Olesen *et al.*, 2003; Scharschmidt *et al.*, 2009).

A 5-year-old girl from the rural city of Mbanza-Ngungu (formerly Thysville), Bas-Congo province, Democratic Republic of Congo, has been suffering from AD since infancy, nearly before reaching her second year of life. According to her mother, the child first presented with redness of the skin and papulous lesions on upper limbs; she also revealed that one of her relative often suffers from skin allergy. Later on, similar skin lesions developed on lower limbs, progressively extending to the trunk as the patient grew older, and she was often scratching.

At the first local medical setting she visited, the mother was told by the doctor that her daughter had psoriasis. Thereafter, she had to see different doctors; however, there was still no improvement of the child's condition. Topical steroids (including betamethasone) and zinc oxide were among the drugs prescribed. Since 2009, her parents have been seeing traditional practitioners and healers, as the medications from hospitals did not improve the patient's condition. However, her condition worsened with extended dyschromic lesions and lichenification on her upper and lower limbs.

Author for correspondence: Dr. Ngatu Nlandu Roger
Kochi Medical School, Kochi University. *Oko-cho, Nankoku-city,*
zip-code: 783-8505, Kochi, Japan

E-mail: doc.rogerngatu@gmail.com

Tel.: +81-9097782097

Fax: +81-88-880-2407

Copyright © 2014 Ukaaz Publications. All rights reserved.
Email: ukaaz@yahoo.com; Website: www.ukaazpublications.com

2. Materials and Methods

2.1 Physical examination and diagnosis

From November 2010 through April 2011, our Congolese-Japanese collaborative research team conducted a dermatological screening, followed by a preliminary clinical trial that consisted on providing healthcare for allergic skin diseases in Bas-Congo province, Democratic Republic of Congo, to patients with mild to moderate conditions. Miss B, a 5-year old girl, was accompanied by her mother to one of our study sites. She was taken care by our team but was not recruited in the study because of the severity of her condition and also she had an associated fungal skin disease.

The history of her disease goes back to the time she was nearly 2 years old. Her parents have visited different medical settings as mentioned above. They also visited traditional practitioners and healers who have been using different plant materials as remedy; however, the kid's condition was getting worse. At the admission, she presented with oozing, lichenification squamous lesions, swelling of skin, scratch markings, and hyperpigmentation of skin on the antecubital fossae, legs and back (Figure 1A) she also had difficulty to walk due to thickened and painful lesions on her knees.

The girl was wearing clothing that covered almost her entire body and was avoiding playing with friends. In addition, the patient had mycotic skin lesions on her head. After a careful history taking and physical examination, and considering the Haniffin and Rajka's AD diagnostic criteria and the distribution of skin lesions (limbs, trunk and back), we concluded that she had a severe, chronic and recalcitrant atopic dermatitis associated with *Tinea capitis* (a common fungal skin infection in Congolese rural children). The disease (AD) severity was evaluated using the 'eczema area and severity index' (EASI) scoring system, as previously reported (Hanifin *et al.*, 2001), considering the severity of each skin symptom (redness, thickness, scratching and lichenification: 0, absence; 1, mild; 2, moderate; 3, severe) localized on neck/head, trunk, upper and lower limbs; in addition, a patient self-evaluation of dermatology quality of life index (DQLI) (Chen, 2007) was performed once a week by interviewing the mother.

2.2 Hematologic, immunologic assays and mycological culture

Blood sample was drawn on day1 and 6 weeks later (day40) for biological and immunological (total IgG, IgE), hepatic function (alanine aminotransferase, ALT; aspartate transaminase, AST) assays. White blood cells count and erythrocytes sedimentation rate (ESR) assays were performed at a local health center (Noki hospital, Bas-Congo province), whereas immunologic and hepatic function markers were assayed at a specialized laboratory (Lomo Medical laboratory, Kinshasa, Congo DR). Potassium hydroxide (KOH) microscopy was positive and mycological culture (Sabouraud' dextrose agar; Saruta clinic of dermatology, Japan) of collected scalp samples isolated *Trichophyton canis*.

2.3 Treatment

As the patient has a history of an unsuccessful *betamethasone* and *dexamethasone* treatment-the only drugs available in this resource limited rural area-she was treated, twice daily, with topical application of 10% *Vernonia amygdalina* extracts (Vamex) (African edible plant with antiallergic properties) ointment. *Tinea capitis* was successfully cured after a three-week topical 2% *miconazole*

treatment. No other medication was added until completion the 8-week treatment period.

2.4 Ethical consideration

The ethics committee of Kochi Medical School approved the study protocol of the clinical study (Ethics committee No 22-59) and a written approval from the provincial medical authority was obtained. Regarding patient B, a verbal informed consent was obtained from the child's mother, an illiterate farmer.

3. Results and Discussion

A marked improvement was noted for lesions on upper and lower limbs, neck and trunk and back (Figure 1B) with an improvement of the disease severity (EASI score: 38.4 vs. 6.2 at day1 and day40, respectively) and life quality (DLQI: 16 vs. 34; respectively). She was no more scratching and could walk and even run. Results from the hematologic and immunologic assays were as follows (Figure 2):

- Leukocytes: eosinophils: 5 vs. 2%, basophils: 2 vs. 0%, lymphocytes: 32 vs. 27%; monocytes: 6 vs. 3%; neutrophils: 61 vs. 53 on day1 and day40, respectively;
- ESR: 51 mm/h vs. 32 mm/h, respectively;
- WBC: 11,200 vs. 9,700/ mm³, respectively;
- Total IgG: 42 IU/L vs. 38 IU/L, respectively;
- Serum total IgE: 0.023 vs. 0.002 IU/L, respectively;
- Serum ALT: 26 IU/L vs. 24 IU/L; serum AST: 17 vs. 19 IU/L, respectively.

No adverse effect was neither observed by the clinician nor reported by the patient or her parent during the course of treatment.

After a long period of discomfort due severe skin lesions, our patient's condition could improve following the use of topical *Vernonia amygdalina* extracts. This amelioration of the severity of the disease might be related to:

- the decrease in serum total IgE level; this immunoglobulin is associated with the development of AD in most cases through upregulation of inflammatory allergic inflammation-dependent Th-2 cytokines production (Rybojad, 2012; Tanei, 2012);
- the potent anti-inflammatory activity of its bioactive flavonoids (*Quercetin*, *Luteolin*, *Dicaffeoylquinic acid*) and terpenoids such as *Vernodalinalol*, from *Vernonia amygdalina* leaf, which exert an inhibitory effect of ERK/MAPK pathways. Those chemicals are reported to confer to the plant its anti-inflammatory and anticancer properties (Oyugi *et al.*, 2009; Toyang and Verpoorte, 2013; Luo *et al.*, 2011). Our recent study demonstrated the antiallergic activity of both water and alcoholic extracts of the Congolese *Vernonia amygdalina* in animals and humans (Ngatu *et al.*, 2012).

There are some lessons to be considered in this report, which consists of a patient taken care in an area where specialized healthcare is particularly rare and more than half of population rely on traditional practitioners and healers. The misdiagnosis of the patient's condition could be due to the limited skills of general practitioners in the field of skin diseases, and, on the other hand, the lack of specialist doctors in hospitals located in most rural cities. Actually, Haniffin and Rajka diagnostic criteria for AD are used internationally. It is a useful tool in the differential diagnosis of eczematous and other itch and /or skin barrier defect associated skin diseases like AD.

The patient condition got worsened possibly due to lack of adherence to previously prescribed treatments (steroids) rather than their ineffectiveness, which might have made her condition recalcitrant. Furthermore, the use of plant materials that had no proven efficiency by traditional practitioners and healers could have aggravated skin lesions that we observed at the time of patient's admission. Though there were a few dyschromic spots on her lower limbs remaining after 8 weeks of treatment, our patient's condition improved considerably and no adverse effect was noted. An improvement of the country's health system and provision of specialized health care in the rural areas could help prevent misdiagnosis of treatable diseases in poor settings.

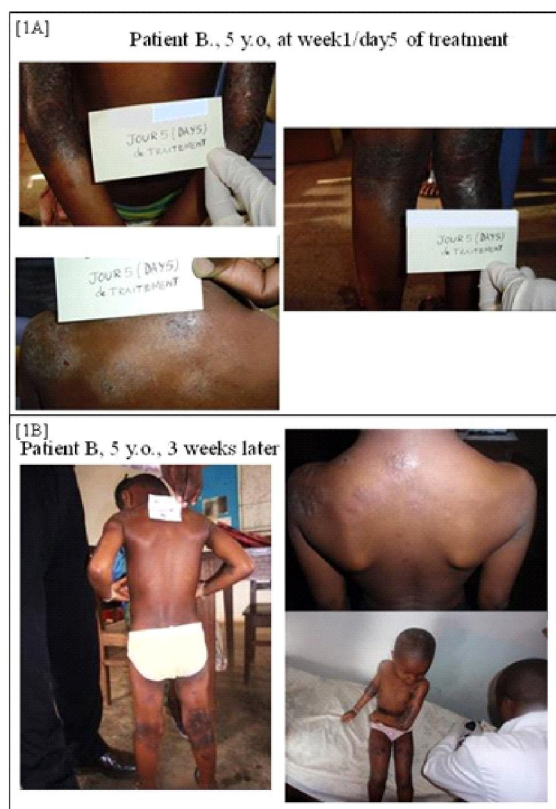

Figure 1A: Affected body areas at day5 (week1) (a) and at day21 (b) after starting topical treatment with 10% Vamex (*Vernonia amygdalina* leaf extracts) in a 5-year old Congolese girl

The Figure shows an improvement of patient's skin condition with a marked reduction of lichenification and areas of dyschromia both on upper and lower limbs, with a re-epithelization of previously affected body areas after 6 weeks of topical VAM extracts treatment.

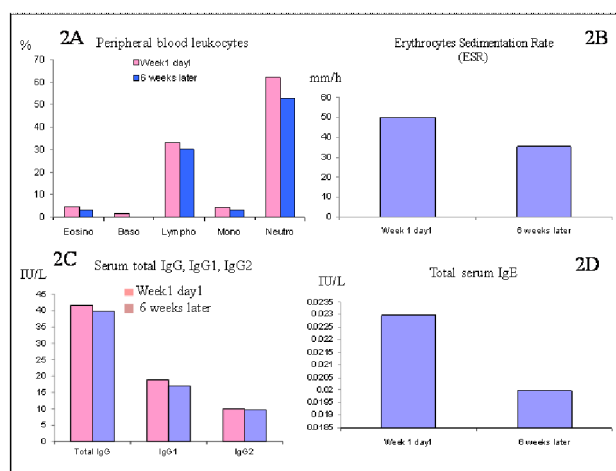


Figure 2: White blood cells count, ESR, serum total IgG, IgG1, IgG2 and IgE levels

The Figure shows relatively reduced levels of blood leucocytes (WBC) (A), ESR (B), total serum IgG, IgG1, IgG2 (C) and IgE (D) after 3 weeks of topical treatment with *Vernonia amygdalina* leaf extracts

As a conclusion, this report suggests that *Vernonia amygdalina* leaf extracts could be beneficial as antiallergic agent in humans. This finding should be confirmed only after conducting a clinical trial with large sample of patients.

Acknowledgment

The authors thank all office staff of the Department of Environmental Medicine, Kochi Medical School, and Dr Takao Saruta for their wonderful support. In addition, we thank the Yamada bee farm staff who provided necessary materials and equipment for this research project.

Conflict of interest

We declare that we have no conflict of interest. Financial support statement: the main study was supported by the Yamada bee farm research grant 2010-2011, Okayama, Japan.

References

- Aoki, T.; Fukuzumi, T.; Adachi, J.; Endo, K. and Kojima, M. (1992). Re-evaluation of skin lesion distribution in atopic dermatitis: analysis of cases 0 to 9 years of age. *Acta. Derm.Venereol. (Stockh)*, **176**:19-23.
- Chen, S.C. (2007). Dermatology Life Quality Instruments: sorting out the quagmire. *Journal of Investigative Dermatology*, **127**: 2695-2696.
- Hanifin, J.M.; Thurston, M.; Omoto, M.; Cherill, R.; Tofte, S.J. and Graeber, M. (2001). The eczema area and severity index (EASI): assessment of reliability in atopic dermatitis. *EASIE valuator Group. Exp. Dermatol.*, **10**(1):11-8.
- Luo, X.; Jiang, Y.; Fronczek, F.R.; Lin, C.; Izevbigie, E.B. and Lee, K.S. (2011). Isolation and structure determination of a sesquiterpene lactone (Vernodalinol) from *Vernonia amygdalina* extracts. *Pharm. Biol.* **49**(5):464-470.

- Nemoto-Hasebe, I.; Akiyama, M.; Nomura, T.; Sandilands, A.; McLean, W.H.I. and Shimizu, H. (2009). Clinical severity correlates with impaired barrier in filaggrin-related eczema. *Journal of Investigative Dermatology*, **129**:682-689.
- Ngatu, N.R.; Okajima, M.K.; Yokogawa, M.; Hirota, R.; Takaishi, M.; Eitoku, M. (2012). Anti-allergic effects of *Vernonia amygdalina* leaf extracts in hapten-induced atopic dermatitis-like disease in mice. *Allergology International*, **61**:597-607.
- Olesen, A.B.; Juul, S. and Thestrup-Pedersen, K. (2003). Atopic dermatitis is increased following vaccination for measles, mumps and rubella or measles infection. *Acta. Derm.Venereol*, **83**:445-450.
- Oyugi, D.A.; Luo, X.; Lee, K.S.; Hill, B. and Izevbigie, E.B. (2009). Activity Markers of the Anti-Breast Carcinoma Cell Growth Fractions of *Vernonia amygdalina* Extracts. *Exp. Biol. Med.*, **234**:410-417.
- Rybojad, M. (2012). Atopic dermatitis. *Arch. Pediatr.*, **19**(8):882-5.
- Scharschmidt, T.C.; Man, M.Q.; Hatano, Y.; Crumrine, D.; Gunathilake, R. and Sundberg, J.P.(2009). Filaggrin deficiency confers a paracellular barrier abnormality that reduces inflammatory thresholds to irritants and haptens. *J. Allergy. Clin Immunol.*, **124**(3):496-506.e6.
- Tanei, R.; Hasegawa, Y. and Sawabe, M. (2012). Abundant immunoglobulin E-positive cells in skin lesions support an allergic etiology of atopic dermatitis in the elderly. *J. Eur. Acad. Dermatol.Venereol*, doi., **10.1111/j.1468-3083.2012.04612.x**.
- Toyang, N.J. and Verpoorte, R. (2013). A review of the medicinal potentials of plants of the genus *Vernonia amygdalina* (Asteraceae). *Journal of Ethnopharmacology*, **146**:681-723.
- Williams, H.C. (2005). Atopic dermatitis. *N. Engl. J. Med.*, **352**: 2314-2324.