



Original Article

Evaluation of Gastrointestinal Helminths of Native Turkeys in Amol, Iran

ShahrokhRanjbarBahadory¹, Nasser Hoghoghi Rad¹, Ammar Ramezani^{2*}, Daryoush Babazadeh³
Sepideh Falah⁴, Samere Ghavami⁵

¹DVM, PhD Department of Parasitology, Faculty of Veterinary Medicine, Science and Research Branch, Islamic Azad University, Tehran, Iran.

²MS Student, Student of Veterinary medicine, Science and Research Branch, Islamic Azad University, Tehran, Iran.

³DVM, PhD Student, Avian Diseases Research Center, School of Veterinary Medicine, International Division, Shiraz University, Shiraz, Iran.

⁴DVM Graduated of Veterinary Medicine, Tehran University, Tehran, Iran.

⁵DVM, PhD Student, Avian Diseases Research Center, School of Veterinary Medicine, Shiraz University, Shiraz, Iran.

*Corresponding author's Email: Ammar.ramzani@gmail.com

ABSTRACT

Native turkeys are kept as domestic bird in rural environments and can be infected with bacterial, viral and parasitic agents. *Capillaria* and *Ascaridia* are nematodes of small intestines of domestic birds such as turkey. Small intestine trematode of birds like echinostomiasis need intermediate hosts for evolution. *Raillietina tetragona* and *Raillietina echinobothrida* are parasites in small intestines of birds. These parasites can cause economic loss and create problems for turkey. The purpose of this study was to determine the genus and species, frequency and severity of gastrointestinal helminth parasites. Gastrointestinal of 60 slaughtered turkeys of Amol city were necropsied and examined. 25% of the samples were not contaminated and 75% of samples were infected with nematode, cestode and trematode. Prevalence and parasite species, including: 20% *Capillaria*, 51% *A. gali*, 8% *R. tetragona*, 8% *R. echinobothrida* and 11% *Echinostoma*. The results indicated that the highest prevalence of helminth parasites in turkeys of Amol and north of Iran was nematode.

Key words: Turkey, Helminth, gastrointestinal, Amol

INTRODUCTION

Chicken, duck and turkey are most birds that are kept as domestic bird in rural environments. The gastrointestinal tract plays an important role in digestion and absorption of foods so any changes in intestinal health and digestion due to lack of proper absorption of food and the growth performance and production will be disrupted. Bacterial, viral, parasitic and some non-infective agents such as management problems and nutritional deficiencies can cause intestinal problems in turkeys (Hafez, 2011). There are risk factors of parasitic infection (including protozoa, arthropods, worms, etc) in rural poultry because they are in contact with outdoor environments. Santoro et al. (2010) detected helminth infestation at post mortem examination in 95% of birds and pathological changes associated with helminthes in 74% of infected birds in Southern Italy.

Capillaria is a nematode of small intestines of domestic and wild birds such as chicken, geese, duck, guinea fowl that cause weight loss, diarrhea and economic losses in severe infections (Hogue et al.

2014). *Ascaridia gali* is a nematode of small intestines of domestic and wild birds which worldwide distribution and in severe infections causing diarrhea, decreased egg production, emaciation and anemia (Yadav et al., 1991). *Echinostomais* trematode of small intestine of birds and the infections are in areas of the world where there are suitable conditions for the growth of intermediate host (snails). *Raillietina tetragona* and *Raillietina echinobothrida* are parasites in the small intestines of birds (including chicken, turkey, quail and pheasant) and these infections have been spread world wide (Vattanodorn et al., 1984).

Amol city is located in northern Iran and in south of Caspian Sea. The temperate climate, rainfall humidity and ambient temperature provide optimum conditions to maintain helminth population and intermediate hosts. The purpose of this study is identify the species and prevalence of helminth parasites in the digestive system of native turkeys in Amol city, Iran.

MATERIALS AND METHODS

In this study, samples were obtained randomly from gastrointestinal tract of 60 native turkeys that these were slaughtered during February and March, 2014. The turkeys randomly obtained from many villages of Amol city, Iran. The samples were classified according to sex and age (month). The age of the turkeys was classified into three groups (A) 2-6 month, (B) 6-10 month, (C) 10-14 month (Table 1).

Table 1. Age and sex distribution of selected native turkeys of Amol city, Iran

Age (month)	Male	Femal	Total
2-6	8	19	27
6-10	7	14	21
10-14	5	7	12
Total	20	40	60

The gastrointestinal tracts of turkeys were isolated completely after slaughtering. To prevent mixing of the contents of intestines, beginning and end of crop, stomach, gizzard, small intestine, large intestine and secums were tied and transferred to laboratory for examination. At autopsy, each segment was opened with a fine scissor and placed in separate petri dishes containing normal saline. The contents were washed with distilled water through a strainer while the deposits were transferred to petri dish for examination. The mucosa was scrapped in order to collect the embedded worms in the mucosal layer of crop, proventriculus, gizzard and intestines. Isolation of gizzard worm was preceded by peeling off the

keratin layer. All worms were picked, recorded and stored in universal bottles containing alcohol-glycerine. All helminths were identified by morphological characters according to the description of Soulsby (Soulsby, 1982). After staining with acetocarmine, slides were observed by light microscope to identify the heminth parasites (nematode, trematode, cestode).

RESULTS AND DISCUSSION

Species of parasites

In the acetocarmine staining coloring from sample contents of the digestive system, positive examples of two species of nematodes, two species of cestodes and one species of trematode were reported (Table 2). In a study Eslami et al. (2008) reported 96% of domestic poultry in Golestan province, Iran and near to Caspian sea were infected with at least one of the parasites. Also, Radfar et al. (2011) reported that 93.23% native chicken in Sistan province (Iran) were infected with 10 species nematodes, cestodes and ectoparasites. The nematodes recovered were *Ascaridia gali* and *Capillaria spp.* The cestodes recovered were *R. tetragona* and *R. echinobothrida* and the trematode recovered was *Echinostoma spp.*

Total worm count

The results indicated 25% of the samples were not contaminated and 75% of samples were infected with nematode, cestode and trematode. The highest worm count was nematode (53.3%) while trematode was the lowest worm count (8.3%) (Table 2). Magbool et al. (1998) noted that nematodes infection in broiler and native poultry was high prevalence in Fasilabad, Pakistan.

Table 2. Total worm count of the intestinal contents of selected native turkeys in Amol city, Iran

Types of parasites		Absolute frequency (%)	Relative abundance (%)
Nematode	<i>Capillaria</i>	9 (15%)	32 (53.3%)
	<i>A. gali</i>	23 (38.3%)	
Cestodes	<i>R. tetragona</i>	4 (6.7%)	8 (13.3%)
	<i>R. echinobotrída</i>	4 (6.7%)	
Trematode (<i>Echinostoma</i>)		5 (8.3%)	5 (8.3%)
Non infected		15 (25%)	

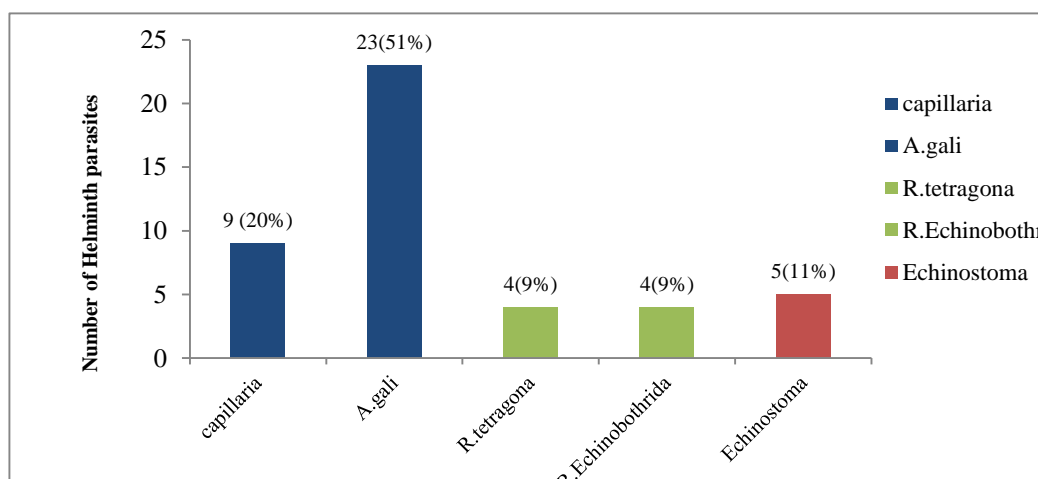


Diagram 1. Prevalence of intestinal parasites of native turkey based on type, genus and species in Amol city, Iran.

The prevalence of helminth parasites based on type, genus and species are summarized in Diagram 1 that indicated the highest prevalence of helminth parasites among infected samples was *Ascaridia gali* (51%) while *Raillietina tetragona* and *Raillietina echinobothrida* had the lowest prevalence (9%). There are many studies that reported the high prevalence of *Ascaridia gali* in native birds, Yadav et al. (1991) reported that *Ascaridia gali* was the most common nematode in native chickens in India. Another survey of gastrointestinal parasitic infection was performed among domestic and wild birds in Bangladesh that was determined parasites with *Capillaria*, *Heterakis* and *Ascaridia* (Hogue et al. 2014). The two species of cestodes which were found in present study have been reported by Vattanodorn et al. (1984). In a study *Raillietina echinobothrida* reported as the most common cestode in chickens (Saniet, 1986). But in some other studies *R. tetragona* reported as the most frequent cestode in chickens (Shanta, 1971; Amin-Babjee et al., 1994). The prevalence of the only trematode (*Echinostoma*) of infected samples was higher than cestodes but it was too lower than nematodes which was the only trematode species reported by Shanta (1971).

CONCLUSION

Poultry can easily be infected with diseases mainly caused by parasitic pathogens. However, parasitic infections (nematodes, cestodes and trematode) are often neglected. It often constitutes to low productivity and impairs the health status of poultry. Present study revealed helminth infections of turkeys in Amol city that is due to poor hygiene, the lack of anti-parasite treatment and poor hygiene nutrition. However the prevalence of helminth parasites in native poultry particularly in turkey need to more investigation. The literature review showed that most of studies were case report and restricted to a sudden occurrence or outbreak, thus further research should be designed for controlling intestinal parasites in native and rare poultry.

REFERENCES

- Amin-Babjee SM and Lee CC, (1994). Parasites of the fighting breed of domestic chicken, *Gallus gallusdomesticus*. In: Applied Biology beyond the Year 2000. Third Symposium of Malaysian Society of Applied Biology, Malacca. pp. 16-18.
- Eslami A, Ghaemi P and Rahbari S, (2008). Parasitic Infections of free- Range chicken from Golestan Province. Iranian Journal of Parasitology 4(3): 10- 14.
- Hafez HM, (2011). Enteric Diseases of Poultry with Special Attention to *Clostridium perfringens*. Pakistan Veterinary Journal, 31(3): 175-184.
- Hoque MA, Hassan MM, Haque E, Shaikat AH, Khan SA, AlimA, Skerrat LF, Islam A, Tun HM, Dissanayake R, Day TK, Debnath NC and Yamage M, (2014). A survey of gastrointestinal parasitic infection in domestic and wild birds in Chittagong and Greater Sylhet, Bangladesh. Preventive Veterinary Medicine, 117: 305-312.
- Magbool A, Ahmad M and Raza A, (1998). Prevalence of helminth parasites of poultry under different management conditions. Journal Faculty of veterinary university of Tehran, 53 (2): 102- 103.
- Radfar MH, Khedri J, Adinehbeigi K, Nabavi R and Rahmani K, (2011). Prevalence of parasites and associated risk factors in domestic pigeons (*Columba liviadomestica*) and free-range backyard chickens of Sistan region, east of Iran. Journal of parasitic diseases, 36(2): 220- 225.
- Sani RA, Harisah M and Bohari Y, (1986). Parasites of the indigenous fowl (*Gallus gallusdomesticus*) in Selangor. KajianVeterinar, 18: 183-189.
- Santoro M, Tripepi M, Kinsella JM and Mattiucci S, (2010). Helminth infestation in birds of prey (*Accipitriformes* and *Falconiformes*) in Southern Italy. The Veterinary Journal, 186: 119-122.
- Shanta CS, Song CY and Wan SP, (1971). Helminth parasites of the alimentary tract of broilers in North Malaya. Malaysian Veterinary Journal, 15: 1-8.
- Soulsby EJJ, (1982). Helminths, Arthropods and Protozoa of Domesticated Animals (Seventh Edition of Mönning's Veterinary Helminthology and Entomology). Baillière, Tindall and Cassell Ltd. pp. 5-683.
- Vattanodorn S, Inder-Singh K and Krishnasamy M, (1984). A preliminary survey of helminthendoparasites of the domestic fowl *Gallus domesticus* L. from aborigine settlements with some new records. Malaysian Veterinary Journal, 8: 13-18.
- Yadav AK and Tandon V, (1991). Helminth parasitism of domestic fowl (*Gallus domesticus* L.) in a subtropical high- rainfall area of India. Beitr Trop Landwirtsch Veterinarmed, 29: 97-104.