

Actinomyces Odontolyticus - Associated Bacteremia

Anika Považan¹, Anka Vukelic¹, Nevena Secen^{2,3}, Danica Sazdanic-Velikic², Daliborka Bursac²

¹Institute for Pulmonary Diseases of Vojvodina, Center for Microbiology, Immunology and Virology, Sremska Kamenica, Serbia; ²Institute for Pulmonary Diseases of Vojvodina, Pulmonary Oncology Clinic, Sremska Kamenica, Serbia; ³Faculty of Medicine, University of Novi Sad, Department of Internal Medicine, Novi Sad, Serbia

Abstract

Citation: Považan A, Vukelic A, Secen N, Sazdanic-Velikic D, Bursac D. *Actinomyces Odontolyticus* - Associated Bacteremia. Maced J Med Sci. 2012 Oct 15; 5(3):324-327. http://dx.doi.org/10.3889/MJMS.1957-5773.2012.0242.

Key words: *Actinomyces odontolyticus*; opportunistic infection; bacteremia; immunosuppression; lung malignancy.

Correspondence: Dr. Anika Považan, Institute for Pulmonary Diseases of Vojvodina, Center for Microbiology, Immunology and Virology, Put doktora Goldmana 4, Sremska Kamenica 21204, Serbia. Phone: +381/21/4805348, Fax: +381/21/527960. E-Mail: anikapovazan@yahoo.com

Received: 03-Apr-2012; Revised: 08-May-2012; Accepted: 09-May-2012; Online first: 23-Sep-2012

Copyright: © 2012 Považan A. This is an open-access article distributed under the terms of the Creative Commons Attribution License, which permits unrestricted use, distribution, and reproduction in any medium, provided the original author and source are credited.

Competing Interests: The author have declared that no competing interests exist.

Many *Actinomyces* species are part of the oral microflora of humans. *Actinomyces odontolyticus* - associated infections are exceptionally rare, presenting an endogenous infection originating from mucous membranes. Immunodeficiency is often complicated by severe opportunistic bacterial infections leading to critical condition of the patient. We report a case of an immunosuppressed patient with fever and *Actinomyces odontolyticus* bacteremia. The patient poorly responded to the applied antimicrobial therapy and did not recover.

Introduction

Actinomyces odontolyticus is a Gram-positive, facultative anaerobic bacterium [1, 2]. It was initially isolated from dental caries in 1958. As other *Actinomyces* species, this organism colonizes the oral cavity [1]. The most significant pathogen of the genus *Actinomyces* is *Actinomyces israelii*, which causes actinomycosis of the cervico-facial, thoraco-pulmonary and abdominal region

[1, 3]. Most frequently, *Actinomyces israelii* enters the body either through a damaged skin or mucosa, or via inhalation [3]. *Actinomyces odontolyticus* infections are exceptionally rare, presenting an endogenous infection arising most frequently from mucous membranes. Clinically the disease caused by *Actinomyces odontolyticus* closely resembles to the disease caused by *Actinomyces israelii* and other representatives of the genus. Pulmonary infections [4], bacteremia [2] and

abscess of various organs [1, 5-7] caused by this pathogen have been reported.

Case presentation

A 62-year male patient was admitted to hospital to enlighten the etiology of the lesion presented on his chest X-ray, localized in the right upper lobe. He reported a two-month history of back pains, fatigue, exhaustion, appetite and body mass losses (8 kg in two months). Having noticed a tumorous lesion on the patient's chest X-ray (Figure 1, 2), chest computed tomography (CT) was performed delineating an infiltration of 27 mm in

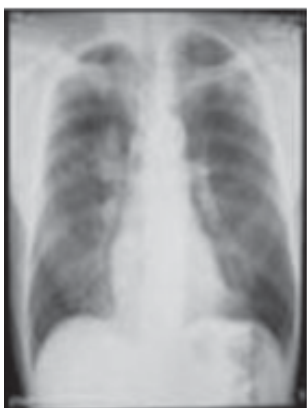

Figure 1: PA chest X-ray at the first day of hospitalization.

diameter localized in the right upper lobe, with adjacent reactive pneumonitis and a few micronodular subpleural lesions contralaterally, the 9th rib fracture with infiltrated pleura and subpleural fat tissue, as well as enlarged retrocaval, bronchopulmonary lymph nodes on the right, and those in the subcarinal region (Figure 3).

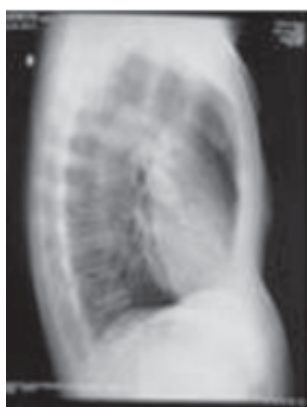


Figure 2: Profile chest X-ray at the first day of hospitalization.

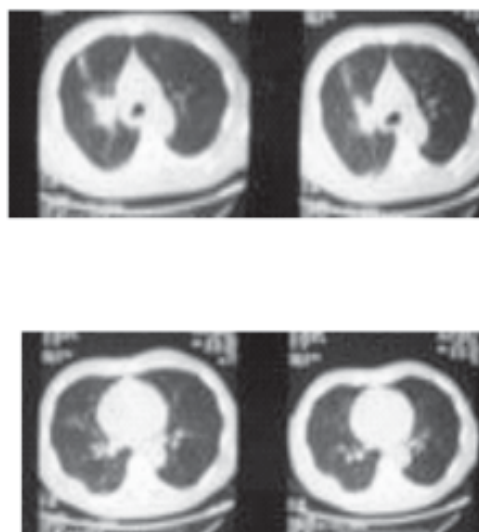


Figure 3: CT chest X-ray.

Bronchoscopy was performed, and the histopathological finding of the biopsy samples taken from the right upper lobe confirmed adenocarcinoma. Due to the right jaw and right lower leg pains, scintigraphy of the skeleton was performed, detecting pathological hyperfixation foci in the projection of the right parietal bone, along all spinal column segments, bilaterally in the ribs, shoulder region bones, left humerus diaphysis, sacroiliac joint and proximal femur tips. Due to the advanced stage of the disease, the chemotherapy regimen with paclitaxel/carboplatin was recommended, accompanied with bisphosphonate administration. However, on the 10th hospital day, the patient's condition deteriorated, developing fever (39°C) and blood leukocytosis ($35.5 \times 10^9/L$), with predominating granulocytes (96.5); procalcitonin levels also increased (2.58 ng/ml), as well as nitrogenous substances in the blood (blood urea 28.2 mmol/l, creatinine 311 μ mol/L). Gas analysis of the arterial blood at rest revealed a severe partial respiratory insufficiency (SaO₂ 81.7%, PaO₂ 6.16 kPa, PaCO₂ 5.41kPa, pH 7.396). The chest X-ray finding was presented with a bronchopneumonic infiltration paracardially on the right (Figure 4).

Parenteral antibiotic treatment was initiated, amoxicillin with clavulanic acid. After two days, due to elevated procalcitonin levels (138.24 ng/ml) and worsened medical condition, the therapy was switched to ceftazidime and ciprofloxacin, according to the NCCN (National Comprehensive Cancer Network) guidelines for immunosuppressed patients and hospital-acquired pneumonia. In the mean time, one set of blood cultures

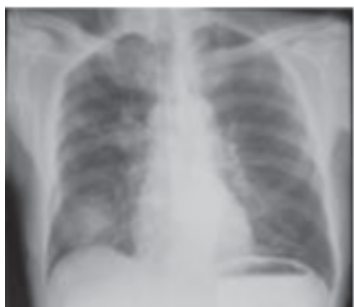

Figure 4: PA chest X-ray with pneumonic shadow.

was sent for microbiological examination. Blood cultures were cultivated in the automated BacT/Alert system using both anaerobe and aerobe liquid media. The instrument indicated positive cultures after the 24 hour-incubation. Gram staining of the liquid cultures revealed short Gram-positive bacilli. The blood cultures were subcultured on the blood agar and MacConkey agar in aerobic conditions and on Shaedler agar in anaerobic conditions. After 48h of incubation on the blood and Shaedler agar, a noticeable growth was registered. Colonies were small, smooth and slightly whitish. Gram stain of the culture revealed Gram-positive short rods resembling diptheroids in pattern. The oxidase and catalase tests were performed, producing a negative

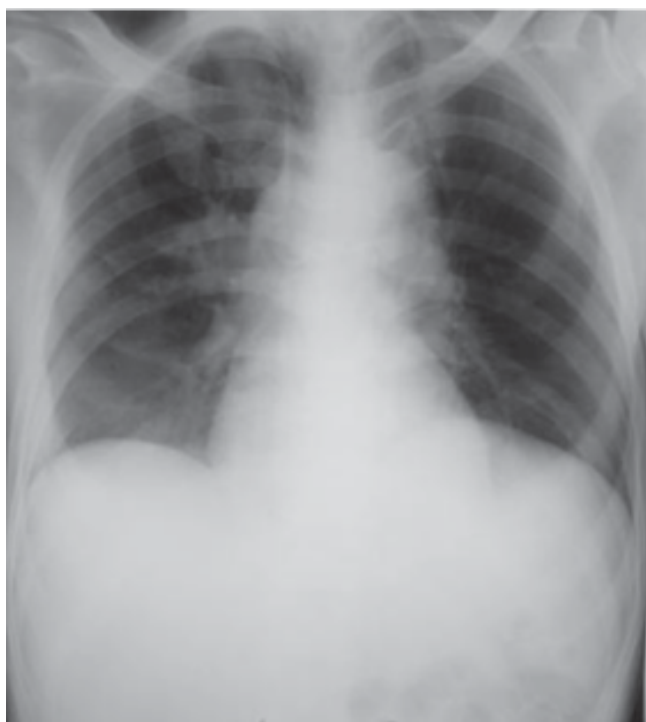

Figure 5: Control PA chest X-ray after antibiotics.

result. The identification was performed by anaerobic bacterial identification systems (BBL Crystal Identification Systems Gram Anaerobe Kit, Beckton Dickinson, USA) and *Actinomyces odontolyticus* was identified. Antimicrobial susceptibility testing could not be done due to technical difficulties. Similar cases of immunocompromised patients with *Actinomyces odontolyticus* infection suggested the efficiency of tetracyclines besides penicillin and cephalosporins in the treatment of such infection [2]. It was decided to include doxycycline in the treatment.

Procalcitonin level and white blood count tended to decrease, and the control chest X-ray finding showed an initial regression of the pneumonic infiltration in the right lower lobe (Figure 5).

However, on the 10th day of antimicrobial therapy, the medical state of the patient worsened, developing the symptoms of endogenous intoxication, resulting in a lethal outcome on the same day. The patient's dental status was normal, did not reveal any possible infection focus.

Discussion

Actinomyces odontolyticus is a Gram-positive facultative anaerobic, non sporulating, non-motile bacterium [1, 2]. The Gram-smear may be presented with shorter bacilli resembling diptheroids in pattern. Small, whitish, smooth or slightly granular colonies appear on the blood agar, developing dark red pigment in 2-14 days [1, 4]. Pigmentation is best recognized when the cultures, following the primary anaerobic isolation, are left on the room temperature. *Actinomyces odontolyticus* also grows well on the CDC and Brucella agar [2].

Actinomyces odontolyticus shows negative catalase and oxidase tests, reduces nitrates to nitrites, and does not grow at pH 5.5 [2]. The final identification can be done by identification systems based on biochemical reactions [8], or by polymerase chain reaction (PCR), analyzing the 16S rRNA gene sequence [7]. Moreover, the 16S rRNA gene sequence is recommended in final identification of *Actinomyces* species [7], but it is still not routinely used in clinical microbiology laboratories. *Actinomyces odontolyticus* is susceptible to penicillin, cephalosporins, tetracycline, clindamycin, chloramphenicol and erythromycin [2].

The identification of *Actinomyces odontolyticus* in blood cultures of the patient with advanced lung

malignancy was made according to microscopic, cultural and biochemical characteristics of the subculture grown on the blood and Shaedler agar and using the BBL Crystal AND ID.

The representatives of the genus *Actinomyces* are commensals of the oral cavity microflora which participate in development of dental caries, periodontitis and other infections [9]. *Actinomyces odontolyticus* infections are endogenous, originating from mucous membranes [2]. *Actinomyces odontolyticus* grows predominantly on the surface of the tongue in supra and subgingival regions [9], which may account for a normal dental finding of the patient.

Infections caused by *Actinomyces odontolyticus* are rarely found, more frequently affecting immunosuppressed patients, predominantly middle-aged males [2]. The reported patient is a middle-aged male with advanced malignant disease.

Conclusion

Immunosuppressed conditions are often complicated with severe infections caused by opportunistic bacteria, such as the reported infection induced by *Actinomyces odontolyticus* in the patient with advanced lung malignancy. Such infections often have a variable outcome despite the applied antimicrobial treatment. Better understanding of the pathogenetic mechanism of such opportunistic agents may help in developing some other treating strategies.

References

1. Chao CT, Liao CH, Lai CC, Hsueh PR. Liver abscess due to *Actinomyces odontolyticus* in an immunocompetent patient. *Infection*. 2011; 39:77–79.
2. Cone LA, Leung MM, Hirschberg J. *Actinomyces odontolyticus* bacteremia. *Emerg Infect Dis*. 2003;12:1629–32.
3. Mabeza GF, Macfarlane J. Pulmonary actinomycosis. *Eur Respir J*. 2003;21:545–51.
4. Takiguchi Y, Terano T, Hirai A. Lung abscess caused by *Actinomyces odontolyticus*. *Intern Med*. 2003; 42:732–5.
5. Simpson AJ, Das SS, Mitchelmore IJ. Polymicrobial brain abscess involving *Haemophilus paraphrophilus* and *Actinomyces odontolyticus*. *Postgrad Med J*. 1996;72:297–8.
6. Sugano S, Matuda T, Suzuki T, Makino H, Iinuma M, Ishii K, Ohe K, Mogami K. Hepatic actinomycosis: case report and review of the literature in Japan. *J Gastroenterol*. 1997;32:672–6.
7. Woo PC, Fung AM, Lau SK, Hon E, Yuen KY. Diagnosis of pelvic actinomycosis by 16S ribosomal RNA gene sequencing and its clinical significance. *Diagn Microbiol Infect Dis*. 2002;43:113–8.
8. Cavallaro JJ, Wiggs LS, Miller JM. Evaluation of the BBL Crystal Anaerobe Identification System. *J Clin Microbiol*. 1997;35(12):3186–91.
9. Drobni M, Hallberg K, Öhman U, Birve A, Persson K, Johansson I, et al. Sequence analyses of fimbriae subunit FimA proteins on *Actinomyces naeslundii* genospecies 1 and 2 and *Actinomyces odontolyticus* with variant carbohydrate binding specificities. *BMC Microbiol*. 2006; 6: 43.