



Penile agenesis: A case report

Hussaini Yusuf Maitama, Ngwobia Peter Agu, Usman Mohammed Tela

Abstract Absence of the penis is a rare congenital anomaly of the male infant that may be associated with other congenital anomalies. Management in the last two decades has changed from initial female gender assignment to penile reconstruction procedures. In our sub-region, training and experience in penile reconstruction are imperative.

Key Words Agenesis; aphallia; penis; congenital anomalies. © 2014 pediatricurologycasereports.com. All Rights Reserved

From the Division of Urology, Department of surgery, Ahmadu Bello University Teaching Hospital, Usman Danfodio University Teaching Hospital and University of Maiduguri Teaching Hospital, Nigeria.

Corresponding Author: Usman Mohammed Tela, Division of Urology, Department of Surgery, University of Maiduguri Teaching Hospital, Maiduguri, Nigeria.

Email: umtela@yahoo.com

Accepted for publication 21 October 2014

INTRODUCTION

Congenital anomalies of the penis are especially troubling for parents of affected children because of the unconscious emotional significance of the penis, because of the impact on future reproduction [1]. Absence of the penis is an extremely rare

congenital disorder occurring in 1 in 30 million births [2]. Clinical presentation is diagnostic but may be associated with other anorectal and systemic anomalies [3,4]. We report a case of a neonate with penile agenesis with associated genitourinary anomalies.

CASE REPORT

A three day old neonate presented at the Urology clinic with absent penis noticed by the mother at birth. Pregnancy was booked at a peripheral local government clinic and it was uneventful except for episode of

pyrexia, nausea and vomiting in the first trimester which was treated with some drugs purchased at the local drug store. The mother did not have the routine antenatal drugs and no form of laboratory investigations. The child was not a product of consanguine marriage. The mother went into spontaneous labour and had vertex vaginal delivery at home after 5 hours of labour. There was no history of intra-partum or post-partum hemorrhage. The baby cried after birth, moved all the limbs and also passed meconium at birth. The mother had noticed absence of the penis immediately after the delivery. There was no other abnormality noted. The baby sucks breast milk actively and there was no history of vomiting.

On examination, patient was dressed in female attire and the feet decorated with henna, not pale, anicteric acyanosed, and not dehydrated, afebrile and weighed 2.5kg. Respiratory rate was 20 cycles per minute, chest was clinically clear heart sounds were S1 and S2, no added sounds. Abdomen

moved with respiration, normal umbilical stump, no hernia, omphalocele, or suprapubic swellings were noted. Liver and spleen not enlarged, and the kidneys not ballotable. Examination of the external genitalia revealed normal well formed scrotum as shown in figures 1a, with bilaterally descended testes, however, the penis was absent as shown in figure 1b .

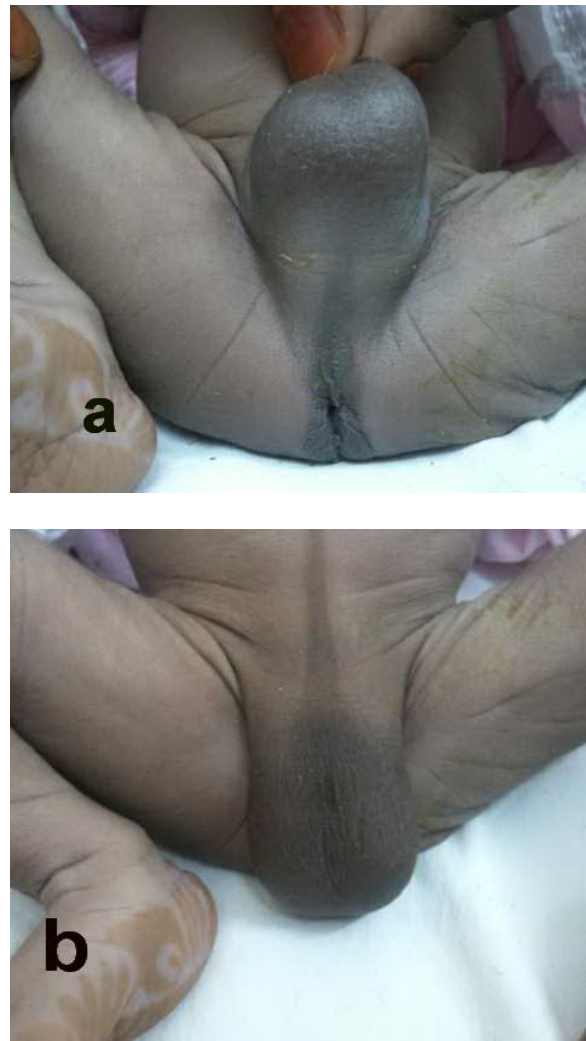


Fig. 1. (a) Normal scrotum and anus and **(b)** absent penis

There was no perineal induration or collection. Rectal examination showed normal anal verge, good sphincteric tone, and the rectum was empty, there was no palpable mass felt and the examining gloved finger was stained with well formed feces. Central nervous system examination revealed normal head circumference of 35 cm, normal face, neck and vertebral spine. Patient was moving all the limbs. A diagnosis of penile agenesis to rule out cloacal malformation was made.

Abdomino-pelvic ultrasound scan revealed ectopic left kidney with normal calyces, located in the pelvic cavity, otherwise normal right kidney, liver and spleen and kidneys. The urinary bladder was also normal, no stone or mass within it. The uterus was not visualized in the pelvis, and scrotal ultrasound scan revealed normal testes as shown in figure 2a. The soft tissues were within normal limit. The bladder phase of Intra-Venous Urography displayed contrast in the bladder and rectum, suggestive of a fistula communicating the 2

cavities, as seen in the lateral view, in figure 2b. Abdominal CT scan further confirmed the presence of left ectopic kidney as shown in figure 2c.

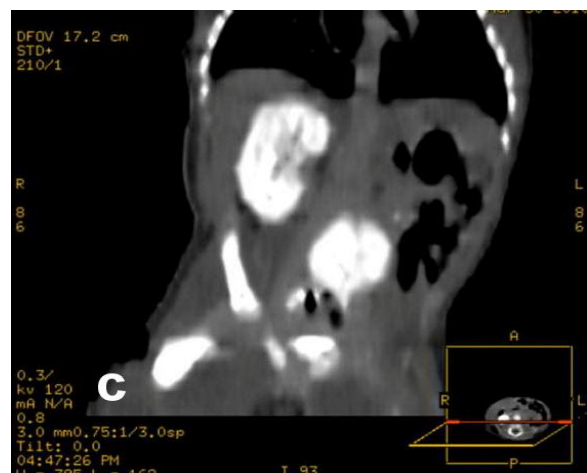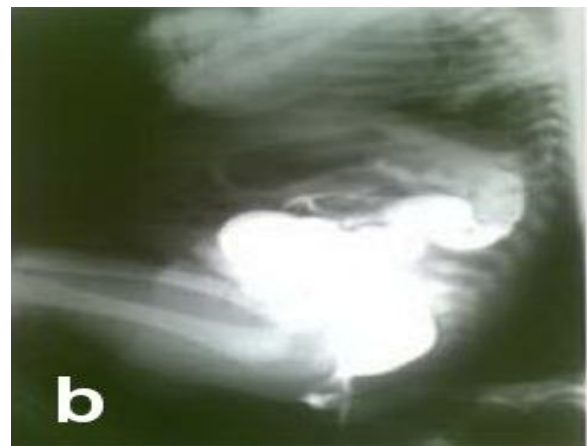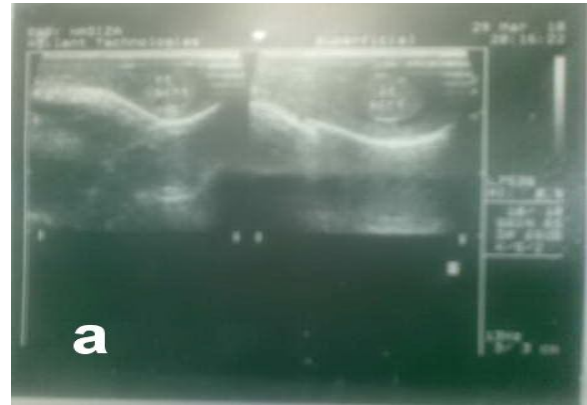


Fig. 2. (a) Normal testes, (b) IVU contrast in bladder and rectum and, (c) ectopic left kidney.

Buccal smear (cytology) was XY karyotype, serum electrolytes Urea and Creatinine were within normal limits. The packed cell volume was 37% and the WBC count was $7.2 \times 10^9/L$.

Male gender assignment was decided after discussing with the patient relation, who has much earlier presumed that the patient was female, at their first presentation in the clinic, evidenced by feminine attire and feet decorations in figure 1a. Our next plan of management was to do staged surgery comprising of phalloplasty and urethroplasty at an older age during which the tissues would have matured and hence easier to handle, and the potential complication of Anesthesia in the neonatal period would have been avoided. However, patient was said to have suddenly developed severe difficulty in breathing while breast feeding at home on the 10th day of life, which culminated to arrest, presented late at the hospital and was certified death on the same day. The possible cause of death was aspiration pneumonia.

DISCUSSION

Congenital absence of the penis, or Aphallia, is a rare anomaly caused by developmental failure of the genital tubercle. Approximate incidence is 1 case per 30 million populations. In this anomaly, the phallus is completely absent, including the corpora cavernosa and corpus spongiosum; however, some children have been reported to have small portions of corpora cavernosa. Usually, the scrotum is normal and the testes are maldescended. Approximately 80 cases have been reported. In these cases, the karyotype almost always is 46, XY, and the usual appearance is that of a well-developed scrotum with descended testes and an absent penile shaft [5].

Development of the external genitalia in the male is under the influence of androgens secreted by the fetal testes and is characterized by rapid elongation of the genital tubercle, which is now called the phallus [6]. In the embryo, the penis is derived from the genital tubercle, which starts to develop from mesenchyme at the

cranial end of the cloacal membrane early in the fourth week and then slowly elongates. This is followed by formation of labioscrotal swellings and urogenital folds on each side of the membrane. At the same time, the urorectal septum is forming, and by 7 weeks it has fused with the cloacal membrane to separate the urogenital sinus from the hindgut. The new distinct urogenital and anal membranes rupture at 7–8 weeks, to leave a patent anus and the urethral groove. As the penis elongates, the groove is pulled forward along its ventral surface and gradually fuses in the direction of the glans penis to form the penile urethra and penile raphe. The labioscrotal folds move dorsally and grow toward each other, fusing below the penis to form the scrotum and scrotal raphe. Obviously, major disruption of caudal mesoderm in this area would lead to maldevelopment of most of these structures, including the genital tubercle (resulting in penile agenesis), urogenital sinus (resulting in bladder and urethral agenesis), and hindgut (resulting in anal atresia).

Labioscrotal swellings are ectodermal in origin, which later develops into scrotum in the male and labia major in the female [4,7]. Aphallia is usually associated with genitourinary and nongenitourinary system anomalies such as cryptorchidism, vesico-ureteral reflux, horseshoe kidney, renal agenesis, imperforate anus and musculoskeletal abnormalities [5,8]. Absence of the phallus with well-developed scrotum and presence of a skin tag at the anal verge with or without a urethral meatal opening within it are the usual clinical findings associated, and this appears to stem from a more isolated malformation of the genital tubercle [4]. The index patient fits the above description but in addition, had ectopic left kidney in the pelvis and rectovesical fistula. Management of aphallia has seen a dramatic change in last few years from the earlier female sex reassignment to the recent trend toward male sex assignment [2]. The previous multi-stage treatment comprised of female gender reassignment, bilateral orchiectomy, urethral perineal

transposition and feminizing genitoplasty in new born period or at presentation [3,9].

Prompt gender assignment is important in a child with external genitalia ambiguity. However, gender assignment or re-assignment poses some of the most emotive and contentious ethical dilemmas encountered in any area of medical practice. Moreover, the emergence of patient and parent support groups and the interchange of information via the Internet have created a climate in which medical decisions and management is the subject of increasingly close and critical scrutiny [10]. Some of these patients have a male gender identity despite reconstruction as a female, presumably because of in-utero or postnatal sex steroid imprinting. Consequently, the recommendation to perform gender reassignment should be made carefully and only after full evaluation by an ambiguous genitalia assessment team that includes a pediatric urologist, endocrinologist, and psychiatrist [5]. Nowadays however, sex reassignment surgery (man to woman) is no

longer considered as an option for patients with aphallia (normal 46, XY man with functioning testis). In 2007, an article by De Castro et al influenced changing the management of aphallia. They proposed that the opposite sex should not be assigned in patients affected by aphallia. They recommended the rearing of such patients according to their karyotype and hormonal production to prevent later gender dysphoria. They proposed early palliative phalloplasty using an abdominal wall skin flap in childhood until the patient can undergo definitive phalloplasty using a forearm free flap after puberty [11]. This was our proposed plan of management in the index case presented. Perovic et al reconstructed the phallus using a musculocutaneous latissimus dorsi free flap to create the new phallus [12].

Penile agenesis is a rare male genital anomaly that may be a cause of anxiety to the parents. Early referral to the specialist centre, prompt diagnosis and early gender assignment are crucial to good outcome. In

our sub-region, training and development of reconstructive urologic procedures are important for management of these patients.

REFERENCES

- Hartke DM and Palmer JS. Anomalies of the Penis. *J Men's Health & Gender*. 2006; 3(3): 244-9.
- Rattan KN, Kajal P, Pathak M, Kadian YS, Gupta R. Aphallia: experience with 3 cases. *J Pediatr Surg*. 2010; 45(1): E13- 6.
- Gupta A and Gupta H. Aphallia: A rare congenital anomaly. *JK Science*. 2008; 10 (3):142-3.
- Evans JA, Erdile LB, Greenberg CR, Chudley AE. Agenesis of the penis: patterns of associated malformations. *Am J Med Genet*. 1999;84(1):47-55.
- Elder JS. Abnormalities of Genitalia in Boys and their surgical Surgical Management. In *Campbell- Walsh Urology*, Wein AJ, Kavoussi LR, Novick AC, Peters CA (Eds). 9th Edition; Saunders Elsevier; 2007; p3756.
- Sadler TW. External Genitalia. In: *Langman's Medical Embryology*, 9th Edition; pp 349-350.
- Kaefer M, Adams MC. Penis and bladder Agenesis in a living male neonate. *J Urol*. 1997;157(4): 1439-40.
- Roth JK, Marshall RH, Angel JR, Daftary M, Lewis RW. Congenital absence of the penis. *Urology*. 1981;17 (6): 579-583.
- Gluer S, Fuchs J, Mildemberger H. Diagnosis and current management of penile agenesis. *J Pediatr Surg*. 1998;33 (4): 628-31.
- Thomas DFM. Gender assignment: background and current controversies. *BJU Int*. 2004; 93: 47-50.
- De Castro R, Merlini E, Rigamonti W, Macedo A Jr. Phalloplasty and urethroplasty in children with penile

CONFLICT OF INTEREST

None declared.

agenesis: preliminary report. J Urol.
2007;177(3):1112-6.

12. Perovic SV, Djinovic R, Bumbasirevic M, Djordjevic M, Vukovic P. Total phalloplasty using a musculocutaneous latissimus dorsi flap. BJU Int. 2007;100(4):899-905.