



Penile injury due to blunt trauma after circumcision in a male child:

A case report

Hulya Ozturk, Serkan Ozturk

Abstract Injury in the case presented here is different from the cause of penile trauma. Our case has been exposed to blunt trauma after circumcision. Type developments of the penile trauma, treatment, and precautions have been discussed with the literature.

Key Words Penile trauma; children; circumcision; blunt trauma.

© 2014 pediatricurologycasereports.com. All Rights Reserved

From the Department of Pediatric Surgery, Abant Izzet Baysal University, Medical School, Bolu, Turkey.

Corresponding Author: Hulya Ozturk-Prof, M.D. Abant Izzet Baysal University, Medical School,

Department of Pediatric Surgery, Bolu, Turkey

E mail: hulya_ztrk@yahoo.com

Accepted for publication 18 August 2014

INTRODUCTION

Circumcision is a common and persistently controversial surgical procedure. Circumcision involves the amputation of both layers of the foreskin normally covered glans, and is often performed on baby boys a few days after birth [1,2]. It is a relatively safe procedure with a low complication rate.

However, it, like any surgical procedure, does carry the risk of complications. Circumcision-related injuries are most commonly due to clamp (e.g. Mogen or Gomco) circumcisions and may range from a mild loss of penile skin to more significant glans, distal urethral and penile shaft injuries [3-5]. Complication rates depend on multiple factors such as anatomic, medical comorbidities, surgical technique, and age [3].

The causes of penile trauma except circumcision complications are varied; it can be iatrogenic or caused by traffic accidents, blunt trauma, burns, animal bites, gunshots or self-mutilation. The type and extent of penile trauma varies from mild to severe injuries, sometimes even with total amputation [6].

Injury in the case presented here is different from the cause of penile trauma. Our case has been exposed to blunt trauma after circumcision. Type developments of the penile trauma, treatment, and precautions have been discussed with the literature.

CASE REPORT

A seven year old boy was brought for circumcision. Case was circumcised with technique free-hand circumcision. The “free-hand circumcision” is accomplished in the operating room and involves excising the skin as marked, hemostasis using electrocautery and then re-approximation of the skin edges using absorbable sutures. Early complication has not developed. Although warning of the patient's parent, the patient was sent to school early and he was

exposed to blunt trauma. Most of the penile skin sutures were opened, and bleeding, hematoma and edema in the penile tissue were developed (Fig 1,2). The penile skin was cleaned and foley was inserted. The patient was managed conservatively improved.

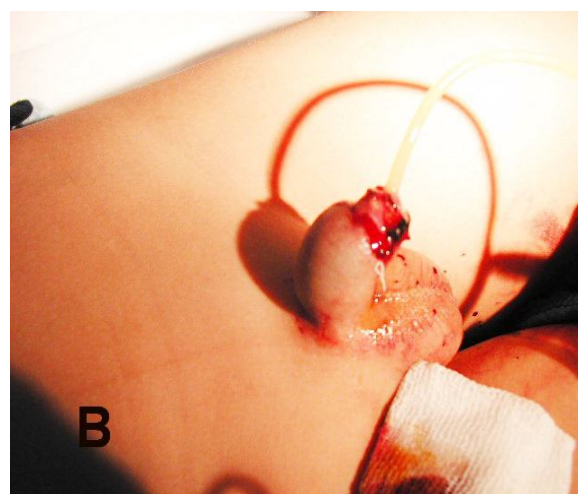
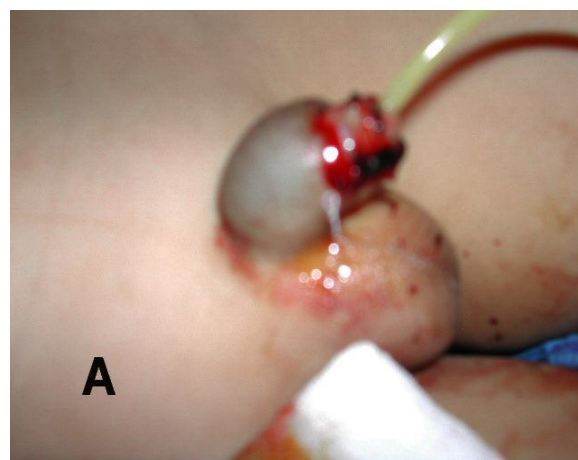


Fig1.A,B. The appearance of penile blunt trauma after circumcision.

DISCUSSION

Penile trauma in the pediatric patient population is most commonly iatrogenic and

caused by circumcision [7,8]. Additionally, the causes of penile trauma are varied; it can be iatrogenic or caused by traffic accidents, blunt trauma, burns, animal bites, gunshots or self-mutilation. The type and extent of penile trauma varies from mild to severe injuries, sometimes even with total amputation [6]. To fall onto a hard surface or an object falling onto the penis are other cases penile injuries in childhood. These injuries lead to contusions and superficial lacerations [9]. Circumcision-related early complications such as: bleeding, pain, inadequate skin removal, and surgical site infection tend to be minor and quite treatable. However, postcircumcision bleeding in patients with coagulation disorders can be significant and sometimes even fatal. Other serious early complications include chordee, iatrogenic hypospadias, glanular necrosis, and glanular amputation. The latter, of course, requires prompt surgical intervention. Circumcision-related late complications include epidermal inclusion cysts, suture sinus tracts, chordee,

and inadequate skin removal resulting in redundant foreskin, penile adhesions, phimosis, buried penis, urethrocutaneous fistulae, meatitis, and meatal stenosis. These are commonly treated in an outpatient setting [10].

Penile strangulation caused by a hair or thread is occasionally seen. In most cases it is hard to believe that this insult is purely accidental, and consideration for social service investigation for possible child abuse should be given [7,11-13]. Domestic animal attack is the most severe form of penile trauma usually seen in childhood. These penile injuries are usually associated with significant tissue destruction and fraught with complications due to bacterial contamination [7,11,12].

Our case is somewhat different from the above cause penile trauma. Case was normally circumcised. Early complication has not developed. Although warning of the patient's parent, the patient was sent to school early and he was exposed to blunt trauma. Most of the penile skin sutures were

opened, and bleeding, hematoma and edema were developed. The penile skin was cleaned and the foley was inserted. The patient was managed conservatively improved. Children after circumcision must

not be exposed to blunt trauma. Hence, during the recovery period is important refrain from excessive activity of children.

CONFLICT OF INTEREST

None declared.

REFERENCES

1. Boyd BR. Circumcision exposed: Rethinking a medical and cultural tradition. Freedom CA: The Crossing Pres, U.S. 1998.
2. Ritter TJ and Denniston GC. Say No to Circumcision: 40 Compelling Reasons. 2nd ed. Aptos, CA: Hourglass.; 1996, pp. 6-20.
3. Krill AJ, Palmer LS, Palmer JS. Complications of circumcision. Scientific World Journal. 2011;11:2458-68.
4. Livne PM, Gonzales ET, Jr. Genitourinary trauma in children. Urol Clin North Am. 1985;12:53-65.
5. Vemulakonda V and Grady RW. Genital Trauma. In: Wilcox DT, Godbole PP, and Kolye MA (eds). Pediatric Urology: Surgical Complications and Management. Blackwell Publishing Ltd.; 2008. pp. 289-295.
6. Perovic SV, DjinoVIC RP, Bumbasirevic MZ, Santucci RA, Djordjevic ML, Kourbatov D. Severe penile injuries: a problem of severity and reconstruction. BJU Int. 2009; 104:676-87.
7. Gluckman G, Stoller M, Jacobs M, Kogan B. Newborn penile glans amputation during circumcision and successful reattachment. J Urol. 1995;153:778-82.
8. El-Bahnasawy MS, El-Sherbiny MT. Paediatric penile trauma. BJU Int. 2002;90:92-6.
9. Male external genital injuries. In: Davies F, Bruce CE, Robinson KT (eds). Emergency Care of Minor Trauma in Children: A Practical Handbook. CRC Press.; 2011. pp.180-182.

10. Mayer E, Caruso DJ, Ankem M, Fisher MC, Cummings KB, Barone JG. Anatomic variants associated with newborn circumcision complications. *Can J Urol.* 2003;10:2013-6.
11. El-Sherbiny M, Abol- Enein H, Dawaba M, Ghoneim M. Treatment of urethral defects: skin, buccal or bladder mucosa, tube or patch? An experimental study in dogs. *J Urol.* 2002;167:2225-28.
12. Radhakrishnan J, Razzaq A, Manickam K. Concealed penis. *Pediatr Surg Int.* 2002;18:668-72.
13. Ozcakir E, Kaya M. A genital hair tourniquet syndrome: Case report and review of the literature. *Ped Urol Case Rep.* 2014;1:1-4.