



## Self-insertion of needle as urethral foreign body after sexual gratification: An unusual case report

Metin Tahaoglu, Serkan Ozturk, Hayrettin Ozturk

**Abstract** Self-inserted foreign bodies in the urethra are rare among children. We describe here a 13-year-old boy who had self-inserted a needle into his urethra. Self-insertion of the needle wrapped with cotton into the urethra for cleaning after masturbation by patient was applied. A foreign body in the urethra was removed by cystoscopy.

**Key Words** Self-inserted foreign bodies; urethra; children; cystoscopy.

© 2014 pediatricurologycasereports.com. All Rights Reserved

*From the Department of Pediatric Surgery, Abant Izzet Baysal University, Medical School, Bolu, Turkey.*

**Corresponding Author:** Hayrettin Ozturk, M.D. Abant Izzet Baysal University, Medical School,

Department of Pediatric Surgery, Bolu, Turkey

E mail: [ozturkhayrettin@hotmail.com](mailto:ozturkhayrettin@hotmail.com)

Accepted for publication 27 August 2014

### INTRODUCTION

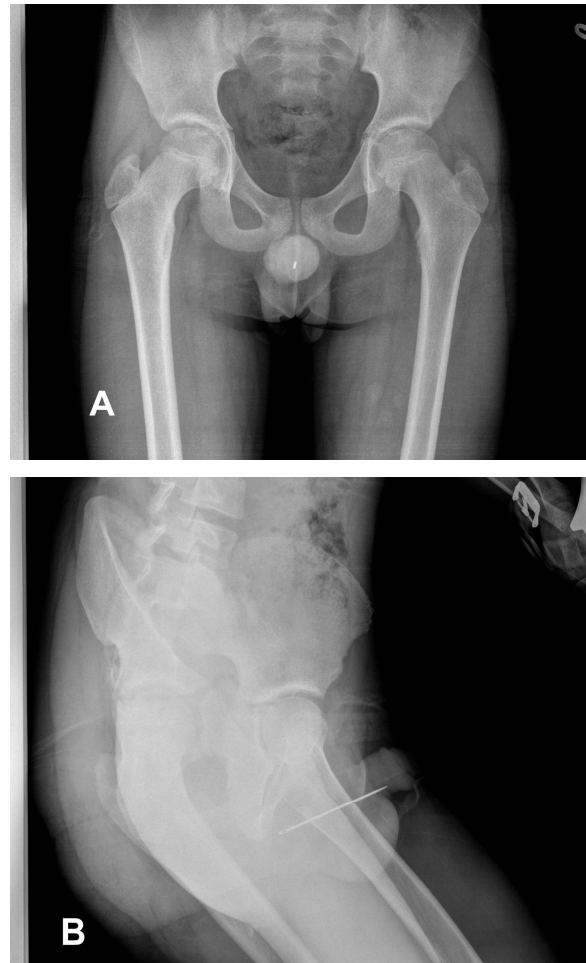
Self- insertion of the foreign body into the urethra in male children has been rather uncommon reported in the literature [1,2]. Self- insertion foreign bodies are varied as pins, wires, screws or ball point pens [3,4]. The causes of self-insertion are autoerotic

stimulation, psychiatric illness, therapeutic purposes, or no definite reasons by the patient [1,5,6]. The urological consequences of self-insertion can be significant and the implications for patients can be serious consequences until death from sepsis [5,6]. We present a case of self-insertion of the needle wrapped with cotton into the urethra for cleaning after masturbation. We review possible motives for insertion of foreign bodies in to the urethra and discuss clinical

presentation, as well as diagnosis and management of such patients.

### CASE REPORT

A 13-year-old boy presented to the emergency department approximately 3 hours after the event with a urethral needle he had self-inserted. The boy was otherwise healthy, without previous medical problems, including psychiatric illness or drug addiction. This was the first time he had ever self-inserted a foreign body in his urethra. The patient said that he was masturbating. Self-insertion of the needle wrapped with cotton into the urethra for cleaning after masturbation by him was applied. Needle had escaped into the urethra. A physical examination was unremarkable. Posteroanterior and lateral pelvic x-ray image demonstrated a straight radiopaque needle inside the urethra (Fig.1,2). The needle was extracted via transurethral route with a urethroscope under general anesthesia. The post-operative course was uneventful and he was discharged home after 24 hours. The patient had a preliminary psychological evaluation.



**Fig. 1.** Posteroanterior and lateral pelvic radiogram of patient. There is a linear radio-opaque foreign bodies in the region of urethra.

### DISCUSSION

Self-insertion transurethrally of foreign bodies in the literature has been presented including fishhooks, pencils, electrical cables, metal rods, screws, a knife handle, and pistachio shells [1]. However, self-insertion of foreign bodies in children is very rare [1]. Complications of self-insertion of foreign bodies for the urethra are

known as urethral injury, urethrocutaneous fistula, bladder perforation, and renal failure [7-10].

Foreign bodies in the lower urinary tract can be migration from adjacent sites which may result in trauma. The reasons for insertion of foreign bodies into urethra could be psychiatric, accidental, sexual stimulation, curiosity especially among children, or therapeutic in cases of stricture [11]. The case presented here is very interesting. Cause underlying of self-insertion of the needle into the urethra is very different. Self-insertion of the needle wrapped with cotton into the urethra for cleaning after masturbation by patient was applied. Needle had escaped into the urethra.

In the presence of a foreign body in the urethra often requires prompt diagnosis and treatment [1,12-14]. Definite therapy of urethral foreign bodies aims at complete removal with minimal invasive method and least complications. The most optimal method to remove urethral foreign bodies

depends on features of the objects, such as shape, size, location, and mobility in the urethra [1]. At the same time, procedures of foreign body removal from the urethra such as meatotomy, cystoscopy, internal or external urethrotomy, suprapubic cystostomy have been described. However, removal of foreign body is usually performed via cystoscopy but may require open surgery [15]. Even in infancy it is possible to extract foreign body by transurethral approach. Cystoscopy is minimal invasive technique for retrieval [16]. In our case, foreign body in the urethra was removed by cystoscopy. Any complications did not develop. Additionally, cotton residue in the urethra was observed. Psychiatric evaluation has been advised in all cases of self insertion of foreign bodies, although this has not been universally agreed upon [1,17]. Psychiatric control in our case was recommended.

#### **CONFLICT OF INTEREST**

**None declared.**

## REFERENCES

1. van Ophoven A, deKernion JB. Clinical management of foreign bodies of the genitourinary tract. *J Urol*. 2000;164:274-87.
2. Rahman NU, Elliott SP, McAninch JW. Self-inflicted male urethral foreign body insertion: endoscopic management and complications. *BJU Int*. 2004;94:1051–53.
3. Trehan RK, Haroon A, Memon S, Turner D. Successful removal of a telephone cable, a foreign body through the urethra into the bladder: a case report. *J Med Case Rep*. 2007;27;1:153.
4. Park S, Moon KH, Kim SH, Kim DY, Cho YW, Cho SJ, Park S. Needles as urethral foreign body in a child: successful removal using a new method with a laparoscopic needle holder. *Urology*. 2013;8:188–90.
5. Ghaly AFF, Munishankar AR, Sultana SR, Nimmo M. Case report: foreign body in the male penile urethra. *Genitourin Med*. 1996;72:67–8.
6. Pec J, Straka S, Novomesky F, Kliment J, Pec M, Lazarova Z. Mechanical urethritis and ascendant genitourinary infections due to sexual stimulation of the urethra by inserted foreign bodies. *Genitourin Med*. 1992;68:399–400.
7. Rahman N, Featherstone NC, DeCaluwe D. Spider-man, magnets, and urethral-cutaneous fistula. *Urology*. 2010;76:162-3.
8. Jacobs BL, Matoka DJ, Maranchie JK. Renal insufficiency secondary to delayed presentation of a retained foreign body. *Can J Urol*. 2009;16:4697-4700.
9. Forde JC, Casey RG, Grainger R. An unusual penpal: case report and literature review of posterior urethral injuries secondary to foreign body insertion. *Can J Urol*. 2009;16:4757-59.
10. Rafique M. Intravesical foreign bodies: review and current management strategies. *J Urol*. 2008;5:223-31.
11. Sukkarieh T, Smaldone M, Shah B. Multiple foreign bodies in the anterior

- and posterior urethra. *Int Braz J Urol.* 2004;30:219-20.
12. Moon SJ, Kim DH, Chung JH, Jo JK, Son YW, Choi HY, Moon HS. Unusual foreign bodies in the urinary bladder and urethra due to autoerotism. *Int Neurourol J.* 2010;14:186-89.
13. Padmanabhan P, Hutchinson RC, Reynolds WS, Kaufman M, Scarpero HM, Dmochowski RR. Approach to management of iatrogenic foreign bodies of the lower urinary tract following reconstructive pelvic surgery. *J Urol.* 2012;187:1685-90.
14. Gonzalgo ML, Chan DY. Endoscopic basket extraction of a urethral foreign body. *Urology.* 2003;62:352.
15. Rafique M. Case report: an unusual intravesical foreign body: cause of recurrent urinary tract infections. *Int Urol Nephrol.* 2002;34:205-6.
16. Ceran C, Uguralp S. Self-inflicted urethrovesical foreign bodies in children. *Case Rep Urol.* 2012;2012:134358.
17. Padmanabhan P, Hutchinson RC, Reynolds WS, Kaufman M, Scarpero HM, Dmochowski RR. Approach to management of iatrogenic foreign bodies of the lower urinary tract following reconstructive pelvic surgery. *J. Urol.* 2012;187:1685–90