



Early intervention in a newborn with primary obstructive megaureter

Arzu Akdag, Elif Ozalkaya, Hakan Erdogan, Ayse Oren, Mete Kaya

Abstract In children, any ureter greater than 7 mm in diameter is considered a megaureter based on measurements in fetuses greater than 30 weeks gestation and children <12 years. Primary megaureter (POM) is a result of a functional or anatomical abnormality involving the uretero-vesical junction. Although the endoscopic and surgical techniques to manage POM are successful, we thought that early intervention may cause to undesirable results.

Key Words Ureter; children; megaureter; primary megaureter

© 2014 pediatricurologycasereports.com. All Rights Reserved

From the Department of Neonatology, Nephrology and Pediatric Surgery, Sevket Yilmaz Education and Research Hospital, Bursa, Turkey

Corresponding Author:

Arzu Akdag, M.D.

Sevket Yilmaz Education and Research Hospital,

Department of Neonatology, Yildirim, Bursa, Turkey.

E-mail: arzuakdag@hotmail.com

Accepted for publication 30 June 2014

INTRODUCTION

Megaureter is defined as a ureter that exceeds the upper limits of normal size. In children, any ureter greater than 7 mm in

diameter is considered a megaureter based on measurements in fetuses greater than 30 weeks gestation and children <12 years [1]. Smith [2] classified megaureters into four categories, obstructed, refluxing, refluxing with obstruction, and non-refluxing/non-obstructing, later subdivided into primary and secondary by King [3]. Primary megaureter (POM) is a result of a functional

or anatomical abnormality involving the uretero-vesical junction, whereas secondary megaureter results from abnormalities that involve the bladder or urethra.

There are no randomized trials that provide evidence for the optimal management of POM. In early infancy, the conservative management is recommended in the most of cases with POM, but also some cases such as urosepsis or massive dilatation with decreased renal function at presentation, or onset of symptoms or obstruction with loss of function at follow-up are needed surgical intervention [4].

We present a case of POM and thus we plan to discuss the postnatal approach to POM.

CASE REPORT

Labor was induced and a primigravida gestation 40 weeks male, weighing 3280 g was born with vaginal delivery. A baby was born depressed with Apgar scores of 3 and 6 at 1 and 5 min, respectively. His heart rate increased from 80/min to 120/min after one minute of face-mask bagging. At 1 hours age, blood gas (all given as

pH/pCO₂/pO₂/HCO₃⁻/Base excess) revealed 7.1/34/24/9/-17. The infant began seizing within the first 2 hours of life. He was transferred to the neonatal intensive care unit (NICU) for the management of birth asphyxia. He underwent 72-hour duration of therapeutic hypothermia (33.5°C) and made an uneventful recovery.

Family history was of no significance. Before referral, antenatal ultrasound (US) examination showed bilateral dilated upper pelvicaliceal and ureteric systems at 35 weeks, suspicious for obstruction. Abdominal US on postnatal day 3 showed bilateral grade 4 hydroureteronephrosis, and increased renal pelvis antero-posterior (A-P) diameters (R.25 mm and L.21 mm). Blood electrolytes, serum creatinine and blood urea nitrogen (BUN) were normal levels. A voiding cystourethrogram (VCUG) was performed, but a vesico-ureteral reflux or posterior urethral obstruction like valves was not detected (Fig. 1).

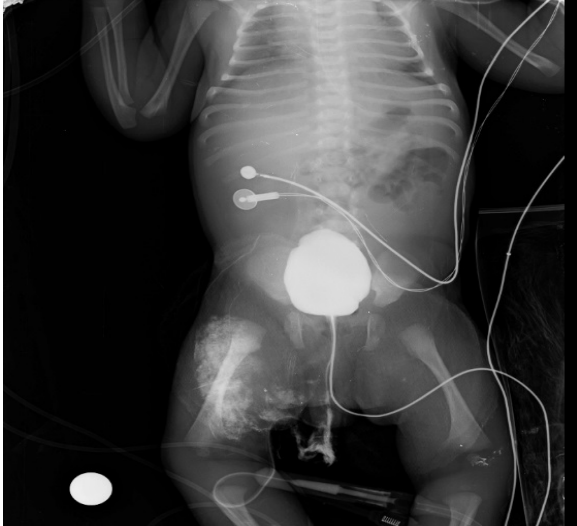

Fig. 1. Cystography shows no VUR or PUV like appearance.

After the improvement of the overall situation, because of bilateral renal pelvis diameter increased (R.35 mm and L.37 mm), and urine output decreased gradually, cystoscopy was performed to investigate PUV, and uretero-vesical junction (UVJ) obstruction and bilateral ureterocele with bladder trabeculations were detected in patient. Ureters could not be stented. Transcystoscopic incision of the ureterocele was carried out, but after operation, anuria developed, US revealed severe bilateral hydroureteronephrosis with 45 mm renal pelvis diameter, and emergent bilateral percutaneous nephrostomy catheter was inserted. The antegrad pyelographies were

applied, and revealed bilateral obstructive megaureters (Fig. 2).

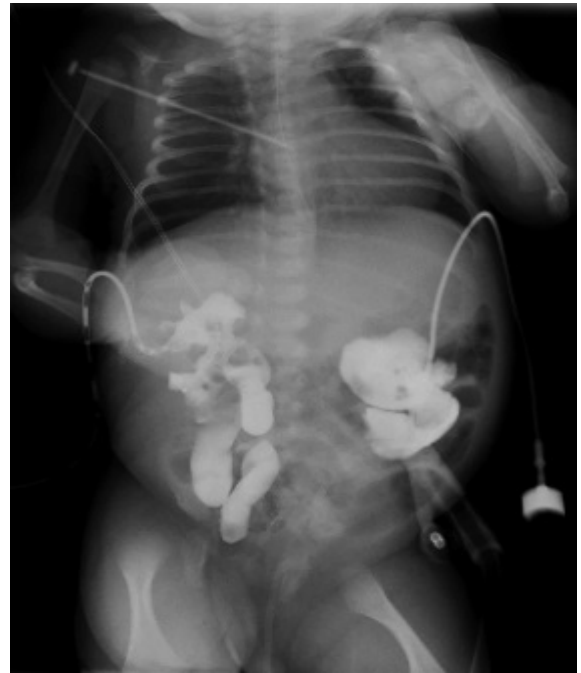


Fig.2. Bilateral antegrade pyelographies display megaureters and no drainage to the bladder.

Patient was followed up for 1 month with percutaneous nephrostomy, but there was no transition in antegrade pyelography. Because of family of the baby had lower socio-economic level and percutaneous catheter would be able to be tolerated by parents, ureteroneocystostomy, ureteral tapering and double J stenting as definitive operation were performed on postnatal day 40. Patient was discharged from hospital with oral antibiotics, and followed-up outpatient basis without complication. Double J stents were

removed at postoperative 6th weeks, after which, the patient was uneventful on follow-up period. Oral amoxicillin (10 mg/kg/day) has been given for antibiotic prophylaxis. Technetium-99m mercaptoacetyltriglycine (MAG3) showed mildly obstructive pattern in the kidneys. The differential kidney functions were 59% and 41% in the right and left kidneys. At 6 months of age, he had one febrile UTI which was treated with antibiotics. Repeat imaging results of renal US still show bilateral hydronephrosis. He has already comfortable urination without renal failure.

DISCUSSION

POM is nonhereditary congenital dilatations that grow up by the obstruction of the distal ureter, and it is the second most common form of ureteric obstruction in newborns with an incidence of about 0.36 of 1,000 live births [5-7]. The normal ureteral peristalsis is lost because of the functional obstruction of the distal segment. Before routine prenatal ultrasound screening, most children presented as toddlers with urinary tract

infection (UTI), abdominal pain, hematuria, or urolithiasis in later life [6,8,9].

Congenital anomalies of the UVJ often present because of detection of an associated dilated or 'mega'-ureter. Although it is commonly named as obstructed megaureter, UVJ obstruction is a more specific term, and focuses on the obstructive nature of the lesion. All babies with prenatally diagnosed ureteric dilatation should have a postnatal ultrasound scan. Babies with bilateral ureteric dilatation and boys with unilateral hydronephrosis should have an early VCUG obtained in order to exclude the presence of vesicoureteral reflux (VUR) or bladder outlet obstruction such as posterior urethral valves (PUV). The possibility of UVJ obstruction or megaureter is considered in patients with hydronephrosis and dilated ureter where VCUG is normal [4]. In our patient, bilateral hydronephrosis had been detected on antenatal US. Because primary problem was perinatal asphyxia at first, urinary symptoms could not follow properly. Postnatal serial USs showed a

bilateral persistent upper urinary tract dilatation. VCUG displayed no VUR or PUV.

Initial management of primary megaureters is conservative which based on prophylactic antibiotics. It has been shown to provide an opportunity for spontaneous regression of megaureter without a compromise in renal function. Peters et al. reported that 10% of patients required surgery before 8 months of age [10]. Keating et al. [11] reported that when the decision to intervene was based on absolute renal function, up to 87% of patients could be followed up conservatively. On the other hand, Dixon et al. [12] speculate that this embryologic malformation of terminal ureter does not resolve spontaneously and may become the subgroup of obstructed megaureter that requires early intervention. Because our patient's urinary output decreased and diameter of renal pelvis increased, early cystoscopic evaluation was done to detect any bladder or anomaly of bladder outlet. Trabeculous and enflamed bladder

associated with bilateral moderate ureterocele were found. Although an endoscopic incision of the ureterocele was done properly, no urine output was seen postoperative period, bilateral hydroureteronephrosis was dramatically increased, and finally percutaneous drainage was performed as early intervention.

Actually, indications for surgical intervention include symptoms such as febrile UTIs or pain, and, in the asymptomatic patient, a differential renal function below 40% associated with massive or progressive hydronephrosis, or a drop in differential function on serial renograms. Occasionally, an infant presents with substantial renal compromise secondary to an obstructed megaureter. There was proposed that emergency intervention is performed when faced with a septic child with an obstructed infected system not responsive to intravenous antibiotics, and the majority voted in favour of a percutaneous nephrostomy or cutaneous ureterostomy in preference to a double-J

stent [13]. Our case was initially decided to be managed conservatively, but temporary percutaneous nephrostomy catheters were inserted because of anuria occurred after endoscopy. We thought that developed an edema and inflammation at the lower end of the ureter after cystoscopic management caused an anuria.

Recommended surgical interventions are tapering and ureteral reimplantation in patients with obstructive megeureters over 1 year of age but the procedure may be challenging in infancy [4,5,10]. However, the reimplantation of a grossly dilated ureter into a small infantile bladder could be a challenging operation in babies below 1 year of age; proposed alternatives are the insertion of a temporary JJ stenting, endoscopic balloon dilatation, endoureterotomy, cutaneous ureterostomy or a refluxing reimplantation. However, we placed initially percutaneous nephrostomy catheters, but later, early definitive surgery as tapering and ureteroneocystostomy was performed, because the socio-economic

status of the patient's family was low, they would not able to look long time a baby with ureterostomy or percutaneous catheter.

In conclusion, controversy surrounds the current management of obstructed megaureter. Conservative management based on prophylactic antibiotics has been shown to provide an opportunity for spontaneous regression of megaureter without a compromise in renal function, especially in infants less than 1 year of age. Surgery is reserved for patients with high-grade POMs with increasing dilation, obstructive patterns found at renography, or cases involving decreased renal function. Although the endoscopic and surgical techniques to manage POM are successful, we thought that early intervention may cause to undesirable results.

CONFLICT OF INTEREST

None declared.

REFERENCES

1. Cussen LJ. Dimensions of the normal ureter in infancy and childhood. Invest Urol. 1967;5:164-178.

2. Smith ED. Report of Working Party to establish the international nomenclature for the large ureter. In: Bergsma D, Duckett J (eds). Birth defects. Original articles series. NY: A. Allan, R. Liss Inc.; 1977. pp. 3e8.
3. King LR. Megaloureter: definition, diagnosis and management. *J Urol.* 1980;123:222-23.
4. Farrugia MK, Hitchcock R, Radford A, Burki T, Robb A, Murphy F; British Association of Paediatric Urologists. British Association of Paediatric Urologists consensus statement on the management of the primary obstructive megaureter. *J Pediatr Urol.* 2014;10:26-33.
5. Shokeir AA, Nijman RJ. Primary megaureter: current trends in diagnosis and treatment. *BJU Int.* 2000;86:861-68.
6. Meyer JS, Lebowitz RL. Primary megaureter in infants and children: a review. *Urol Radiol.* 1992;14:296-305.
7. Stoll C, Alembik Y, Roth MP, Dott B, Sauvage P. Risk factors in internal urinary system malformations. *Pediatr Nephrol.* 1990;4:319-323.
8. Diamond DA, Rickwood AM, Lee PH, Johnston JH. Infection stones in children: a twenty-seven-year review. *Urology.* 1994;43:525-27.
9. Vereecken RL, Proesmans W. A review of ninety-two obstructive megaureters in children. *Eur Urol.* 1999;36:342-47.
10. Peters CA, Mandell J, Lebowitz RL, Colodny AH, Bauer SB, Hendren WH, et al. Congenital obstructed megaureters in early infancy: diagnosis and treatment. *J Urol.* 1989;142:641-45.
11. Keating MA, Escala J, Snyder HM 3rd, Heyman S, Duckett JW. Changing concepts in management of primary obstructive megaureter. *J Urol.* 1989;142:636-40.
12. Dixon JS, Jen PY, Yeung CK, Gosling JA. The vesico-ureteric junction in three cases of primary obstructive megaureter associated with ectopic ureteric insertion. *Br J Urol.* 1998;81:580-84.

13. Carroll D, Chandran H, Joshi A, McCarthy LS, Parashar K. Endoscopic placement of double-J ureteric stents in children as a treatment for primary obstructive megaureter. *Urol Ann.* 2010;2:114-18.