

UDC: [616.717.8/9+616.727.8/9]-007.251-089.844

CLEFT HAND RECONSTRUCTION IN A YOUNG ADULT WOMAN (CLINICAL CASE)

Andrey Bepalchuk*, ¹Lana Kang

Belarusian State Medical University, 83, Dzerzhinsky Ave., Minsk 220116, Republic of Belarus

¹Hospital for Special Surgery, 535 East 70th Street, New York, NY 10021, USA

(Received 25 January 2013; published 14 April 2013)

Cleft hand is a congenital deformity of the hand consisting of varying absence of the central structures of the hand. One form is the V-shaped cleft in the palm with severe narrowing of the web space and absence of the middle finger. Most peer-reviewed studies in the scientific literature describe surgical treatment during childhood. This study illustrates our experience with treating cleft hand deformity in a skeletally mature patient. We describe a novel surgical technique and the 3 year results using a Z-shaped carpal bone osteotomy reconstruction in a 22 year-old woman results.

Key words: cleft hand, lobster-claw, congenital anomalies, hand malformation, congenital hand deformity.

*bepalchuk@yandex.ru

INTRODUCTION

Cleft hand refers to a congenital condition involving variable absence of the central structures of the hand. Cleft hand is also known as central deficiency of the hand which is considered to be a longitudinal deficiency. One characteristic form of this condition has a V-shaped cleft in the palm with absence of the middle finger and severe narrowing of the thumb web. When reconstruction is desired, it is recommended that surgery be performed at about one year of age [3, 5].

Most studies in the literature describe surgical treatment for the pediatric patient. One commonly used surgical technique for the cleft hand is the Snow-Littler procedure that consists of transposition of the second ray onto the absent or hypoplastic third ray followed by a first web-space Z-plasty [7]. In contrast, Binns M. et al. [1] described a surgical procedure in a case involving an adult patient. The case presented here illustrates the results of our experience treating this condition in a young adult woman with a different surgical technique involving a Z-shaped carpal bone osteotomy. Based on this experience, we propose effective use of a Z-osteotomy technique in the adult-aged patient with typical cleft hand deformity.

HISTORY AND PHYSICAL EXAM

A right-hand dominant twenty-two year-old female university student presented with a left V-cleft hand. Due to religious reasons, the patient's parents had refused reconstructive surgery at a younger age than was presented. The patient's orthopaedic history was significant for bilateral congenital lower limb deficiencies. On examination, the middle finger ray was completely absent. There was severe narrowing of the first web space (type IIb by Manske's classification of central deficiency based on the thumb web space) [6]. There was a deep central cleft that separated the second and fourth metacarpal bones. Active flexion of the second and fourth fingers were limited, and active flexion of the fifth finger appeared close to normal (Fig. 1). Clinodactyly of the second finger was present.

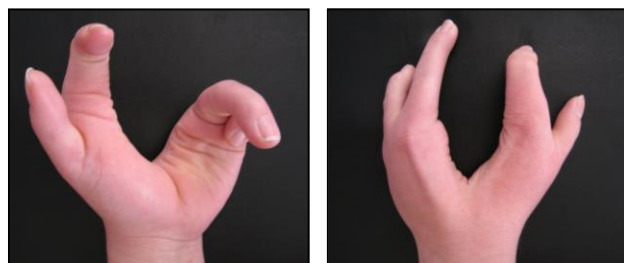


Fig. 1 - Preoperative appearance and functionality: (A) The ventral aspect of the cleft hand, (B) The dorsal aspect of the cleft hand.

Pre-operative radiographs revealed significant osseous and articular anomalies. The third metacarpal bone was severely aplastic, and the capitate and hamate bones were fused. Length of the second finger was compromised due to the hypoplasia of the second metacarpal bone (Fig. 2).

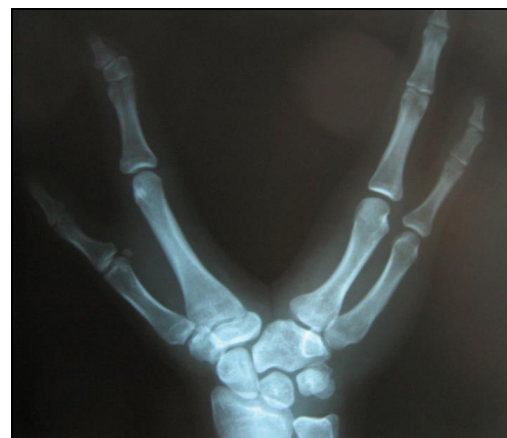

Fig. 2 - Pre-operative X-ray.

SURGICAL TECHNIQUE

The procedure began with a skin incision in palmar cleft as described by Snow and Littler (Fig 3). Deep dissection exposed the anomalous fused flexor and extensor tendons of the absent middle finger (Fig. 4). This

fused tendon unit was resected and harvested for later reconstruction of the intermetacarpal ligament.

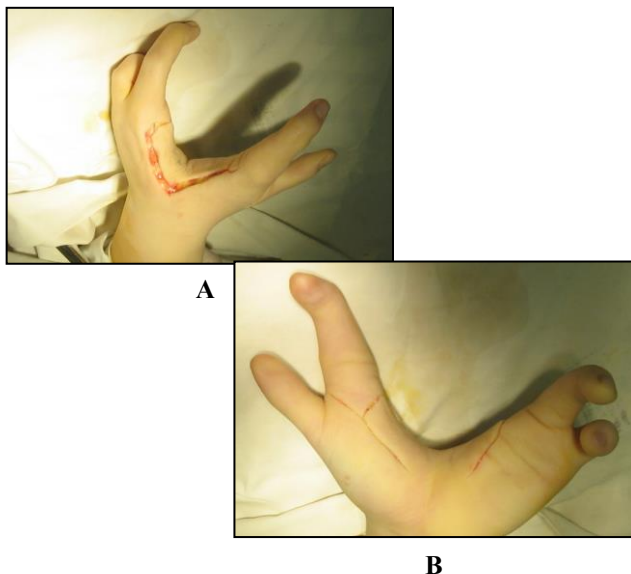


Fig. 3 - The first phase of the operation. A skin incision (Snow and Littler method): (A) The dorsal aspect of the hand, (B) The palmar aspect of the hand.

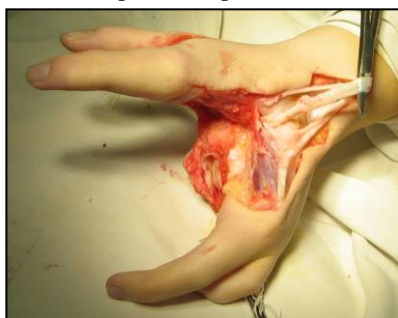


Fig. 4 - The anomalous fused flexor and extensor tendons of the absent third finger.

The next step involved a carpal osteotomy of the capitate-hamate concrescence and a marginal resection of the trapezoid and the second and third metacarpal bones (Fig. 5). The radial and ulnar portions of this osteotomy were fixed with K-wires such that the thumb was in a position of opposition (Fig. 6).

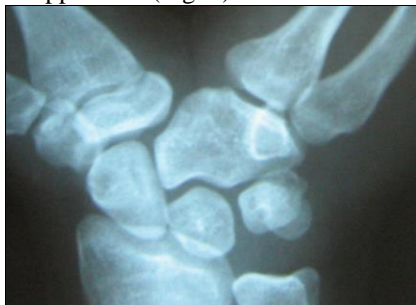

Fig. 5 Technique of the Z-shaped carpal osteotomy of the capitate-hamate concrescence and a marginal resection of the trapezoid and the second and third metacarpal bones.

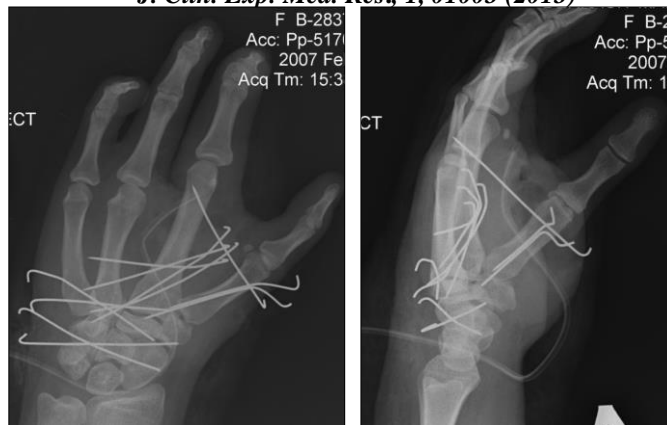

Fig. 6 - Post-operative X-ray: (A) The anteroposterior plane, (B) The lateral plane.

The second deep transverse intermetacarpal ligament was reconstructed using the harvested tendon unit. Finally, the first web space was lengthened with a Z-plasty rearrangement (Fig. 7). A drain was placed during closure and was removed on postoperative day 3. The hand was immobilized in a plaster of Paris cast for a total of twelve weeks. After immobilization, the K-wires were removed, and the patient started exercises for restoration of motion and strength.

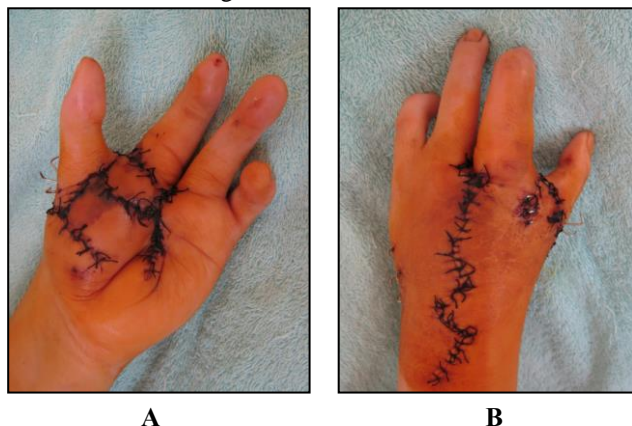


Fig. 7 - Final result after remodeling of the first web space: (A) The ventral aspect; (B) The dorsal aspect.

RESULTS

After three months, the patient resumed crutch use for ambulation, thus, able to tolerate load to a newly-formed first web space. Radiographic studies demonstrated osseous healing and remodeling (Fig. 8). At three years, the patient was working as an arts and crafts teacher at a children’s center. Radiographs and CT demonstrated complete bone remodeling in the area of the carpal osteotomy without evidence of premature arthrosis of the wrist (Fig. 9). The patient expressed continued satisfaction with her stable results including the improvement in function and aesthetics relative to her pre-operative state (Fig. 10).

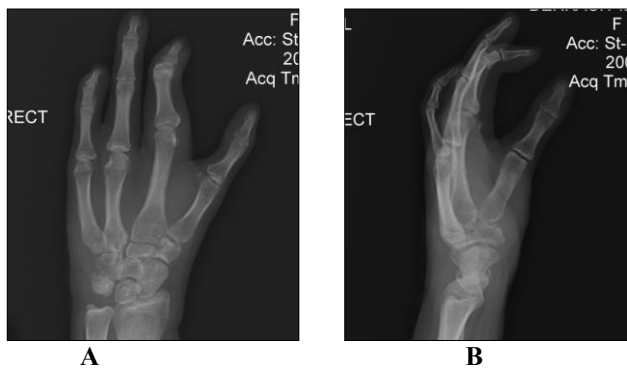

Fig. 8 - X-ray control after three months: (A) The anteroposterior plane, (B) The lateral plane.

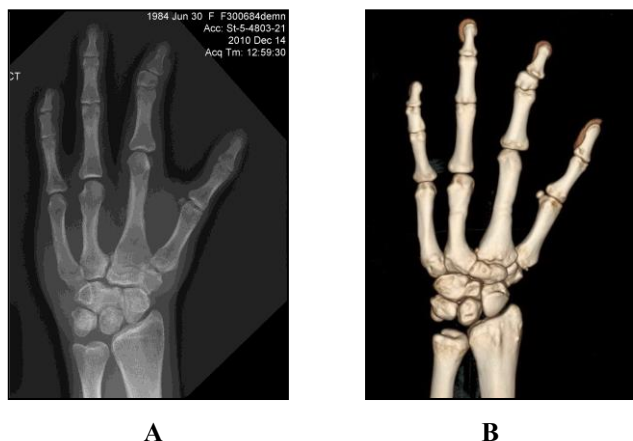


Fig.9 - Radiographs (A) and CT (B) follow-up after three years.

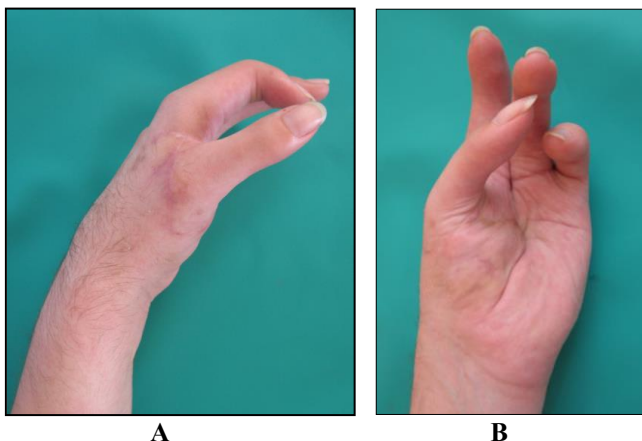


Fig. 10 - Three-year follow-up. Aesthetic e functional outcome: (A) Range of motion of the wrist joint; (B) Functionality of fingers.

DISCUSSION

Cleft hand is one of the most disfiguring congenital anomalies of the upper extremity. The indications for surgical reconstruction remain controversial. The condition may or may not alter function of daily living, and possibly carries a greater concern for having undesirable negative effects on one’s social and psychological development and health. When surgical reconstruction is requested, the authors agree that performing it at an early age is preferred [3, 5]. However,

surgeons may be faced with the rare situation in which the patient seeking treatment is a person of an adult-age.

In an original anatomic study of bilateral cleft hands, Durand S. et al. dissected an elderly cadaveric specimen and discovered fusion of the capitate and hamate, malposition of the scaphoid and a hypoplasia of the head of capitate. The authors of this study hypothesized that this configuration of abnormal carpal bone anatomy was likely an important contributing factor to the intercarpal and radiocarpal arthrosis that was discovered during dissection. Tendon abnormalities were closely associated with the dysmorphic changes of the metacarpal and phalangeal bones. The flexor and extensor tendons of the absent finger were fused as a single unit over the ends of the remaining bones [2]. In our case reported here, similar osseous findings were observed but void of the arthritic changes that were consistently present in Durand’s original anatomic study [2]. Of note, the identification and harvesting of these malunited central tendons were helpful for the subsequent reconstruction of the central intermetacarpal ligament.

Numerous surgical reconstructive procedures have been described. Most scientific papers describe surgical techniques for the pediatric cleft hand. In distinction, Binns M. et al. described reconstruction in an adult-aged patient. In this 27 year-old man, there was a hypoplastic third metacarpal bone associated with the absence of the middle finger phalanx. For this, the authors performed basal osteotomies of the fourth and fifth metacarpal bones, and then repositioned the distal parts of metacarpals in a radial direction without removing the third metacarpal. In addition, a Z-plasty of the first hypoplastic web space skin was not performed [1]. Foucher et al described a similar technique but one described in children where the osteotomy was placed within the deformed hamate in an axis that was parallel to the fifth carpometacarpal joint. The osteotomy was then transferred radially onto the distal portion of the marginally resected capitate. Skin deficits were addressed with full-thickness skin grafts [4].

In general, the most common surgical technique is the Snow and Littler procedure, which involves transposition of the second ray onto the absent or hypoplastic third ray, followed by a first web-space skin z-plasty [3, 7]. The authors believe this classic technique is sound and useful when the patient has a hypoplastic third metacarpal bone. However, the Foucher technique is preferred when appropriate because of its greater technical ease.

For our patient, we applied the major principle of Z-plasty skin lengthening that is fundamental to the Snow-Littler’s procedure. In contrast, we performed an osteotomy of the congenitally fused capitate and hamate bones. The premise for this surgical modification was based on the rationale that scaphoid repositioning to a more vertical position may decrease the risk for secondary osteoarthritis. At the three-year follow-up of our patient, degenerative changes of the wrist joint were not seen on radiographs.

CONCLUSION

The results of this case suggest that surgical reconstruction involving an osteotomy of the carpus is an effective alternative surgical method for the adult cleft hand, especially one with a severely deficient metacarpal bone which may impose limits on obtaining an optimally-desired ray transposition.

References:

1. Binns M. Correction of Lobster-claw hand in a adult / M. Binns, M. Arafa, J. Noble // Journal of Hand Surgery.-1985.-Vol.10B.-P.97-99.
2. Anatomic variation in a cleft hand of an elder cadaveric specimen/[Durand S., Delmas V., Fox M. et al.]/ Surgical and radiological anatomy.-2009.-V. 31.-P.145-148.
3. Flatt A. E. Cleft hand and central defect / Flatt A. E.// The care of congenital hand anomalies.-1994.-In (2nd ed.).-P.337-365.
4. Radial shift of the ulnar fingers: a new technique for special cases of longitudinal central deficiency/[Foucher G., Lorea P., Hovius S. et al.]/ Journal of Hand Surgery.-2006.-V. 31B(2).-P.156-161.
5. Katarincic J. A. Cleft hand / Katarincic J. A.// Journal of the American Society for Surgery of the Hand.-2003.-Vol. 3(2).-P.108-116.
6. Manske P. R. Surgical classification of central deficiency according to the thumb web / P. R.Manske, M. N.Halikas // Journal of Hand Surgery.-1995.-Vol.20(A).-P687-697.
7. An experience of th Snow-Littler procedure. [Rider M. A., Grindel S. I., Tonkin M. A., Wood V. E.]/ Journal of Hand Surgery. - 2000. - V. 25(B). - P. 376-381

ЛЕЧЕНИЕ ДЕФОРМАЦИИ РАСЩЕПЛЕННОЙ КИСТИ У МОЛОДОЙ ЗРЕЛОЙ ЖЕНЩИНЫ (КЛИНИЧЕСКИЙ СЛУЧАЙ)

Андрей Беспальчук*, ²Лана Канг

Белорусский государственный медицинский университет,
пр. Дзержинского, 83, Минск, 220116, Республика Беларусь

²Госпиталь экстренной хирургии, ул. 535 Ист 70, Нью Йорк, NY 10021, США

Расщепленная кисть это врожденная деформация руки, вызванная варьированным отсутствием центральной части кисти. Различают V-образную расщепленность кисти с несколькими сужениями межпальцевого промежутка и отсутствием среднего фаланга пальца. Большинство работ описывает лечение путем хирургического вмешательства в ранний детский период. В нашей статье приводятся данные о лечении расщепленной кисти у пациента с уже сформировавшимся скелетом. Мы описываем новейшую хирургическую технику с использованием Z-образного рассечения кости запястья при лечении 22-летней женщины и полученные на протяжении трех лет результаты.

Ключевые слова: расщепленная кисть, врожденные аномалии, деформация руки, врожденная деформация руки.

ЛІКУВАННЯ ДЕФОРМАЦІЇ РОЗЩЕПЛЕНОЇ КИСТІ У МОЛОДОЇ ЗРІЛОЇ ЖІНКИ (КЛІНІЧНИЙ ВИПАДОК)

Андрій Беспальчук*, ²Лана Канг

Білоруський державний медичний університет, пр. Дзержинського, 83 Мінськ, 220116, Республіка Білорусь

²Госпіталь екстреної хірургії, вул. 535 Іст 70, Нью Йорк, NY 10021, США

Розщеплена кисть – це уроджена деформація, яка виникла через варіювання відсутності центральної частини кисті. Вірізняють V-подібну розщепленість кисті, тобто долоня з декількома звуженнями міжпальцевого проміжку та відсутністю середнього пальця. Більшість наукових праць описують лікування засобами хірургічного втручання у ранній дитячий період. Однак, у нашій статті йдеться мова про лікування розщепленої кисті у пацієнтів зі вже сформованим скелетом. Ми описуємо нову хірургічну техніку з використання Z-подібного розщеплення кисті зап'ястя при лікуванні 22-літньої жінки та отримані протягом трьох років результати.

Ключові слова: розщеплена кисть, уродженні аномалії, деформація руки, уроджена деформація руки.