

Use of Airtraq Optical Laryngoscope for Naso-Tracheal Intubation in Anaesthetized Patients

Sunny Malik¹, Shahin N Jamil², Shraddha Malik³, Rohit Varshney⁴

¹Senior Resident, Department of Anaesthesia, Pandit Madan Mohan Malviya Hospital, New Delhi, U.P., India, ²Reader, Department of Anaesthesia, J.N. Medical College, A.M.U., Aligarh, India, ³Senior Resident, Department of Anaesthesia, ESI Hospital, New Delhi, India, ⁴Assistant Professor, Department of Anaesthesia, Teerthanker Mahaveer Medical College & Research Centre, Moradabad, U.P., India

Reported is a case of successful Nasotracheal intubation using Airtraq optical laryngoscope in a patient of fracture zygomatic arch with cervical spine injury. The patient had predicted difficult direct laryngoscopy with restricted mouth opening.

Keywords: Airtraq Nasotracheal intubation, Optical

INTRODUCTION

Nasotracheal intubation, a procedure not routinely used as a method of intubation but required in patients undergoing maxillo-facial surgeries (oral and dental) to provide better field of view to surgeons. Direct laryngoscopy with Macintosh laryngoscope and Magills forceps is the most widely accepted method for Nasotracheal intubation, but it requires expertise.¹ The Airtraq laryngoscope (Figure 1) is a battery powered optical device which provides a high grade, indirect close view of the glottis without the alignment of the oral, pharyngeal and laryngeal axes. Airtraq laryngoscope provides an unobstructed view of the glottis easily allowing the anaesthesiologist to quickly visualise the target to which endotracheal tube is directed. It reduces the chances of damage to the cuff of the tracheal tube caused by the arms of the Magills forceps. Moreover, the blade of the Airtraq laryngoscope is anatomically shaped, so there are less chances of injury to the anterior airway as compared to Macintosh laryngoscope.² Hence Airtraq laryngoscope provides superior intubation conditions and takes lesser time to secure the airway.^{2,3}

CASE

A patient, 55year male was brought to casualty of J.N Medical college Hospital after road traffic accident. On examination, he was diagnosed as a case of zygomatic arch fracture right side with cervical spine injury. He was scheduled for elective open reduction and plating of the zygomatic arch. His vitals (Pulse rate - 80/min, regular, normal volume with no special character; Blood

pressure- 140/90 mm of Hg; Pallor- present; Icterus, cyanosis, clubbing, lymphadenopathy, edema- absent) and relevant investigations (Hemoglobin- 9 gm %; TLC- 6500 cells/cu mm; DLC- P70 L28 E02 B00; Blood sugar(R)- 125 mg %; Blood urea- 40 mg %; Serum creatinine- 0.85 mg %; ECG & X-Ray chest PA view- Nothing abnormality detected) were found to be within normal limits. Pre-anaesthetic check-up was done which included routine airway evaluation of dentition, mouth opening, tongue size, Mallampatti grading and neck mobility. Our patient was found to be edentulous with Mallampatti grade IV due to reduced mouth opening of about 16 mm.

ANAESTHETIC TECHNIQUE

Informed consent was taken from the patient. Patient was intubated by nasal route using standard protocol.⁴ Difficult airway cart including the instruments of surgical airway techniques (cricothyrotomy, tracheostomy) were kept ready. Nasal patency was equal on both sides and the right naris was selected for Nasotracheal intubation as the bevel of most of the endotracheal tubes will face the flat nasal septum minimising damage to the turbinates. We instilled cotton-tip pledgets soaked with 2 % Xylocaine with 1:200000 epinephrine in both the nasal passages 10-15 minutes prior to intubation. Premedication was done with Inj. Ondansetron 4 mg IV, Inj. Tramadol 100mg iv and Inj. Midazolam 2 mg iv. Patient was pre-oxygenated with 100% O₂ for 3 minutes and induced with Inj. Thiopentone 250 mg IV, face mask ventilation was uneventful. Next the patient was relaxed with Inj. Succinyl choline 75 mg iv.

Corresponding Author:

Dr. Sunny Malik, Senior Resident, Department of Anaesthesia, Pandit Madan Mohan Malviya Hospital, New Delhi.
E-mail: dr.malik_sunny@yahoo.co.in

Cuffed endotracheal tube 7.0 mm PVC type lubricated with Xylocaine jelly was introduced to the half of its length into right nasal passage. Airtraq laryngoscope prelubricated with Xylocaine jelly, introduced inside the mouth in the midline, over the centre of the tongue (Figure 2). The blade was introduced till its tip was positioned in the vallecula. It was now manipulated to get the central view of the glottic aperture. Under its visual guidance, Nasotracheal intubation was done pushing the endotracheal tube through the abducted vocal cords. Correct placement of the tube was confirmed by capnography and auscultation. This whole procedure took place for about 12 seconds. The duration of Nasotracheal intubation was taken from the interruption of intermittent positive pressure ventilation to connecting of endotracheal tube to the anaesthesia circuit. Patient was maintained on O₂ + N₂O + IPPV + Inj. Vecuronium. All the vital parameters including the pulse rate, blood pressure and SpO₂ were maintained throughout the surgery which took place for about an hour. After the surgical process, the patient was successfully extubated with the recovery, reflexes, respiration and vitals found within normal limits.

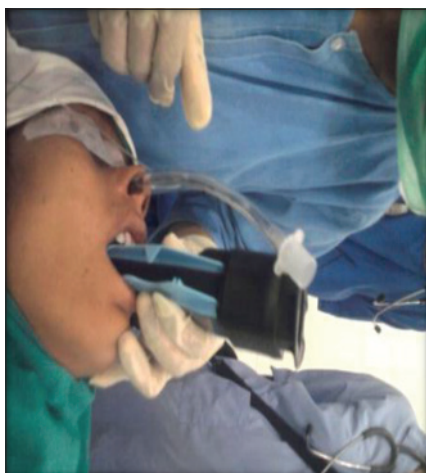


Figure 1: Nasotracheal intubation guided by airtraq laryngoscope



Figure 2: Airtraq optical laryngoscope

DISCUSSION

The case presented on an elective PLASTIC SURGERY list with a restricted mouth opening as a result of fracture zygomatic arch with limited cervical mobility, that created a difficulty in insertion of endotracheal tube through mouth. Nasotracheal intubation was also opted to provide sufficient field to surgeon to mend the zygomatic fracture. Although Nasotracheal intubation is a difficult manoeuvre in inexperienced hands, while intubation by nasal route can be easily achieved by using Airtraq laryngoscope which provides easy intubation even by moderately experienced anaesthetists.⁵ However, use of this device needs caution on part of anaesthetist as there are reports of severe bleeding and oropharyngeal trauma.⁶ Airtraq laryngoscope reduces the duration of intubation and manoeuvre is easy to perform as seen in our case. It is possible to intubate different patient categories in the most unfavourable circumstances and in short time, it provides optimum protection of the airway. The Airtraq laryngoscope offers a new approach to tracheal intubation of patients who require cervical spine immobilization.⁷ It can be used for intubating the patient of difficult airway as fracture zygomatic arch and cervical spine immobilization. In our study intubation by Airtraq via nasal route provided free hand movements to the surgeon for the repair of the fracture. So it can be used as a novice tool for intubation in maxillo-facial surgeries.

REFERENCES

1. Benumof JL. Conventional (laryngoscopic) orotracheal and Nasotracheal intubation (single lumen tube) In: Benumof JL ed. Airway Management- Principles and practice. St. Louis, MO: Mosby- Year Book, 1996; 261-76.
2. Hirabayashi Y and Seo N. Airtraq laryngoscope has an advantage over Macintosh laryngoscope for Nasotracheal intubation by novice laryngoscopists. *J Anesth.* 2009; 23: 172-173.
3. Hirabayashi Y, Seo N. Nasotracheal intubation using the Airtraq versus Macintosh laryngoscope: A manikin study. *Anesth Prog.* 2008; 55: 78-8.
4. Khan RM, Maroof M. Airway management Made easy- *Manual of clinical practitioners and examiners* 2009; 55: 93.
5. Missaghi SM, Krasser K, Hildegard Lackner-Ausserhofer, Anita Moser Ernst Zadrobilek The Airtraq optical laryngoscope- Experiences with a new intubation device for orotracheal intubation; *Internet journal of airway management*; vol 4 Jan 2006 to Dec 2007.
6. Schoettker P, Bathory I, Broome M. Use of nasotracheal Airtraq to assist difficult nasal fibreoptic intubation: *Canadian Journal of anaesthesia.* 2008; 55: 884.
7. Maharaj CH, Buckley E, Barto BH, Laffey JH: Endotracheal intubation in patients with cervical spine immobilization, A comparison of Macintosh and Airtraq laryngoscope; *Anaesthesiology* 2007; 107: 53-9.

How to cite this article: Malik S, Jamil SN, Malik S, Varshney R. Use of airtraq optical laryngoscope for naso-tracheal intubation in anaesthetized patients. *Acta Medica International* 2014;1(1):41-42.

Source of Support: Nil, **Conflict of Interest:** None declared.