

REVIEW CLINICAL PHARMACOLOGY AND
PHARMACOKINETICS, INTERNATIONAL
EDITION 37(1) 5-9 (2023)
©PHARMAKON-Press

Open Access Article **Clinical study**

Ultrasound detection of mammary duct dilatation after breastfeeding cessation

G. Dorovinis¹, S. Zervoudis^{1,2}, G. Iatrakis^{1,2}, A. Bothou^{1,2},
S. Kalantaridou³

(1) Rea hospital, Athens, Greece

(2) Department of Midwifery, University of West Attica (UniWA), Athens, Greece

(3) University Hospital Attikon, Athens, Greece

Keywords: cabergoline, ductal dilatation, weaning, lactation, breastfeeding, lactation inhibition

Citation: G. Dorovinis, S. Zervoudis, G. Iatrakis, A. Bothou, S. Kalantaridou. Ultrasound detection of mammary duct dilatation after breastfeeding cessation. Rev. Clin. Pharmacol. Pharmacokinet., Int. Ed. 2023, 37,1, 5-9.

<https://doi.org/10.5281/zenodo.10051846>

Received: 18 December 2022

Accepted: 5 January 2023

Republished: 27 October 2023

Publisher's Note: PHARMAKON-Press stays neutral with regard to jurisdictional claims in published maps and institutional affiliations.



Copyright: © 2023 by the authors.

Licensee PHARMAKON- Press, Athens, Greece. This article is an open access article distributed under the terms and conditions of the Creative Commons Attribution (CC BY) license. (<http://creativecommons.org/licenses/by/4.0/>).

Corresponding author: Prof. Stefanos Zervoudis MD, PhD, Rea Hospital, 383 Syggrou Avenue .Palαιο Faliro GR-17564, Greece. Tel: 00306944308777. Email: szervoud@otenet.gr ; szervoudis@uniwa.gr

SUMMARY: Mammary duct ectasia was assessed after breast feeding in two groups of patients; without any medication and with cabergoline. The group treated with this medicine presented a reduction of the duct dilatation.

INTRODUCTION

Mammary duct ectasia (MDE) is considered the focal dilatation and inflammatory disorder (periductal mastitis) of the lactiferous ducts affecting the nipple and the areola complex. The words “ectasia” and “dilatation” are deriving from the Greek language (“ektasi” and “diastoli” respectively) and, in certain cases, are used as synonyms. Focal dilatation of the lactiferous ducts is due to endoluminal plugs of thick secretions and cellular debris. Loss of duct wall elastin with associated periductal inflammation and fibrosis are concurrent histopathologic findings. However, it is uncertain if duct ectasia and periductal inflammation are to be considered as a single disease or two distinct disease entities (1) (Hamwi & Winters 2022). Thus, many clinicians consider mammary duct ectasia and periductal mastitis as distinct pathology conditions. In women presenting with nipple discharge, MDE is included in the differential diagnosis since in 6 to <60% of those patients, MDE could be the final diagnosis. Imaging assessments, among others, especially in young

women, include ultrasound imaging (method of choice in those younger than 35), galactogram (2) (Iatrakis 2020) or duct endoscopy. Ultrasound findings (3) (Wood 2021), among others, can include mammary duct dilatation and mixed masses (≥ 6 mm) close to the areola complex.

Although successful breastfeeding is crucial for a child's development, there are situations where breastfeeding should be stopped. Since lactation is included in the risk factors of the condition, and that to date, there is no gold standard for breastfeeding cessation, it would be interesting to compare two methods of lactation cessation in terms of duct dilatation impairment.

AIM

Considering that ductal dilatation is, at least, one (or the sole) characteristic of the above condition, the aim of the present study was the ultrasonographic evaluation of the effect of medication versus non-medication on ductal dilatation in women wishing to stop breastfeeding.

MATERIAL AND METHOD

This is a prospectively blind single correlation study. The study population consisted of women who were

adults, breastfeeding and wishing to stop breastfeeding one month after delivery. The women were divided into two 2 groups. In the first group, women received 500 mcg of cabergoline (4) per day for 7 days for breastfeeding cessation. In the second group, the women weaned gradually, reducing the number of times they breastfed during the 24-hour period.

RESULTS

Totally, 24 women aged 31.5 ± 3.6 years were included, of which 66.7% were first-born, 62.5% gave birth by normal delivery (Fig. 1) and 14 (58.3%) women were weaned with medication. Mode of delivery (Fig. 1) did not influence the results. In total, 10 (41.7%) women had ductal dilatation during the first ultrasound and 6 (25%) women had ductal dilatation during the second ultrasound. Duct dilatation decreased in the medication group (35.7% vs. 14.3%, $p = 0.049$ [Fig. 2]), while in the non-medication group there was no statistically significant difference (50% vs. 40%, $p = 0.331$ [Fig. 3]). Furthermore, in certain cases, the reduction of duct dilatation was more prominent in the medication group compared to the non-medication one (Figures 4).

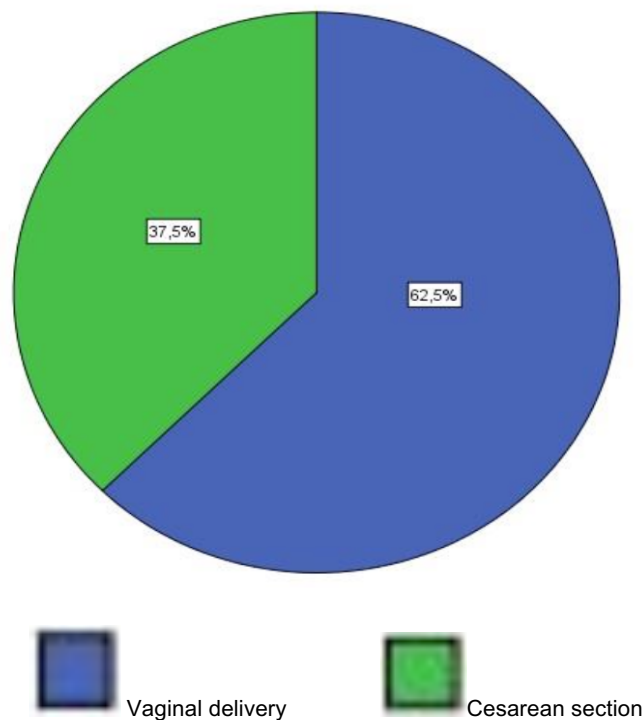


Figure 1. Mode of delivery in women included in the study.

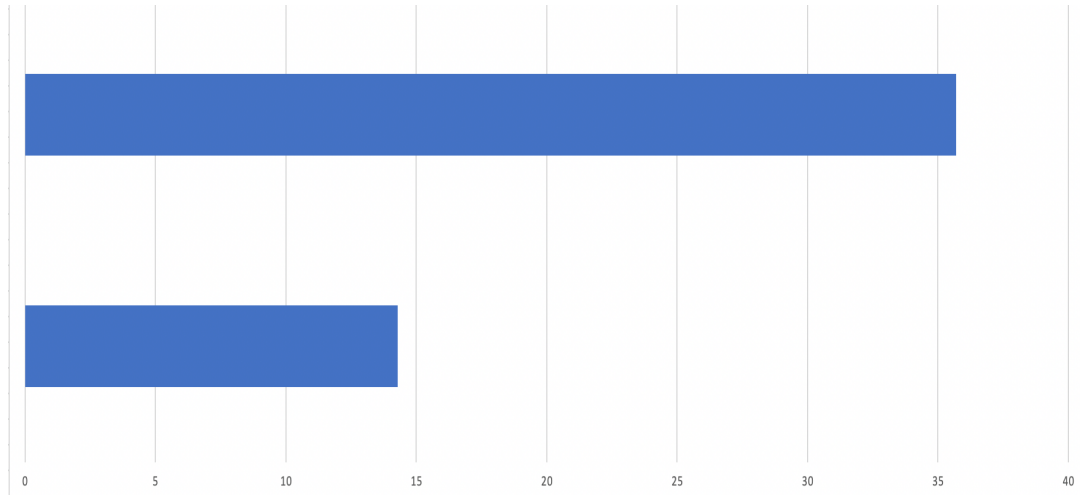


Figure 2. Percentage of duct dilatation before (upper bar) and after (lower bar) pharmaceutical treatment ($p < 0.05$).

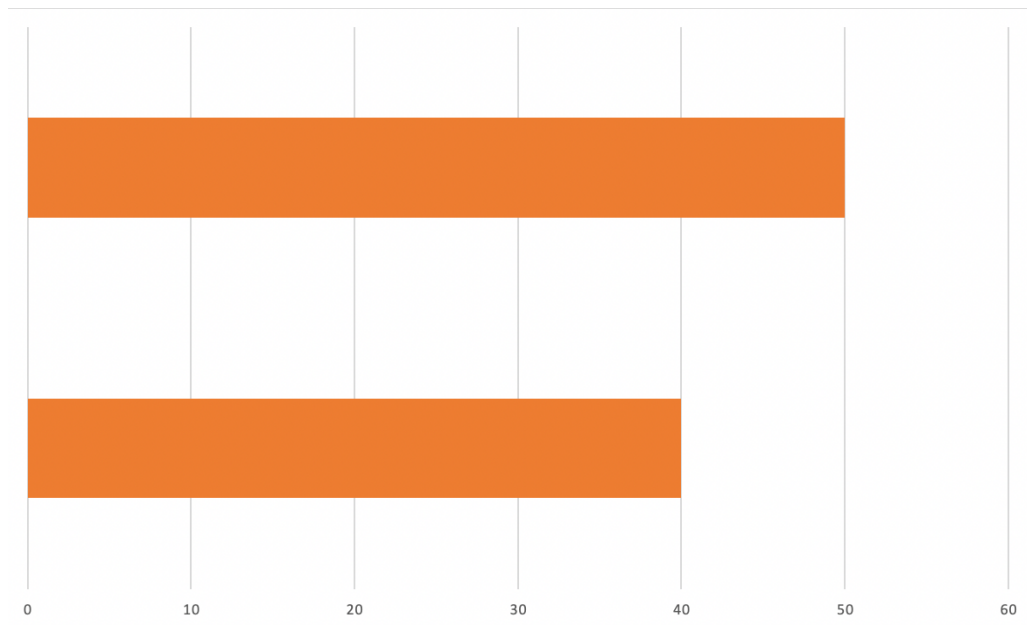
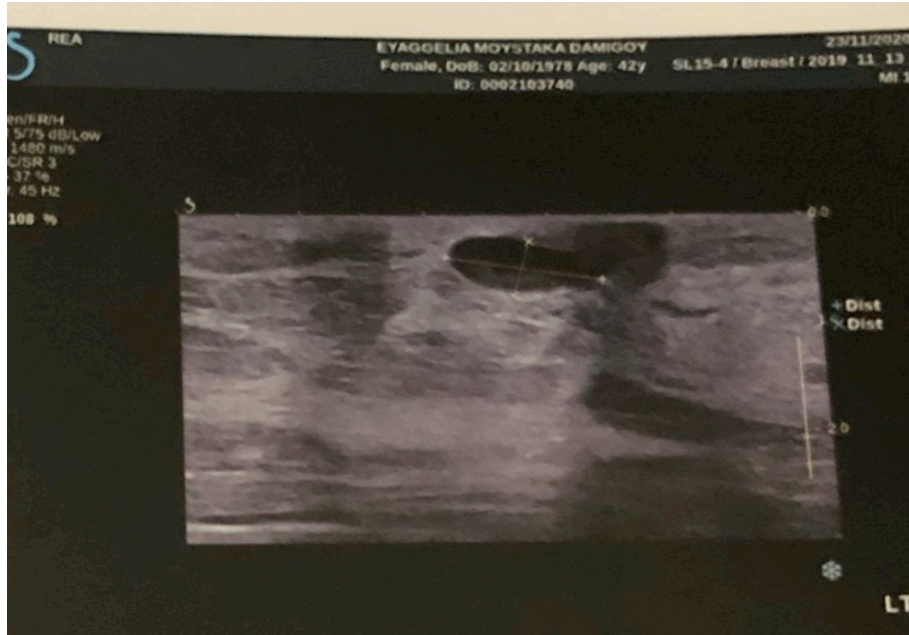
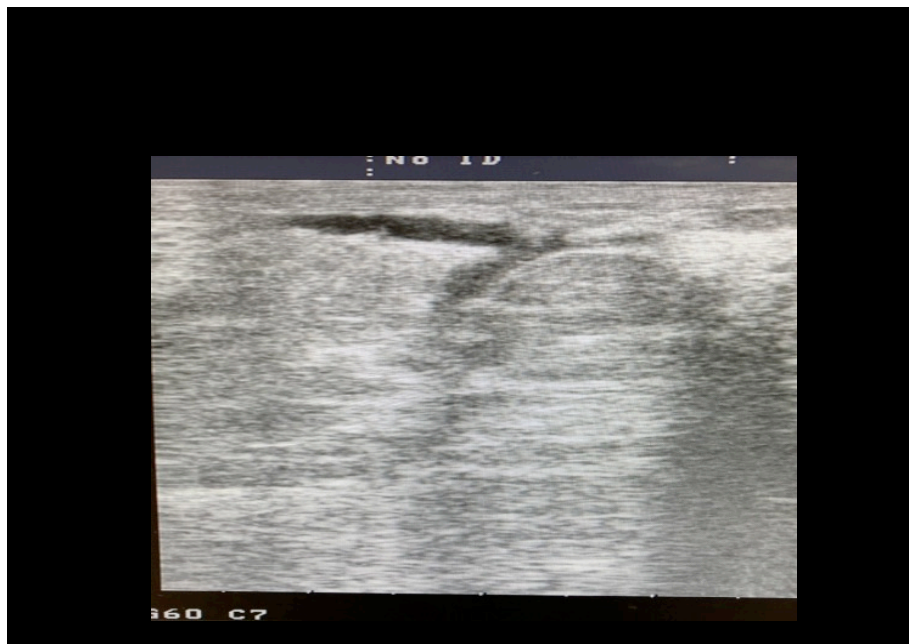
Figure 3. Percentage of duct dilatation before (upper bar) and after (lower bar) observation period without pharmaceutical treatment ($p > 0.3$).



A.



B.

Figure 4. Prominent reduction of duct dilatation in the medication group (A. start, B. end of the observation period).

DISCUSSION

Mammary duct ectasia (MDE) includes the focal dilatation and/or inflammatory disorder of the lactiferous ducts. Many clinicians consider mammary duct ectasia and periductal mastitis as distinct pathology conditions. Considering that mammary duct ectasia could “precede” other pathology alterations, the latter view seems logical, at least in some cases. Actually, pregnancy and lactation are associated with enlargement of the size of the mammary ducts and thus an increase of the risk for the development of local stasis and subsequent infection. “Risk factors” of this abnormality include pregnancy, lactation, abortion and smoking (1)(5)(6)(Hamwi & Winters 2022, Mohamed 2021, Rahal et al 2005). Women with congenital nipple inversions or malformations are also at increased risk (1)(Hamwi & Winters 2022). In particular, lactation has a strong association with the disease.

Our study showed that duct dilatation was decreased in the group treated with cabergoline, while in the non-medication group there was no statistically significant difference in terms of ducts’ dilatation before and after natural weaning. Thus, medical cessation of breast feeding could be proved an effective method of decreasing the probability of duct ectasia in the future. However, it must be noted that if an abrupt cessation of breastfeeding is desired, some measures may be helpful, including wearing a tight-fitting bra for the entire day and night and the application of cold compresses. The use of cabergoline for abrupt weaning is off-label and the drug can have some serious side effects. Actually, in the US labeling, cabergoline is not indicated for the inhibition or suppression of physiologic lactation (1)(Cabergoline 2022). Moreover many antiprolactin drugs as bromocriptin quinagolide and cabergoline were proposed to decrease hyperprolactinemia. Even in hypergalactia (overabundant milk supply), cabergoline is used off label(7) (Eglash 2014). Moreover some studies showed that quinagolide is effective in patients with galactorrhea without hyperprolactinemia (8)(Zervoudis 2014). The effect of cabergoline on duct dilatation in patients with breast feeding has not yet been published in the literature and this prototype study tried to give an answer to this effect.

CONCLUSIONS

Cabergoline administration was effective and reduced ductal dilatation in women during weaning compared to women who weaned naturally. Studies with larger cases should confirm our preliminary results.

Conflicts of Interest: The author declares no conflicts of interest regarding the publication of this paper.

REFERENCES

1. Hamwi MW, Winters R. Mammary Duct Ectasia. In: StatPearls [Internet]. Treasure Island (FL): StatPearls Publishing 2022, PMID: 32491597, Bookshelf ID: NBK557665.
2. Iatrakis G. Breast Imaging. In: Gynecologic Oncology. Athens, Greece, Zevelekakis ed. 2020
3. Wood JR. Mammary Duct Ectasia: Symptomatology, Diagnosis, and Treatment. Radiol Technol 2021, 92:383M-98M
4. Cabergoline: Drug information. UpToDate 2022.
5. Mohammed AA. Mammary duct ectasia in adult females; risk factors for the disease, a case control study. Ann Med Surg (Lond) 2021, 62:140-44.
6. Rahal RM, de Freitas-Júnior R, Paulinelli RR. Risk factors for duct ectasia. Breast J 2005, 11:262-5.
7. Eglash A. Treatment of maternal hypergalactia. Breastfeed Med 2014, 9:423-5.
8. Zervoudis S, Iatrakis G, Galazios G, Liberis V, Tsikouras P, Koutlaki N, Mastorakos G, Badiu C. Quinagolide effects in normoprolactinemic galactorrhoea. Breast J. 2014 Mar-Apr;20(2):221-3.