

Case Report

Mystery of Mandibular First Molar With Missed Canals

Arif Ali Mir¹, Hysum Mushtaq², Imran Munawwar Shaikh³

BDS, Private Practitioner¹
Jammu & Kashmir.

MDS Endodontist²
Dental Surgeon
Jammu & Kashmir Health Services.

BDS, Microendodontist³
Private Practitioner
Pune, Maharashtra.

Abstract :

Presented here is a case where 8 canals were located in a mandibular first molar. A patient with continuing pain in mandibular left first molar even after completion of root canal treatment was referred by a dentist. Following basic laws of the pulp chamber floor anatomy and under magnification, 8 canals were located with 3 in mesial root and 5 canals in distal root. At 1 month follow-up patient was asymptomatic. The story emphasizes how understanding the rules of pulp chamber anatomy and following them when looking for extra canals might help to avoid missing canals. The case emphasizes how understanding the rules of pulp chamber anatomy and following them when looking for extra canals might help to avoid missing canals.

Introduction

To undertake endodontic therapy, adequate knowledge of the anatomy of the root canal system is required. The inability to comprehend the internal anatomy of the tooth and subsequent insufficient endodontic therapy are two key reasons why root canal therapy fails.¹ In order to avoid missing anatomy during surgery, a good pre-operative radiograph is required. However, it is not always guaranteed to show the precise number of canals present in the root.

Numerous studies on the root canal morphology of various populations have demonstrated how the internal complexity of the root canal is genetically determined^{2,3}. Additionally, as people age, secondary dentine deposition creates root canal system divisions and substantial differentiations that lead to independent canals and transverse linking systems.

The internal anatomy of the mandibular first molar has been studied extensively using a variety of approaches. Even though type IV and type I root canal systems are the most

frequently encountered (in the mesial & distal roots, respectively), mandibular first molars sometimes have complicated anatomy⁴. Many occurrences have been documented where the first molar on the mandible has more than five canals⁵. Based on clinical and intra-oral periapical radiography observations, Reeh reported the presence of 7 canals in the mandibular first molar, with 4 canals in the mesial root and 3 canals in the distal root.

This case report describes successful non surgical management of a mandibular first molar with 8 canals.

Case Report

A 30 years old male patient came with a chief complaint of persistent pain in his lower left back tooth region from past few days. On Examination medical history was non contributory. Patient has already undergone root canal treatment with respect to same

Access This Article Online

Website:
www.healtalk.in

Quick Response Code:



DOI: <https://doi.org/10.5281/zenodo.11000918>

How to cite this article: Mir A et al.: Mystery of Mandibular First Molar With Missed Canals, *HTAJ OCD.2024; March-April(4):43-45.*

tooth few months back .On radiographic examination root canal treatment was already being performed with respect to 46 .Four canals were already obturated in 46 . On clinical examination there was tenderness on percussion .We were able to predict the causes of the persistent symptoms based on the aforementioned data. A diagnosis of apical periodontitis of a root canal treated tooth with missed canal in 46.

Inferior alveolar nerve block was administered using 2% Lignocaine with 1 : 80,000 epinephrine (Indoco Remedies Ltd., Mumbai, India).Prior to treatment, radiographs of the tooth revealed an apical periodontitis

(Figure 1(a)) .After removal of the temporary restoration, four canal orifices (mesiobuccal, mesiolingual ,distobuccal and distolingual) were visible initially. Other orifices were located using DG16 and Champagne bubble test .Exploration was carried out along the isthmus extending between and beyond the distolingual and distobuccal canals. Two further canals were discovered, one buccal and one lingual to the previously considered distobuccal canal. Hence, a total of 8 canal orifices were located with three in mesial root and five in distal root .

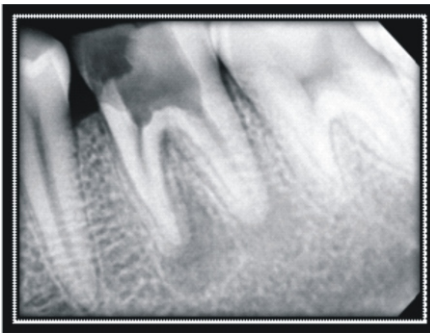


Figure. 1 :Post OperativeView

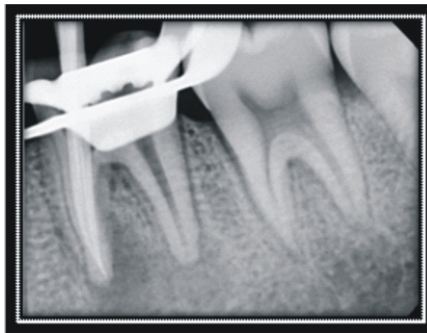


Figure. 2 : With three canals in mesial root

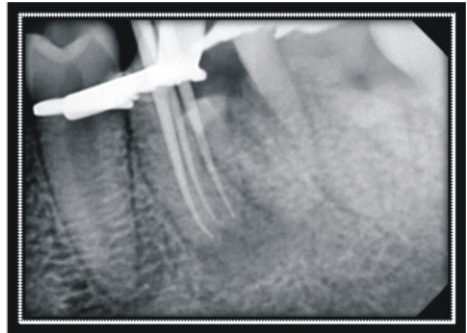


Figure. 3 : Mesial Angulation View with three canals in mesial root

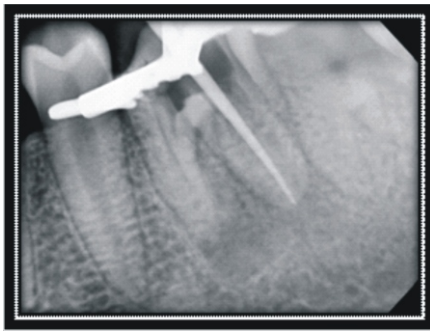

Figure.4 : First canal of distal root

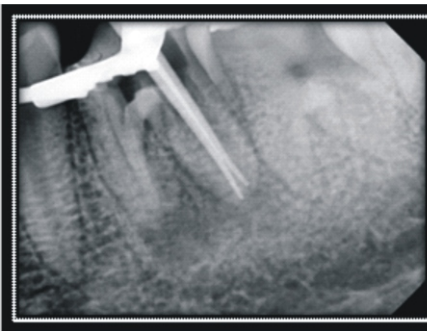

Figure. 5 : Second canal of distal root

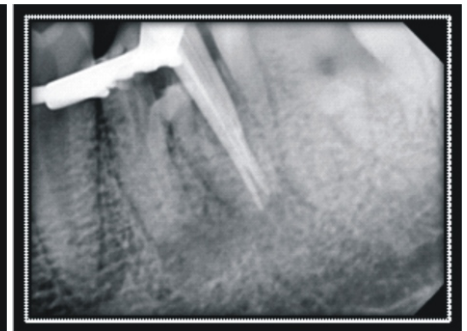


Figure. 6 :Third canal of distal root

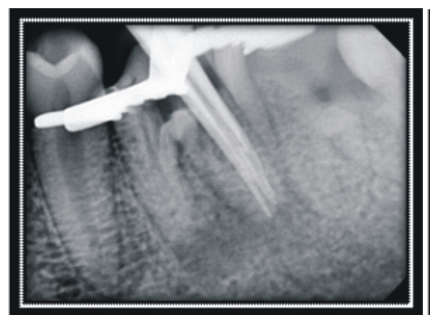


Figure. 7 : Fourth canal of distal root

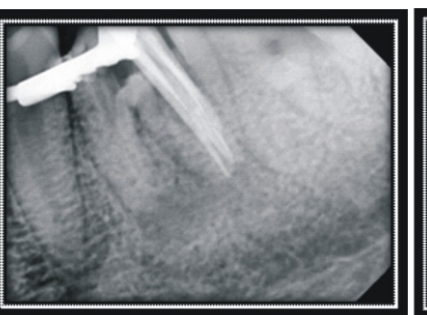


Figure. 8 : Fifth canal of distal root

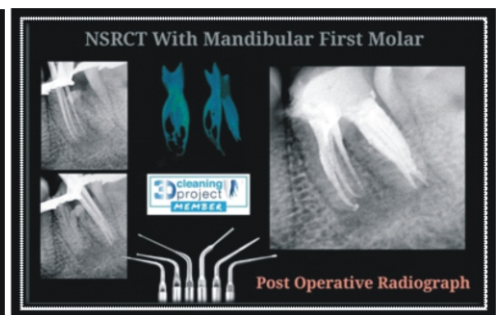


Figure. 9: Post operative View

Discussion:

By using fundamental ideas and adhering to the parameters of the anatomy of the pulp chamber floor in the present case, the canals could be found. Mandibular molars often have four additional canals that are concealed by a dentinal protrusion that is lighter in colour than the pulp chamber floor⁶. In the current case, this was evidently the case. Here magnification plays a major role both use of loupes and operating microscope. Despite the fact that operating microscopes increase the likelihood of discovering more canals with a lower rate of accidents, it is known that loupes also boost this likelihood.

To prevent post-treatment disease, pain, and/or problems of an endodontically treated tooth, adequate root canal therapy involves identifying, shaping, cleaning, and obturating every root canal system⁷.

There are various morphological variances in teeth, which makes root canal therapy more difficult. In order to treat the root canal system and improve treatment outcomes, the physician must be familiar with these variances and use the resources at their disposal⁸.

Numerous earlier publications have noted the existence of three canals in the mesial root of the mandibular first molar. Type II and type IV configurations were the most prevalent ones discovered in mesial roots^{9,10}. Few case reports have also mentioned four canals^{5,11}. One canal has been discovered most frequently in the distal root of mandibular first molars, however in one study, two canals were discovered in as many as 57.7% of molars. Additionally, there is literature that attests to the distal root's three and four canals. This instance reports a mandibular first molar with five canals present in its mesial root and three canals present in its distal root.

The presence of 8 separate orifices justifies the case's uniqueness with Vertucci Type VIII configuration in mesial root and unique configuration of 5 orifices with 5 exits in distal root. The secondary dentin deposition that created the numerous partitions that resulted in the reticular shape with several vertical canals is what caused the anatomy to become so complex. However, because each orifice was distinct and each canal could be

instrumented separately, it was acceptable to count each one as a separate canal.

Conclusion:

The aforementioned instance serves as further evidence that using cutting-edge diagnostic and visual tools is not necessary in all cases to locate new canals. Atypical anatomy can be found by the application of sound knowledge and a dedication to revealing the interior structure.

References:

1. Vertucci FJ. Root canal morphology and its relationship to endodontic procedures. *Endod Topics*. 2005;10:3–29.
2. Schäfer E., Breuer D., Janzen S. The prevalence of three-rooted mandibular permanent first molars in a German population. *Journal of Endodontics*. 2009;35(2):202–205. doi: 10.1016/j.joen.2008.11.010.
3. Neelakantan P., Subbarao C., Subbarao C. V. Comparative evaluation of modified canal staining and clearing technique, cone-beam computed tomography, peripheral quantitative computed tomography, spiral computed tomography, and plain and contrast medium-enhanced digital radiography in studying root canal morphology. *Journal of Endodontics*. 2010;36(9):1547–1551. doi: 10.1016/j.joen.2010.05.008.
4. De Pablo OV, Estevez R, Péix Sánchez M, Heilborn C, Cohenca N. Root anatomy and canal configuration of the permanent mandibular first molar: a systematic review. *J Endod*. 2010;36:1919–1931.
5. Reeh ES. Seven canals in a lower first molar. *J Endod*. 1998;24:497–499.
6. Cantatore G, Berutti E, Castellucci A. Missed anatomy: frequency and clinical impact. *Endod Topics*. 2006;15:3–31.
7. Sjögren U, Hagglund B, Sundqvist G, Wing K (1990) Factors affecting the long-term results of endodontic treatment. *J Endod* 16(10): 498-504.
8. Bansal P, Nikhil V, Shekhar S (2015) Three distal root canals in mandibular first molar with different canal configurations: Report of two cases and literature review. *Saudi Endodontic Journal* 5(1): 51- 55.
9. Kottoor J, Sudha R, Velmurugan N. Middle distal canal of the mandibular first molar: a case report and literature review. *IntEndod J*. 2010;43:714–722.
10. Baugh D, Wallace J. Middle mesial canal of the mandibular first molar: a case report and literature review. *J Endod*. 2004;30:185–186.
11. Goel NK, Gill KS, Taneja JR. Study of root canals configuration in mandibular first permanent molar. *J Indian SocPedodPrev Dent*. 1991;8:12–14