

Rehabilitation of Partially Edentulous Mandibular Arch With Claspless Cast Partial Denture

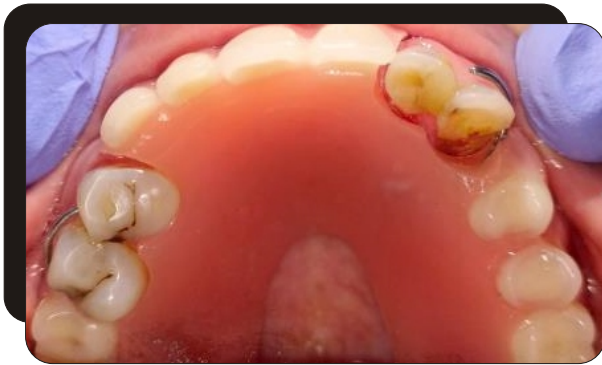
Dr. Komalpreet Kaur, Dr. Lalit Kumar, Dr. Shefali Singla, Dr. Sunint Singh

DOI: <https://doi.org/10.5281/zenodo.10071105>

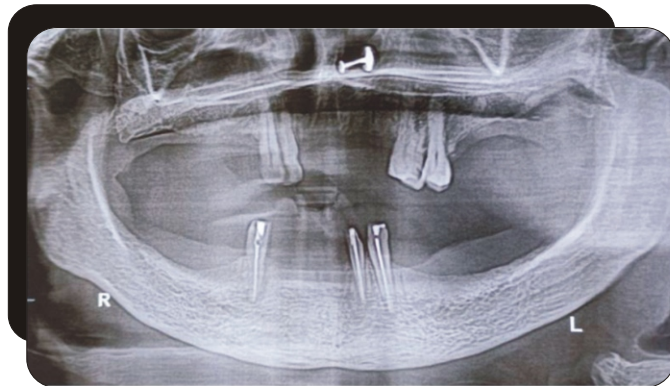
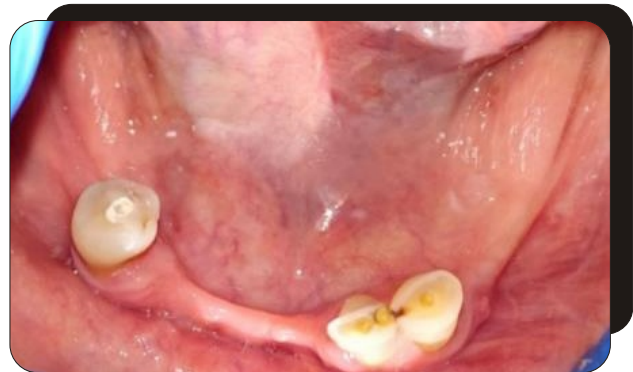Dr Harvansh Singh Judge Institute of Dental Sciences and Hospital, Chandigarh

A 55-year-old female patient came to the department with existing maxillary removable partial denture and Kennedy's class I modification I situation in lower arch.

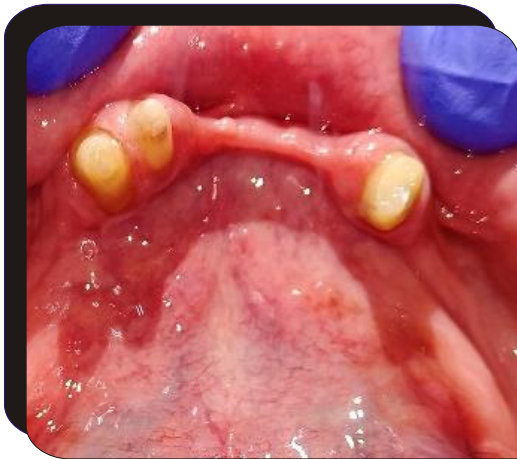Pre-OP Photographs



Occlusal view of maxillary arch and mandibular arch

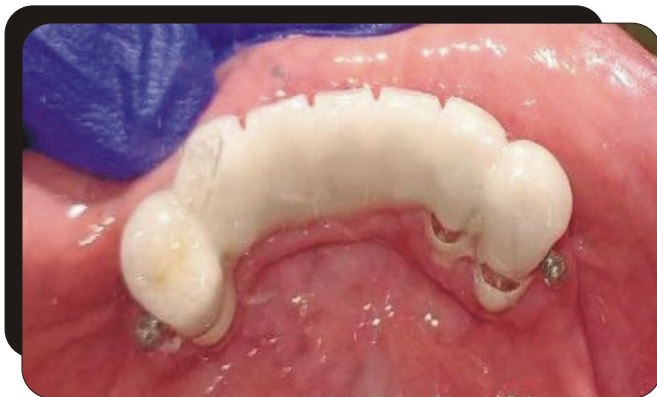
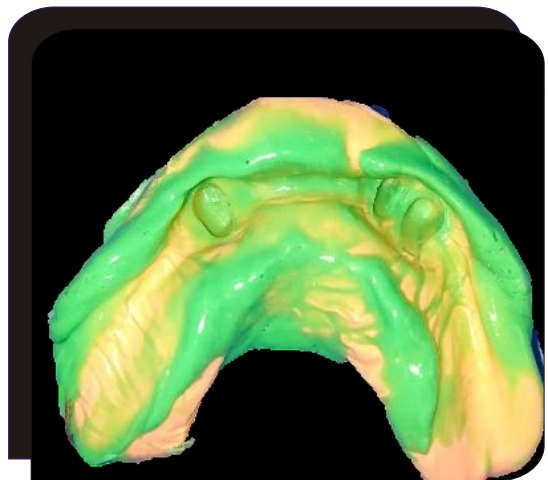
Pre-operative OPG



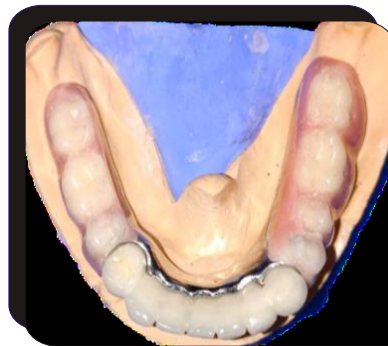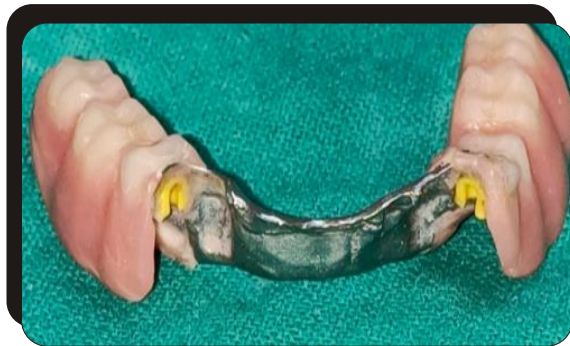
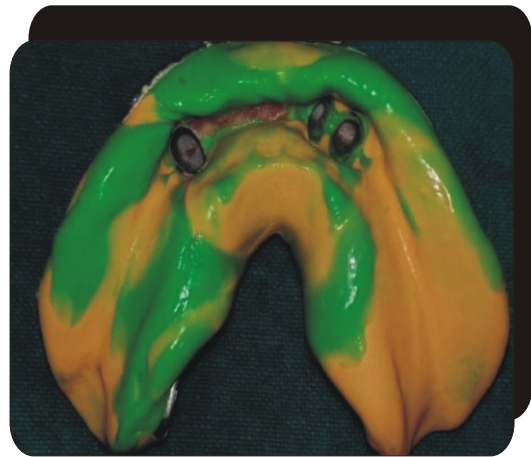
Tooth preparation # 32,33,44

Single step putty-light body impression of mandibular arch

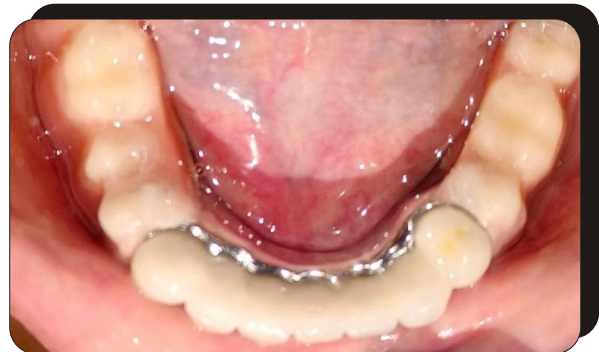
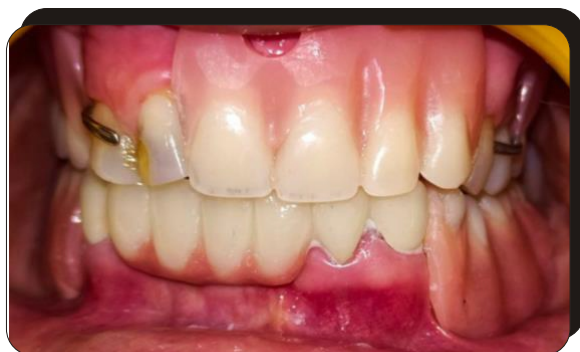
Intra-oral photograph of FPD with precision attachment (SAGIX)

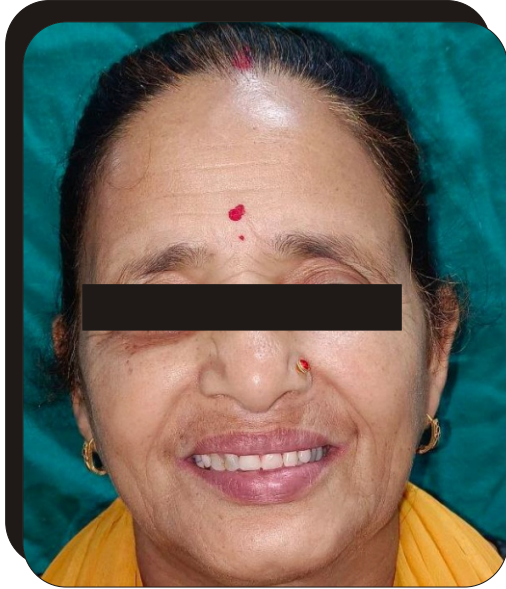Pick-up impression



Extra-oral photographs of Final Prosthesis



Intra-oral photographs of Final Prosthesis



**Extra-oral Post-operative
photograph**

Patient was satisfied with previous maxillary partial denture. Mandibular ridge was severely resorbed so fixed dental prosthesis (FDP) w.r.t 33-44 with bilateral precision attachment supported Cast Partial Denture was advised to enhance support and retention to the prosthesis.