

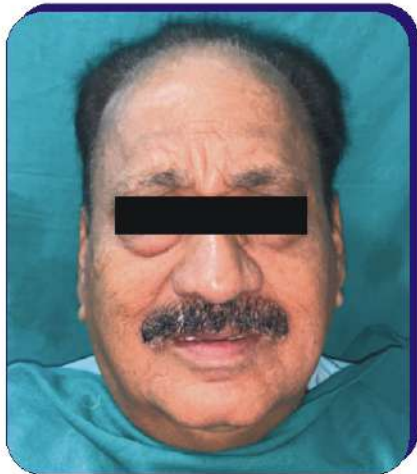## Rehabilitation of Maxillary Arch With Tooth- Implant Supported Overdenture

Dr Neha Gaur<sup>1</sup> Dr Lalit Kumar<sup>2</sup> Dr Shefali Singla<sup>3</sup> Dr Manisha Khanna<sup>4</sup>

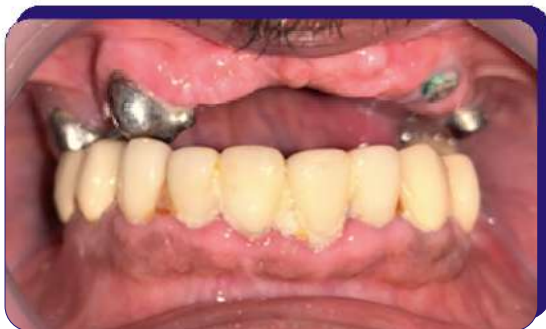Dr Harvansh Singh Judge Institute of Dental Sciences and Hospital, Chandigarh

DOI: <https://doi.org/10.5281/zenodo.8362077>

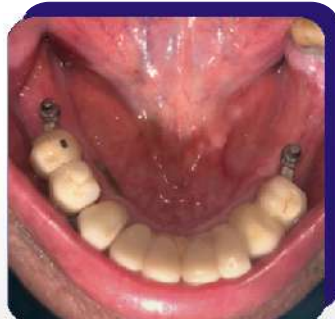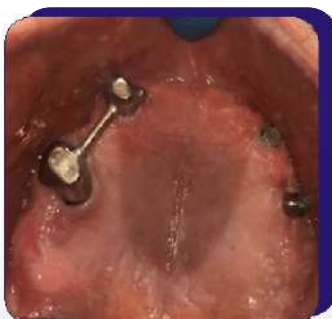A 59 years old male patient reported to the Department of Prosthodontics with chief complaint of replacement of missing teeth. Pre-operative intra-oral assessment revealed #13 and #16 splinted together with a metallic bar and two implants with secured healing abutments wrt #23 and #25 region. The mandibular arch was already restored with splinted PFM crowns along with a cast partial denture with two precision attachments. A tooth-implant supported overdenture was planned. Faulty tooth supported bars were removed and new bars with precision attachments were fabricated based on established vertical dimension. The female housings were picked up in the denture base followed by teeth arrangement, wax-up and try-in. Insertion was done and patient was thoroughly examined in follow-up appointments after 24 hours, 1 week, 15 days and 1 month.

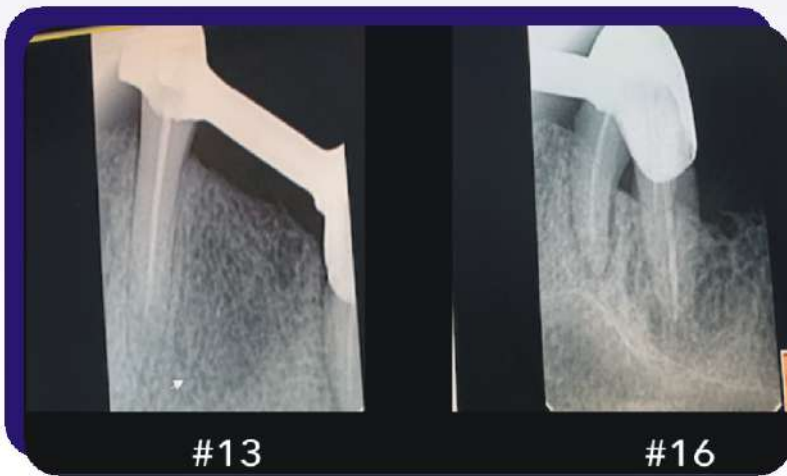


Pre- operative extra-oral profile

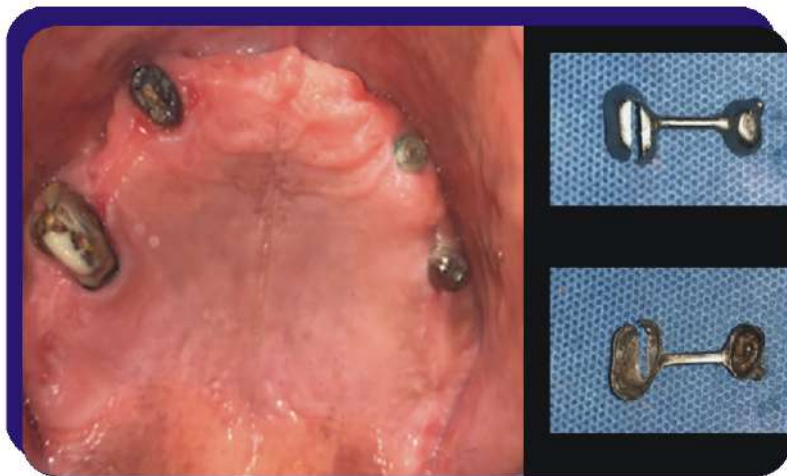

Pre-operative intra-oral frontal (top), maxillary occlusal (bottom left) and mandibular occlusal view (right)

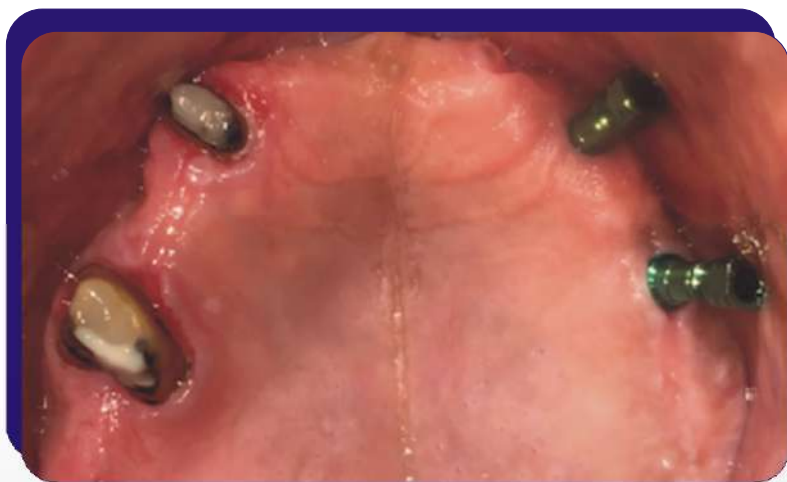



Intra-oral periapical radiograph suggestive of bone loss around #13 and #16 abutment teeth.

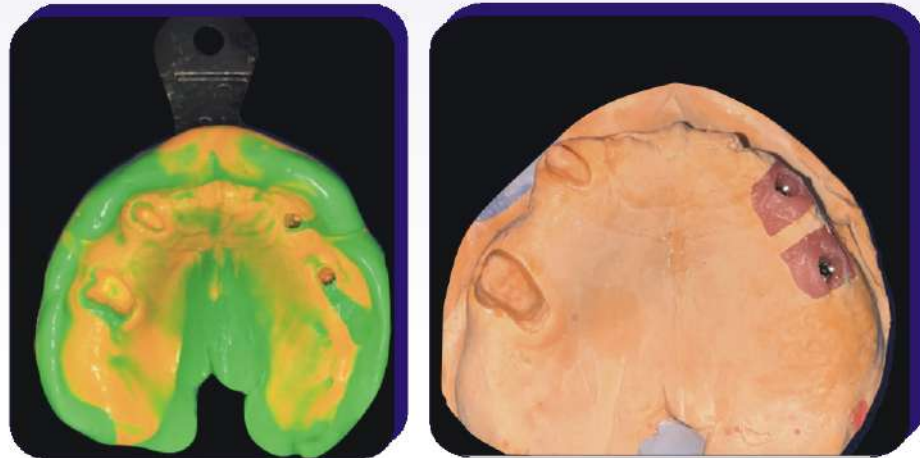


Removal of faulty bar

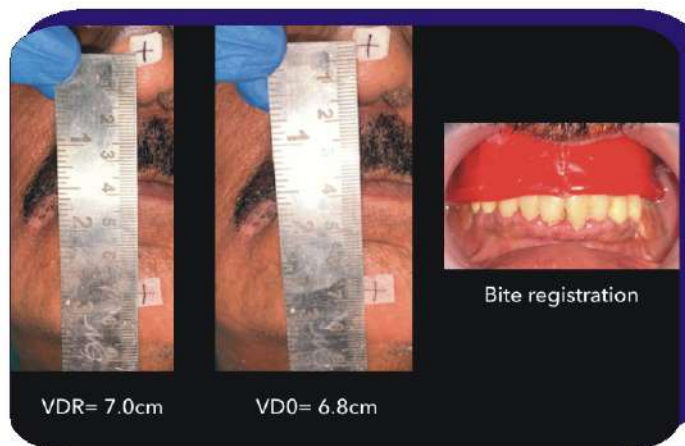

Tooth preparation wrt #13 and #16 and closed tray impression coping secured wrt #23, #25

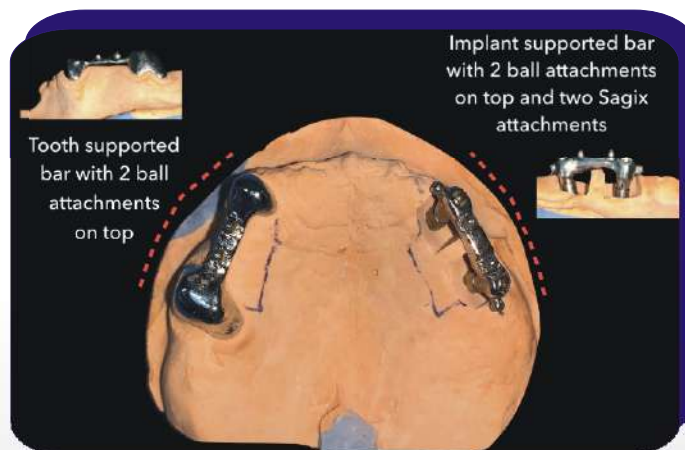
Final impression and master cast

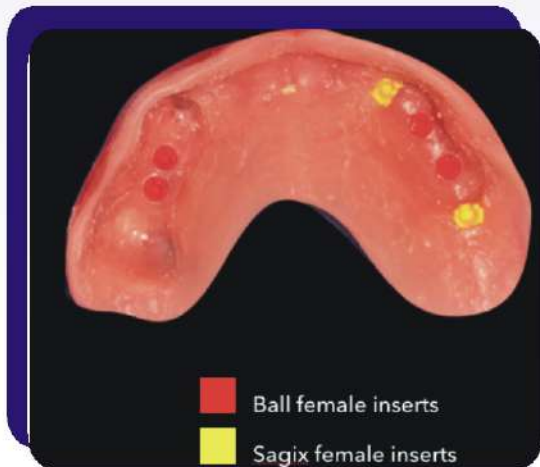


Vertical jaw relation estimation & registration of bite at desired vertical dimension

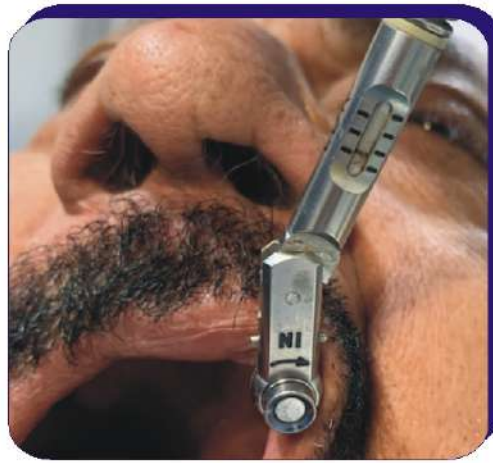


Tooth and implant supported bars with precision attachments

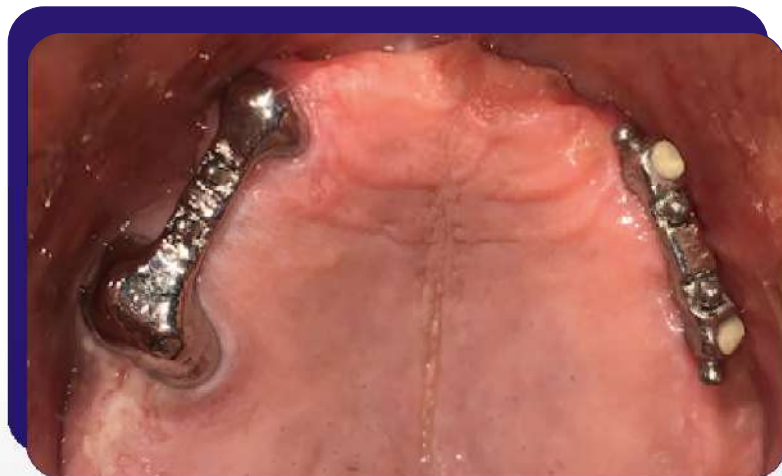



Intaglio surface of the denture base with female housings

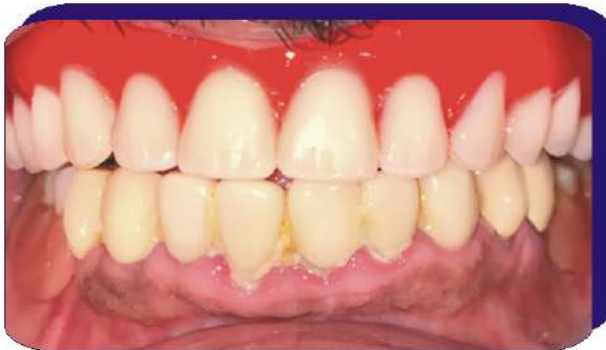
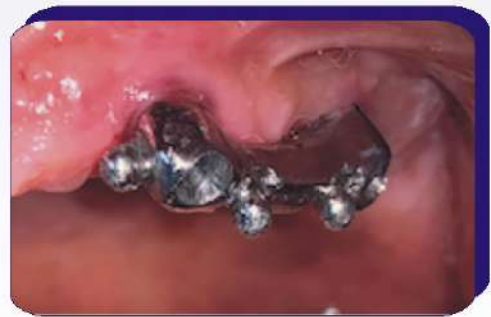
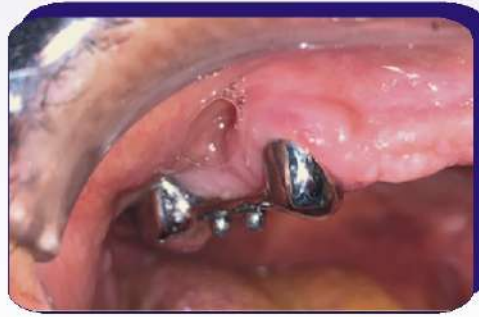Cementation of tooth supported bar with GIC luting cement and implant supported bar secured with manufacturer recommended torque.



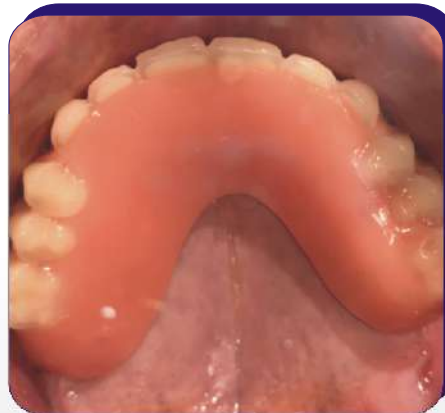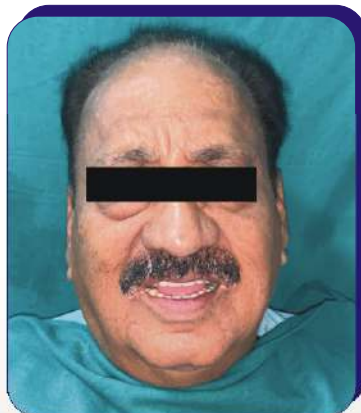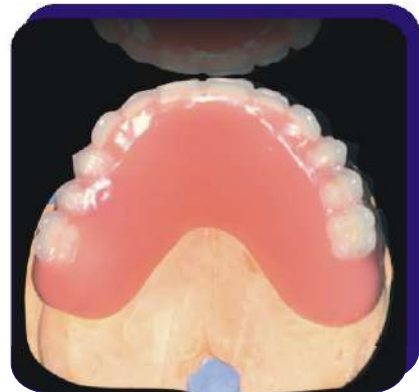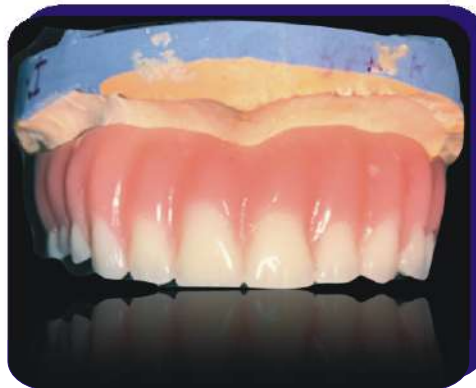Bars secured intra-orally

Lateral view (Left: Tooth supported bar, Right: Implant supported bar)



Try-in appointment

Processed maxillary denture



Denture insertion  
(Left: Extra-oral profile  
Right: Prosthesis in situ)