

## Case Report

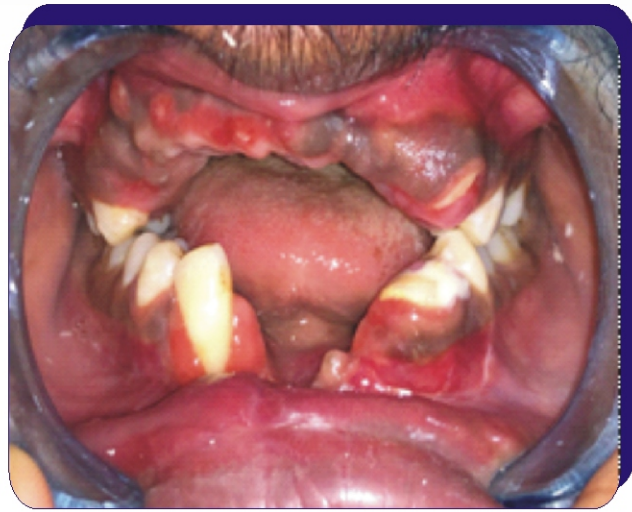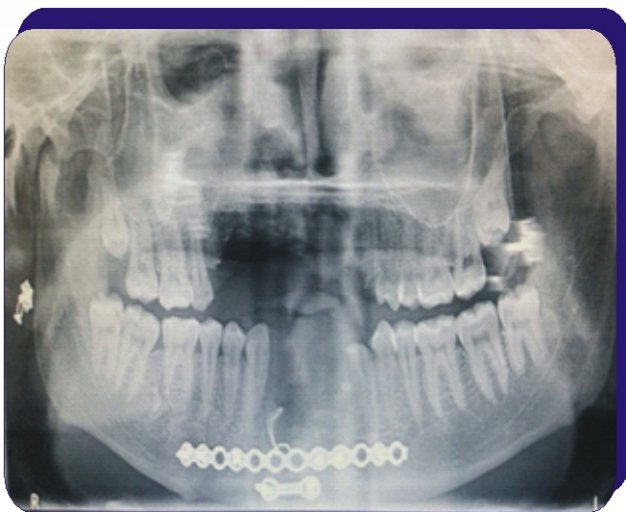DOI : <https://doi.org/10.5281/zenodo.8362071>

Dr. Yesh Sharma<sup>1</sup>, Dr. Kailash Asawa<sup>2</sup>, Dr. Mridula Tak<sup>3</sup>

<sup>1</sup>Senior lecturer, Department of Conservative Dentistry and Endodontics, Pacific Dental College and Hospital, Udaipur, Rajasthan, India, <sup>2</sup>Professor and Head, Department of Public Health Dentistry, Pacific Dental College and Hospital, Udaipur, Rajasthan, India <sup>3</sup>Professor, Department of Public Health Dentistry, Pacific Dental College and Hospital, Udaipur, Rajasthan, India

**A** patient reported to the Department office Public Health Dentistry with a chief complaint of missing upper and lower teeth since 5 months. Patient gives history of exfoliation of teeth due to trauma 5 months ago.

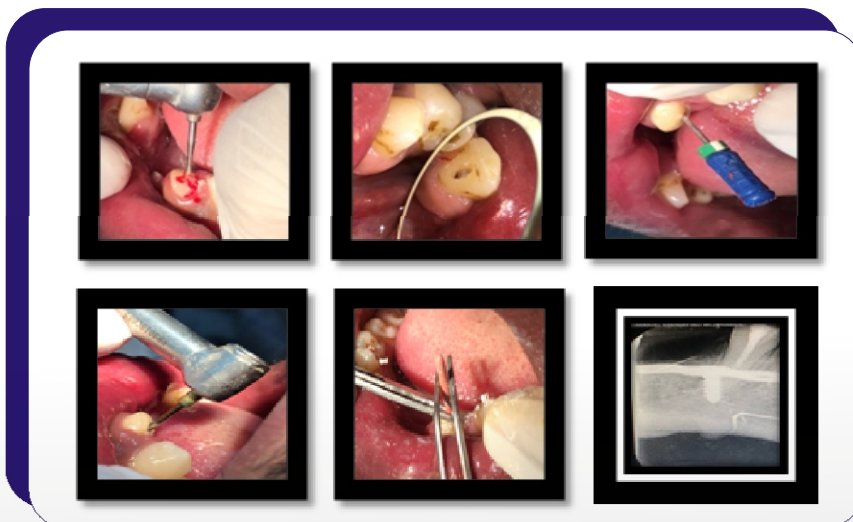
Patient undergone surgery of fracture of maxilla and mandible 5 months ago from Hospital, Udaipur.



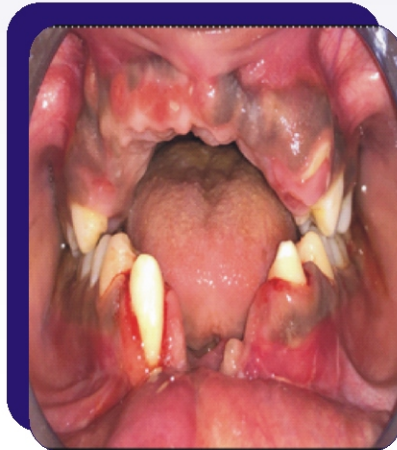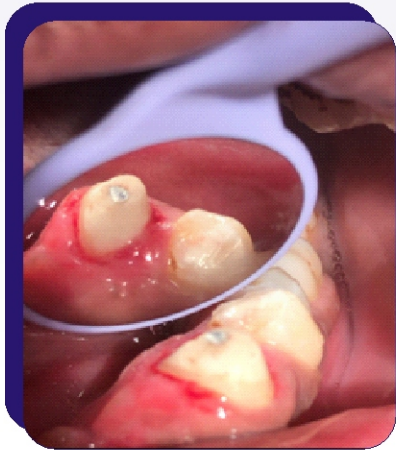Pre-operative Radiograph And Intra Oral Photograph

**OPG Reveals-** Two surgical miniplates evident which extends from right Para symphysis and symphysis to left Para symphysis and symphysis region. Missing tooth -11-14,21,22,32-42 Root Stumps -14,22,23.

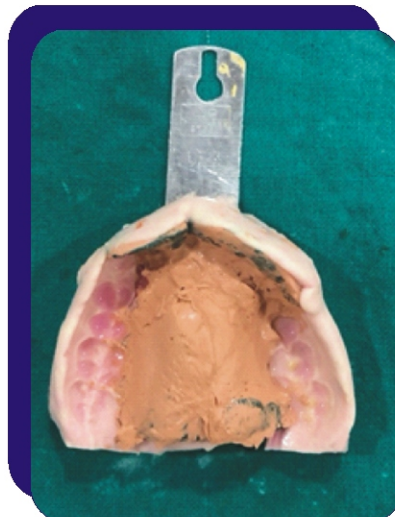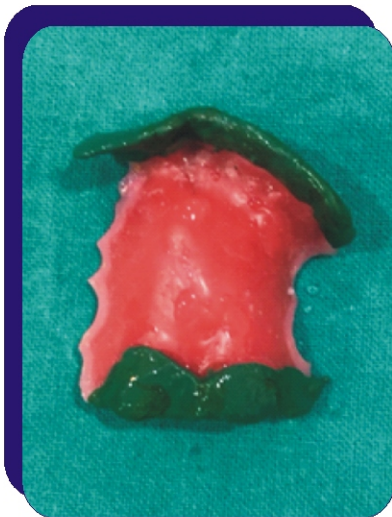
□ **Treatment Plan:** Intentional RCT-33,34,43 and FPD-33-43  
Flexible RPD -11-14,21,22,



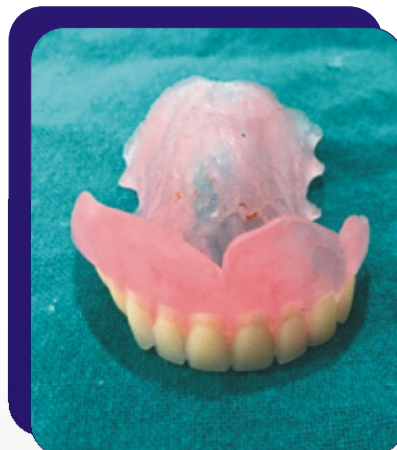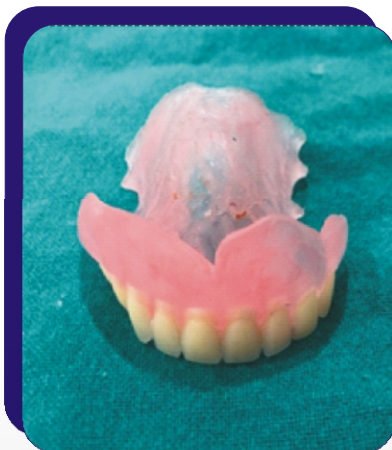Root Canal Procedure Done



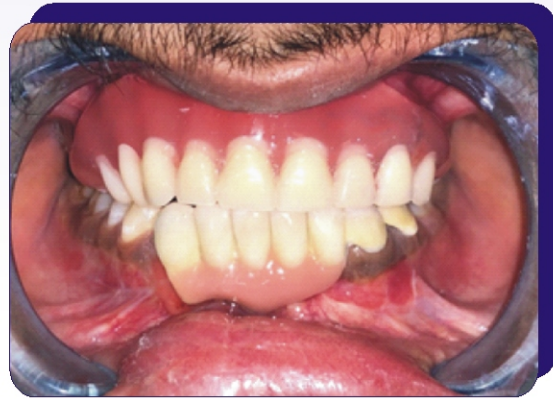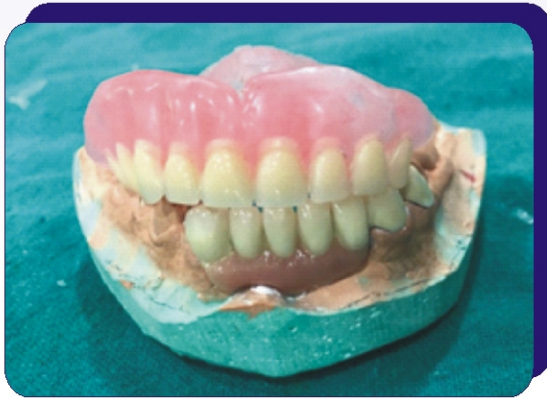Tooth Preparation Done -33,34,43



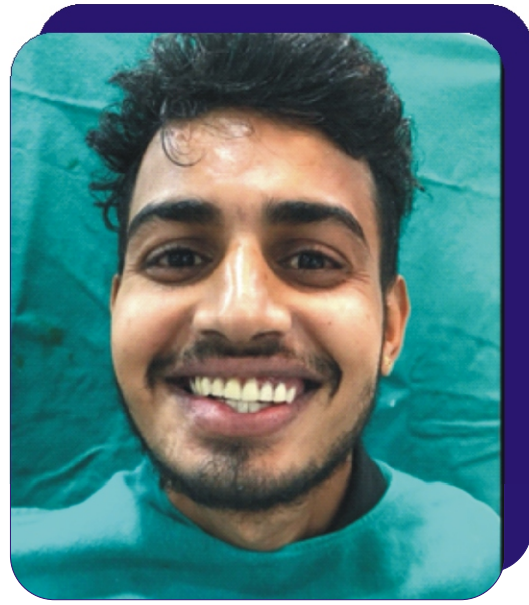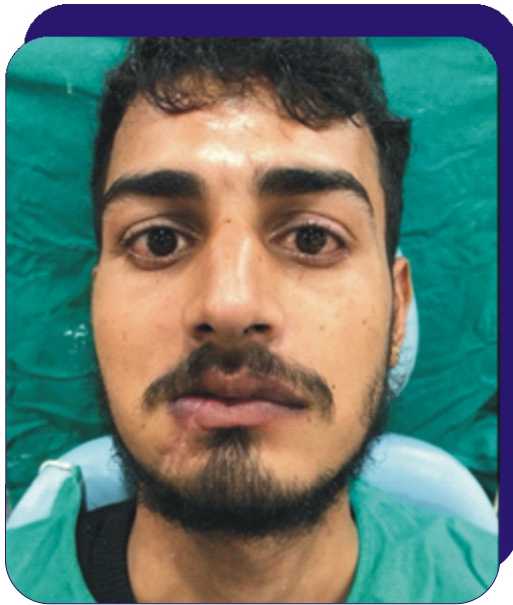Fabrication of Maxillary Custom Tray & Border Moulding



Flexible Removable Partial Denture Fabricated



Post Operative Intraoral Photograph



Pre Op & Post Op Photograph of Patient