

## CASE REPORT

# The efficacy of certolizumab pegol in rheumatoid arthritis assessed by gray scale and power Doppler ultrasonography: case reports

José Alexandre Mendonça PhD<sup>1</sup>, Guilherme B Damian MD<sup>2</sup>

<sup>1</sup>Pontifícia Universidade de Campinas, PUCAMP, Campinas, São Paulo, Brazil; <sup>2</sup>Medical Department, UCB Biopharma S.A., São Paulo, Brazil

**Keywords:** certolizumab pegol, Doppler ultrasound, gray scale ultrasound, rheumatoid arthritis.

### Citation

Mendonça JA, Damian G. The efficacy of certolizumab pegol in rheumatoid arthritis assessed by gray scale and power Doppler ultrasonography: case reports. *Drugs in Context* 2019; 8: 212554. DOI: [10.7573/dic.212554](https://doi.org/10.7573/dic.212554)

## Introduction

Rheumatoid arthritis (RA) is a rapidly progressive disease for many patients. Persistent high disease activity leads to disability, comorbidities, and premature mortality. Consequently, development of treatment strategies to bring the disease under control rapidly is of utmost importance. Close monitoring of disease activity and rapid interventions with synthetic disease-modifying antirheumatic drugs (DMARDs)<sup>1</sup> or combination therapy<sup>2-4</sup> showed improved long-term clinical outcomes (at 1–2 years) in patients with RA.

A key inflammatory pathway in RA includes overproduction and overexpression of tumor necrosis factor (TNF)- $\alpha$ , which are related to synovial inflammation and joint destruction. Anti-TNF- $\alpha$  agents were the first licensed biological drugs for RA treatment.<sup>5</sup>

In this respect, TNF- $\alpha$  inhibitors that rapidly improve clinical signs and symptoms<sup>6-9</sup> and health-related quality of life,<sup>8,10-12</sup> and inhibit structural damage,<sup>8-10,13</sup> have been an important addition to treatment options for patients with RA.

Certolizumab pegol is a PEGylated, humanized, antigen-binding fragment (Fab') of an anti-TNF- $\alpha$  monoclonal antibody.<sup>14,15</sup> Its lack of a crystallized fragment (Fc) region minimizes potential Fc-mediated effects, while the addition of a polyethylene glycol (PEG) moiety improves the pharmacokinetics and bioavailability of certolizumab.<sup>14</sup> Moreover, the pharmacodynamic properties of certolizumab are different from those of other anti-TNF- $\alpha$  agents.<sup>15</sup>

Ultrasonography has become an important tool for the diagnosis and monitoring of RA. The morphology and

extent of synovitis in RA joints can be assessed using gray scale (GS) ultrasound, with color Doppler or power Doppler (PD) ultrasound used to assess synovial vascularity.<sup>16-18</sup> Standardization and validation of the modality in rheumatology has been addressed by the Outcome Measures in Rheumatology (OMERACT) ultrasound working group.<sup>19</sup> Spectral Doppler ultrasonography can be used to determine the type of blood flow associated with inflammatory lesions in RA.<sup>18</sup>

The series of case reports reported herein demonstrates the efficacy of certolizumab pegol in patients with RA using GS and PD ultrasonography to monitor disease progression. The study also clearly demonstrates the importance of rapid and sustained control of disease activity to prevent irreversible damage and loss of joint function.

## Methods

Approval for the study was obtained from the review board of the PUC-Campinas Ambulatory Rheumatology Center, Sao Paulo, Brazil. Written consent was obtained from patients to perform the ultrasound exam and clinical assessment. Two patients were eligible for certolizumab pegol administration, which was administered following local Brazilian guidelines<sup>20</sup>: a loading dose of 400 mg at weeks 0, 2, and 4 by subcutaneous injection, followed by 400 mg every 4 weeks.

Ultrasound was performed using MyLab equipment (Esaote S.p.A., São Paulo, Brazil) with a high frequency (18 MHz) GS probe in the symptomatic joints. All imaging tests were performed using GS and PD techniques to detect morpho-structural changes and the presence of abnormal

blood flow, respectively. The PD settings were standardized with a color mode frequency ranging from 8.0 to 12.5 MHz and a pulse repetition frequency between 0.7 and 1.0 kHz. B-mode software was used to create color histograms that allow a better view of echotextural damage.<sup>21</sup> Spectral Doppler ultrasound was employed to confirm that the PD signal represented true hemodynamic phenomena (blood flow).

GS ultrasonography was used to assess the grade of synovitis on a scale of 0–3,<sup>22</sup> with synovial inflammatory activity scores assessed as follows: 0 (absent), that is, no joint capsule distension; 1 (mild), slight hypoechoic or anechoic image in the joint capsule; 2 (moderate), joint capsule elevation; and 3 (severe), important joint capsule distension. PD was characterized as 0 (absent), with no PD signal, that is, no intra-articular flow; 1 (mild), with 1 PD signal; 2 (moderate), with 2 or 3 PD signals, that is, an intra-articular flow of <50%; and 3 (severe), that is, an intra-articular flow of >50%.<sup>22</sup>

## Results

### Case 1

This case describes a 73-year-old retired woman, who had her first rheumatology appointment in September 2012 (baseline assessment). She had a history of hypertension and dyslipidemia, with polyarthritis manifesting around 10 years previously, involving hands, knees, and ankles. Concomitant medications were hydroxychloroquine 400 mg/day, captopril 25 mg/day, and simvastatin 20 mg/day. In addition, she was treated with prednisone 5 mg/day, 45 days before baseline assessment.

The patient had arthritis involving multiple joints: thickening and edema of the second and third bilateral metacarpophalangeal joints, arthralgia in all proximal interphalangeal joints, functional blockage of hand movement with arthritis, and edema and bilateral functional blockage of ankle movement with arthritis.

A hand X-ray showed juxta-articular osteopenia, narrowing of the symmetric space of proximal interphalangeal joints presenting erosions, and narrowing of the radiocarpal space presenting as erosions.

Laboratory test results are summarized in Table 1. The patient was rheumatoid factor (RF)-positive (188 IU/mL) and, consequently, a putative diagnosis of RA was proposed. The erythrocyte sedimentation rate (ESR) was >120 mm/hour, and the C-reactive protein (CRP) concentration was 114.2 mg/L.

The patient was prescribed methotrexate (MTX) 15 mg/day, hydroxychloroquine 400 mg/day, folic acid 5 mg/week, calcium carbonate 500 mg twice daily, and vitamin D 400 IU twice daily.

In May 2013, the patient reported a self-assessed partial improvement of joint pain and swelling. Examination showed hand arthralgia with blockage without arthritis. Laboratory tests showed an ESR of 103 mm/hour and CRP of 1.15 mg/dL. Leflunomide 20 mg/day was added to DMARD therapy.

The patient showed intolerance to leflunomide with nausea and vomiting and, in August 2013, leflunomide treatment was withdrawn. High liver enzymes (AST and ALT; Table 1) indicated hepatotoxicity. MTX treatment was suspended for 1 year. ESR (21 mm/hour) and CRP (0.13 mg/dL) were reduced to within the normal range.

In September 2014, the patient was unable to walk, and reported arthralgia in both hands. Examination showed left hand arthritis and fifth left metacarpophalangeal joint arthritis. ESR was 70 mm/hour, and CRP was 0.83 mg/dL. The patient received hydroxychloroquine 400 mg/day, prednisone 5 mg/day, captopril 25 mg twice daily, and simvastatin 20 mg/day. Due to leflunomide intolerance and MTX hepatotoxicity, the patient was elected for anti-TNF- $\alpha$  screening.

In September 2015, the patient had arthritis in both hands and left elbow, with the second, third, and fourth metacarpal bones having a swan neck deformity. At this stage, ESR was 90 mm/hour and CRP 2.37 mg/dL (Table 1). The patient had yet to perform screening tests for anti-TNF- $\alpha$  therapy and was being treated with prednisone 10 mg/day, hydroxychloroquine 400 mg/day, and sulfasalazine 500 mg twice daily.

In February 2016, the patient had arthritis in the left elbow, fifth right metacarpophalangeal joint and third, fourth, and fifth left metacarpophalangeal joints. The 28-joint disease activity score (DAS28) was 6.01. The patient was receiving prednisone 10 mg/day, hydroxychloroquine 400 mg/day, and sulfasalazine 500 mg twice daily. She was prescribed certolizumab pegol (as per schedule).

In September 2016, following 3 months' therapy with certolizumab pegol added on to prednisone 10 mg/day, hydroxychloroquine 400 mg/day, and sulfasalazine 1 g/day, the patient described a 100% improvement in joint pain and swelling. Laboratory tests were not available at this visit.

In December 2016, there were no joint complaints, with no swollen or tender joints. DAS28 was reduced to 2.65, and the ESR was 44 mm/hour. Articular ultrasound images showed control of articular inflammation. Figure 1 shows GS ultrasound images of the alleviation of metacarpophalangeal synovitis post certolizumab pegol, with improvement of effusion-synovitis from GS3 to GS0 in the left second metacarpophalangeal joint. In the right second metacarpophalangeal joint, effusion-synovitis showed improvement in both GS and histogram analyses (GS2–GS0). PD ultrasound showed an improvement from PD2 to PD0. Figure 2 shows spectral Doppler images of the right hand pre and post certolizumab pegol, with improvement in the right wrist resistance index (RI) from 0.53 to 0.78. The right wrist also showed improvement in synovitis in the GS (from 1 to 0), which had remained at grade 1 prior to certolizumab pegol treatment. Sulfasalazine treatment was withdrawn.

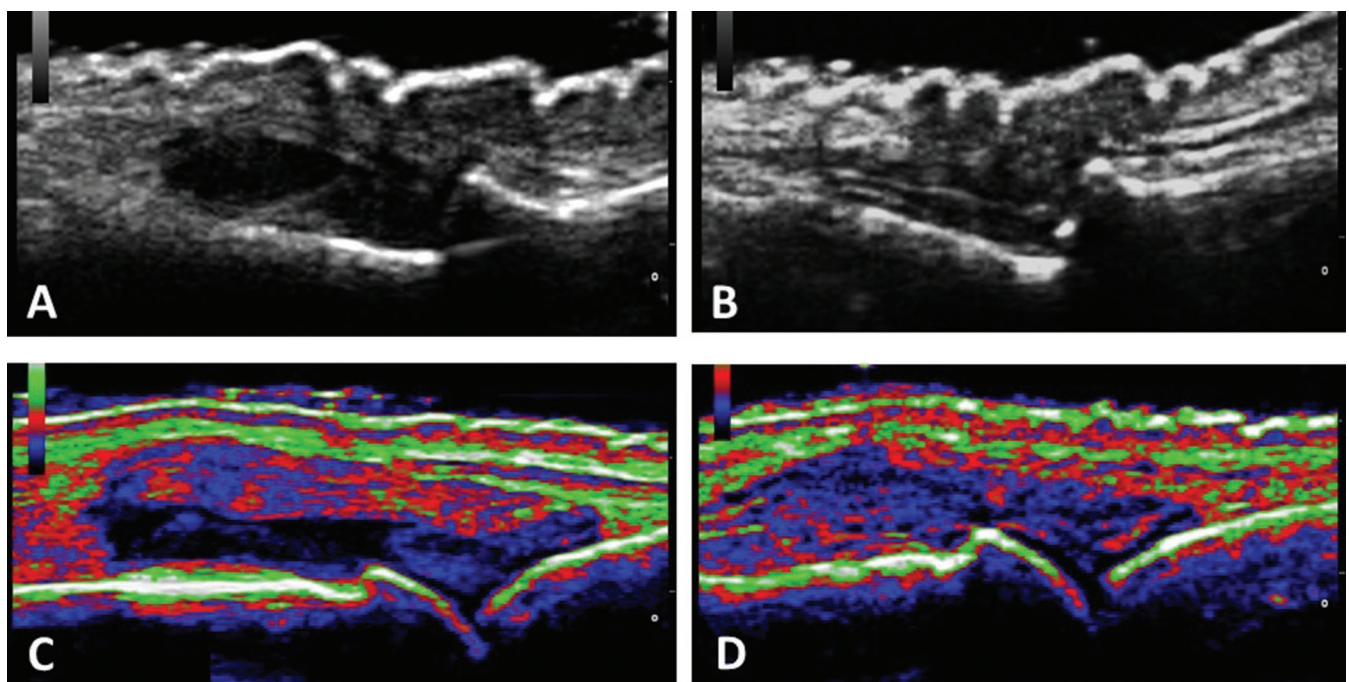
In March 2017, there were no joint complaints, with no swollen or tender joints. DAS 28 (2.16) and ESR (23 mm/hour) were reduced.

**Table 1. Laboratory parameters for Case 1.**

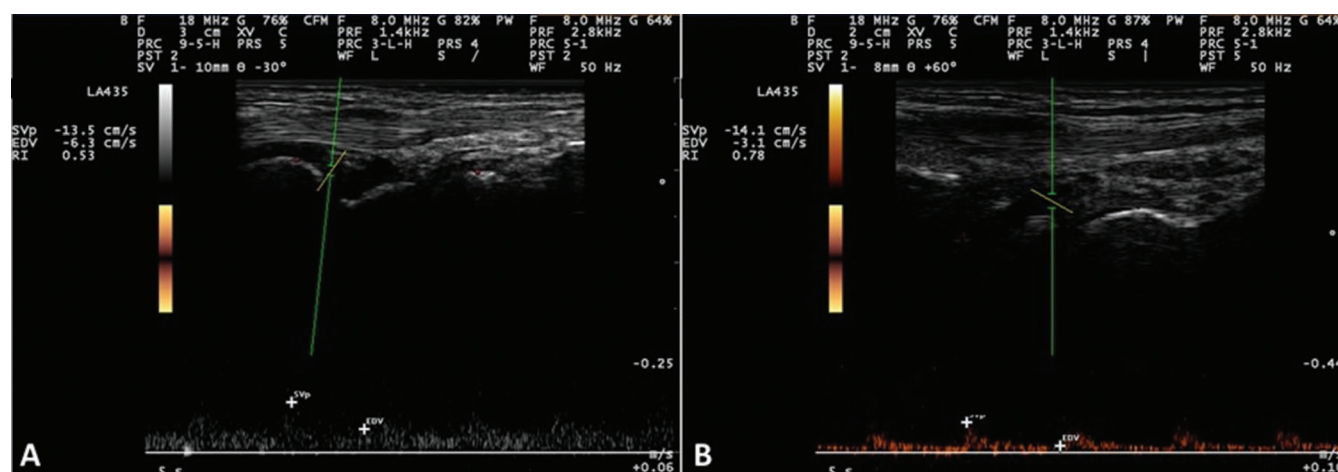
Parameter	Sep 2012	May 2013	Aug 2013	Sep 2014	Sep 2015	Dec 2016	Mar 2017
Rheumatoid factor (IU/mL)	188	ND	ND	ND	ND	ND	ND
C-reactive protein (CRP) (mg/L)	114.2	1.15	0.13	0.83	2.37	ND	ND
Erythrocyte sedimentation rate (ESR) (mm/hour)	>120	103	21	70	90	44	23
Aspartate aminotransferase (AST) (U/L)	32	43	82	ND	17	ND	ND
Alanine aminotransferase (ALT) (U/L)	28	34	117	ND	15	ND	ND
Alkaline phosphatase (U/L)	ND	69	ND	ND	ND	ND	ND
$\gamma$ -Glutamyltransferase (GGT) (U/L)	ND	37	ND	ND	ND	ND	ND
Creatinine (mg/dL)	0.86	0.67	ND	ND	0.77	ND	ND
Urea (mmol/L)	19	ND	ND	ND	44	ND	ND
Hemoglobin (g/dL)	11.5	11	ND	ND	11.8	ND	ND
Hematocrit (%)	34.8	34.8	ND	ND	36	ND	ND
Leukocytes (/ $\mu$ L)	6900	7500	ND	ND	5820	ND	ND
Platelets (/ $\mu$ L)	262,000	436,000	ND	ND	328,000	ND	ND

ND, not done.

**Figure 1.** A/B: Gray scale (GS) ultrasound images showing alleviation of metacarpophalangeal synovitis in Case 1 with certolizumab pegol: (A) Pre treatment (Day 0): GS3; (B) Post certolizumab pegol treatment (Day 90): GS0. C/D: Ultrasound B-mode color map images showing alleviation of metacarpophalangeal synovitis in Case 2 post certolizumab pegol: (C) Pre treatment (Day 0): GS2; (D) Post certolizumab pegol treatment (Day 90): GS0.



**Figure 2. Spectral Doppler images of the right hand in Case 1, pre and post certolizumab pegol: (A) Pre treatment (Day 0) with resistance index (RI) = 0.53; (B) Post certolizumab pegol treatment (Day 90) with RI = 0.78.**



## Case 2

This case describes a 63-year-old homemaker who presented in August 2014 with symmetric polyarthritis of hands, knees, and elbows. She was RF-negative and had an anti-cyclic citrullinated peptide (anti-CCP) level of 340 UI/mL, with an ESR of 101 mm/hour and CRP of 27.7 mg/L. The preliminary diagnosis was RA and she was prescribed MTX 12.5 mg/week, hydroxychloroquine 400 mg/day folic acid 5 mg/week, and prednisone 5 mg twice daily.

In November 2014, the patient had arthritis and articular effusion in her right knee, arthritis in her right elbow and right hand, and arthralgia in all metacarpophalangeal and interphalangeal joints. ESR was 65 mm/hour and CRP 57 mg/L. MTX was increased to 17.5 mg/week.

In July 2015, the patient reported pain persistence in the proximal metacarpophalangeal and interphalangeal joints. Examination showed arthritis in the second and third bilateral metacarpophalangeal joints and elbows and arthritis and articular effusion in the right knee. DAS28 was 5.8 with an ESR of 112 mm/hour and CRP 17 mg/L. Leflunomide 20 mg/day was added to DMARD therapy.

In March 2016, no arthritis was present but the patient still presented with an articular effusion in her right knee. ESR was 30 mm/hour and CRP 2.3 mg/dL. There was no change of medication.

The patient was subjected to articular ultrasound in June 2016, with active disease diagnosed (Figure 1, panel C). The patient was treated with certolizumab pegol (as per schedule) in combination with MTX 17.5 mg/week. Leflunomide was withdrawn.

In November 2016, no articular pain was reported by the patient, and there were no signs of arthritis or symptoms of arthralgia. Figure 1 shows B-mode color map ultrasound images

of the alleviation of metacarpophalangeal synovitis following 3 months of certolizumab pegol treatment. Ultrasound detected GS improvements, from GS2 to GS0, in the right wrist, right second and third metacarpophalangeal joints, and right third proximal interphalangeal joint (Figure 1, panels C and D).

DAS28 was reduced to 0.77, with reductions in ESR (3 mm/hour) and CRP (5.1 mg/L). Prednisone was reduced to 5 mg/day.

In November 2016, no arthritis or arthralgia was diagnosed, and the patient was pain-free. Prednisone was withdrawn.

## Discussion

Certolizumab pegol treatment for 12 weeks, in combination with other DMARDs, dramatically improved RA signs and symptoms in both cases. Due to intolerance to leflunomide and hepatotoxicity following MTX, certolizumab pegol was added on to prednisone, hydroxychloroquine, and sulfasalazine in Case 1. In Case 2, certolizumab pegol was used in combination with MTX, hydroxychloroquine, prednisone, and leflunomide.

Furthermore, improvement was assessed by ultrasound, and clinical and laboratory findings. In Case 1, GS ultrasound images showed improvement in synovitis in the left and right metacarpophalangeal joints, from GS2/3 to GS0, with PD ultrasound showing improvements in blood flow from PD2 to PD0. Spectral Doppler images showed improvement in the right wrist RI. These changes were accompanied by the absence of swollen or tender joints, and improvement of DAS28 and ESR values. In Case 2, GS ultrasound showed improvements, from GS2 to GS0, in the right wrist, and metacarpophalangeal and interphalangeal joints, with the absence of arthritis or arthralgia, and improvement in DAS28, ESR, and CRP.

These results are in line with those found in three pivotal phase 3 trials of RA patients with active disease, which showed that certolizumab pegol monotherapy or certolizumab pegol plus

MTX improved signs and symptoms.<sup>23</sup> Combination therapy with certolizumab pegol and MTX significantly inhibited the progression of radiographically assessed joint damage by Week 16.<sup>23</sup> A recent Cochrane review confirmed the beneficial effects of certolizumab pegol either as monotherapy or combined with MTX in adults with RA.<sup>24</sup>

In conclusion, this current case report highlights the improvement in joint health experienced by both patients

following certolizumab pegol treatment, which was monitored with ultrasound: B-mode histogram analysis showed the rapid suppression of articular effusion, with treatment producing inhibition of the PD test and improved spectral Doppler results. Importantly, to the best of our knowledge, this is the first report to show that this technique has been employed and published to reinforce the response achieved by these patients, and furthermore, ultrasound findings were correlated with clinical and laboratory improvements.

**Contributions:** All named authors meet the International Committee of Medical Journal Editors (ICMJE) criteria for authorship for this article, take responsibility for the integrity of the work as a whole, and have given their approval for this version to be published.

**Disclosure and potential conflicts of interest:** JA Mendonça declares no conflicts of interest. G Damian is a full-time employee of UCB, Biopharma S.A., São Paulo, Brazil. The International Committee of Medical Journal Editors (ICMJE) Potential Conflicts of Interests form for the authors are available for download at <http://www.drugsincontext.com/wp-content/uploads/2019/12/dic.212554-COI.pdf>

**Acknowledgments:** Writing assistance was provided to the authors by Robert A Furlong PhD and David P Figgitt PhD, ISMPP CMPP™, Content Ed Net.

**Funding declaration:** Editorial assistance was provided by Content Ed Net (Brazil) with funding from UCB Biopharma S.A., São Paulo, Brazil. There was no other funding associated with the preparation of this article.

**Copyright:** Copyright © 2019 Mendonça JA, Damian G. Published by Drugs in Context under Creative Commons License Deed CC BY NC ND 4.0, which allows anyone to copy, distribute, and transmit the article provided it is properly attributed in the manner specified below. No commercial use without permission.

**Correct attribution:** Copyright © 2019 Mendonça JA, Damian G. <https://doi.org/10.7573/dic.212554>. Published by Drugs in Context under Creative Commons License Deed CC BY NC ND 4.0.

**Article URL:** <https://www.drugsincontext.com/the-efficacy-of-certolizumab-pegol-in-rheumatoid-arthritis-assessed-by-gray-scale-and-power-doppler-ultrasonography:-case-reports>

**Correspondence:** José Alexandre Mendonça, Pontifícia Universidade de Campinas, PUCCAMP, Campinas, São Paulo, Brazil. [mendoncaja.us@gmail.com](mailto:mendoncaja.us@gmail.com)

**Provenance:** submitted; externally peer reviewed.

**Submitted:** 28 August 2018; **Peer review comments to author:** 17 October 2018; **Revised manuscript received:** 11 December 2018; **Accepted:** 12 December 2018; **Publication date:** 13 February 2019.

**Drugs in Context** is published by BioExcel Publishing Ltd. Registered office: Plaza Building, Lee High Road, London, England, SE13 5PT. BioExcel Publishing Limited is registered in England Number 10038393. VAT GB 252 7720 07.

For all manuscript and submissions enquiries, contact the Editor-in-Chief [gordon.mallarkey@bioexcelpublishing.com](mailto:gordon.mallarkey@bioexcelpublishing.com)

For all permissions, rights and reprints, contact David Hughes [david.hughes@bioexcelpublishing.com](mailto:david.hughes@bioexcelpublishing.com)

## References

1. Grigor C, Capell H, Stirling A, et al. Effect of a treatment strategy of tight control for rheumatoid arthritis (the TICORA study): a single-blind randomised controlled trial. *Lancet*. 2004;364:263–269. [https://doi.org/10.1016/S0140-6736\(04\)16676-2](https://doi.org/10.1016/S0140-6736(04)16676-2)
2. Goekoop-Ruiterman YP, de Vries-Bouwstra JK, Allaart CF, et al. Clinical and radiographic outcomes of four different treatment strategies in patients with early rheumatoid arthritis (the BeSt study): a randomized, controlled trial. *Arthritis Rheum*. 2005;52:3381–3390. <https://doi.org/10.1002/art.21405>
3. Verstappen SM, Jacobs JW, van der Veen MJ, et al; Utrecht Rheumatoid Arthritis Cohort study group. Intensive treatment with methotrexate in early rheumatoid arthritis: aiming for remission. Computer Assisted Management in Early Rheumatoid Arthritis (CAMERA, an open-label strategy trial). *Ann Rheum Dis*. 2007;66:1443–1449. <https://doi.org/10.1136/ard.2007.071092>
4. Soubrier M, Puéchal X, Sibilia J, et al. Evaluation of two strategies (initial methotrexate monotherapy vs its combination with adalimumab) in management of early active rheumatoid arthritis: data from the GUEPARD trial. *Rheumatology (Oxford)*. 2009;48:1429–1434. <https://doi.org/10.1093/rheumatology/kep261>
5. Levy RA, Guzman R, Castañeda-Hernández G, Martínez-Vázquez M, Damian G, Cara C. Biology of anti-TNF agents in immune-mediated inflammatory diseases: therapeutic implications. *Immunotherapy*. 2016;8:1427–1436. <https://doi.org/10.2217/imt-2016-0067>

6. Moreland LW, Schiff MH, Baumgartner SW, et al. Etanercept therapy in rheumatoid arthritis. A randomized, controlled trial. *Ann Intern Med.* 1999;130:478–486. <https://doi.org/10.7326/0003-4819-130-6-199903160-00004>
7. Weinblatt ME, Keystone EC, Furst DE, et al. Adalimumab, a fully human anti-tumor necrosis factor alpha monoclonal antibody, for the treatment of rheumatoid arthritis in patients taking concomitant methotrexate: the ARMADA trial. *Arthritis Rheum.* 2003;48:35–45. <https://doi.org/10.1002/art.10697>
8. Maini RN, Breedveld FC, Kalden JR, et al; Anti-Tumor Necrosis Factor Trial in Rheumatoid Arthritis with Concomitant Therapy Study Group. Sustained improvement over two years in physical function, structural damage, and signs and symptoms among patients with rheumatoid arthritis treated with infliximab and methotrexate. *Arthritis Rheum.* 2004;50:1051–1065. <https://doi.org/10.1002/art.20159>
9. Keystone E, Heijde Dv, Mason D Jr, et al. Certolizumab pegol plus methotrexate is significantly more effective than placebo plus methotrexate in active rheumatoid arthritis: findings of a fifty-two-week, phase III, multicenter, randomized, double-blind, placebo-controlled, parallel-group study. *Arthritis Rheum.* 2008;58:3319–3329. <https://doi.org/10.1002/art.23964>
10. Keystone EC, Kavanaugh AF, Sharp JT, et al. Radiographic, clinical, and functional outcomes of treatment with adalimumab (a human anti-tumor necrosis factor monoclonal antibody) in patients with active rheumatoid arthritis receiving concomitant methotrexate therapy: a randomized, placebo-controlled, 52-week trial. *Arthritis Rheum.* 2004;50:1400–1411. <https://doi.org/10.1002/art.20217>
11. Strand V, Singh JA. Improved health-related quality of life with effective disease-modifying antirheumatic drugs: evidence from randomized controlled trials. *Am J Manag Care.* 2008;14:234–254. PubMed PMID: 18415967
12. Strand V, Keininger DL, Kavanaugh A. Certolizumab pegol (CZP) induces rapid and sustained clinically meaningful improvements in physical function and health-related quality of life (HRQOL) in patients with rheumatoid arthritis (RA): the RAPID 1 and 2 randomised clinical trials (RCTS). *Ann Rheum Dis.* 2008;67(Suppl II):331 (Abstract FRI0141).
13. Genovese MC, Bathon JM, Martin RW, et al. Etanercept versus methotrexate in patients with early rheumatoid arthritis: two-year radiographic and clinical outcomes. *Arthritis Rheum.* 2002;46:1443–1450. <https://doi.org/10.1002/art.10308>
14. Goel N, Stephens S. Certolizumab pegol. *MAbs.* 2010;2:137–147. PubMed PMID: 20190560
15. Pasut G. Pegylation of biological molecules and potential benefits: pharmacological properties of certolizumab pegol. *BioDrugs.* 2014;28 Suppl 1:S15–23. <https://doi.org/10.1007/s40259-013-0064-z>
16. Naredo E, Iagnocco A. One year in review: ultrasound in arthritis. *Clin Exp Rheumatol.* 2016;34:1–10. PubMed PMID: 26892798
17. Haavardsholm EA, Aga AB, Olsen IC, et al. Ultrasound in management of rheumatoid arthritis: ARCTIC randomised controlled strategy trial. *BMJ.* 2016;354:i4205. <https://doi.org/10.1136/bmj.i4205>
18. Carotti M, Salaffi F, Morbiducci J, et al. Colour Doppler ultrasonography evaluation of vascularization in the wrist and finger joints in rheumatoid arthritis patients and healthy subjects. *Eur J Radiol.* 2012;81:1834–1838. <https://doi.org/10.1016/j.ejrad.2010.01.005>
19. Bruyn GA, Naredo E, Iagnocco A, et al; OMERACT Ultrasound Task Force. The OMERACT Ultrasound Working Group 10 Years On: Update at OMERACT 12. *J Rheumatol.* 2015;42:2172–2176. <https://doi.org/10.3899/jrheum.141462>
20. Ministério da Saúde. CIMZIA® Certolizumabe pegol: identification of the medicinal product, 2018. [http://www.anvisa.gov.br/datavisa/fila\\_bula/frmResultado.asp#](http://www.anvisa.gov.br/datavisa/fila_bula/frmResultado.asp#). Accessed June 9, 2018.
21. Mendonça JA. Ultrasound color histogram assessment allows better view of echotexture damage. *Rev Bras Reumatol.* 2017;57:88–91. <https://doi.org/10.1016/j.rbr.2014.12.016>
22. Szkudlarek M, Narvestad E, Klarlund M, Court-Payen M, Thomsen HS, Østergaard M. Ultrasonography of the metatarsophalangeal joints in rheumatoid arthritis: comparison with magnetic resonance imaging, conventional radiography, and clinical examination. *Arthritis Rheum.* 2004;50:2103–2112. <https://doi.org/10.1002/art.20333>
23. Mease PJ. Certolizumab pegol in the treatment of rheumatoid arthritis: a comprehensive review of its clinical efficacy and safety. *Rheumatology (Oxford).* 2011;50(2):261–270. <https://doi.org/10.1093/rheumatology/keq285>
24. Ruiz Garcia V, Burls A, Cabello JB, Vela Casasempere P, Bort-Martí S, Bernal JA. Certolizumab pegol (CDP870) for rheumatoid arthritis in adults. *Cochrane Database Syst Rev.* 2017;9:CD007649. <https://doi.org/10.1002/14651858.CD007649.pub4>