

REVIEW

Dermatology: how to manage acne in skin of colour

Claire Chiang¹, Madison Ward², Melinda Gooderham^{2,3,4}

¹University of Edinburgh, Scotland Old College, South Bridge, Edinburgh, UK; ²SKiN Centre for Dermatology, Peterborough, ON, Canada; ³Probit Medical Research, Waterloo, ON, Canada; ⁴Queen's University, Kingston, ON, Canada

Abstract

Acne vulgaris is a prevalent dermatological condition worldwide but is especially challenging to treat in individuals with skin of colour (SOC). Corresponding to Fitzpatrick skin phototypes III–VI, people of African, Asian, Middle Eastern and Hispanic ethnicity are considered to have SOC. With the additional risk of postinflammatory hyperpigmentation (PIH) as a consequence of inflammatory acne or its respective treatment, managing acne in this population holds significant importance. PIH adversely impacts self-esteem and quality of life and, thus, is usually the patient's priority of treatment. Available acne treatments are similar for all skin types. However, some are more beneficial for individuals with SOC, in particular by targeting both active acne lesions and PIH. The acne treatment literature was searched for topical and systemic treatments that were specifically studied in the SOC population. These treatments included topical agents, such as retinoids and azelaic acid, in addition to topical antibiotics and benzoyl peroxide. Newer formulations and combined regimens reported effective in reducing lesions are less likely to induce PIH and may treat

pre-existing PIH. Moisturiser use, titrating doses and patient education are strategies to minimize irritation and improve adherence. In addition, systemic therapies, including oral antibiotics, isotretinoin, oral contraceptives and spironolactone, are efficacious for refractory acne or more severe cases but specific studies in SOC are lacking. Chemical peels may improve acne and target PIH directly. Overall, based on limited evidence, topical and systemic therapies are well tolerated in the SOC population but efficacy should be balanced with the risk of adverse effects. This narrative review aims to highlight formulations and combination therapies that are effective and safe for treating acne and PIH in patients with SOC.

Keywords: acne vulgaris, benzoyl peroxide, ethnic groups, oral contraceptives postinflammatory hyperpigmentation, retinoids, skin pigmentation, tetracyclines.

Citation

Chiang C, Ward M, Gooderham M. Dermatology: how to manage acne in skin of colour. *Drugs Context*. 2022;11:2021-10-9. <https://doi.org/10.7573/dic.2021-10-9>

Introduction

Acne vulgaris is a multifactorial disease of the pilosebaceous unit and a highly prevalent skin condition globally.^{1,2} It is one of the most common reasons, people with skin of colour (SOC) visit a dermatology office,³ and is the prevailing dermatological condition in Black patients.⁴ People of African, Asian, Middle Eastern and Hispanic descent are identified as having SOC and these ethnic backgrounds correlate with the Fitzpatrick skin phototypes (FST) III–VI.⁵ Although treating acne vulgaris in these populations involves targeting underlying pathological processes similar to all skin phototypes, the unique challenge is preventing or minimizing the increased risk of postinflammatory hyperpigmentation (PIH). Characterized by areas of more deeply pigmented skin, PIH can arise after inflammatory acne itself or its treatments, which cause cutaneous irritation. Higher prevalence,

greater severity and a longer duration of PIH are reported in individuals with SOC compared to FST I–III.^{6,7} It is hypothesized that the increased risk of PIH may be due to prominent melanocyte lability.⁶ Other skin morphology differences between skin types may explain this disparity as well, including increased pore size and sebum production in people with SOC.⁶ However, there is a gap in fully understanding these differences, which needs to be addressed with further research.

The impact of PIH is often more significant to the patient than the acne itself due to detrimental impacts on quality of life, anxiety and self-esteem.^{6,7} The discoloration from old acne lesions can last significantly longer than the original acne lesions themselves. It has been reported that epidermal PIH may last up to 6–12 months, whilst dermal PIH can contrastingly last for years. It is also reported that

those with SOC are approximately 5–16 times more likely to develop keloid scar tissue compared to Caucasian skin.⁶ Disparities in the treatment of acne in patients with SOC can add an additional burden to the disease.⁸ Less frequent visits to dermatologists and acne prescribing are reported in Black patients.⁴ Thus, identifying therapies that are efficacious, tolerable and accessible are particularly important for acne management in patients with SOC. Although the treatment options for acne are similar for all skin types, some treatments have the additional benefit of actively reducing PIH and/or have a minimal risk of inducing PIH. These treatment selections will be explored in this narrative review.

Methods

Medline/PubMed searches were performed to identify the relevant literature for topical therapies, systemic therapies and procedural therapies used to treat acne vulgaris in patients with SOC. Primary studies were included if they discussed either treatment efficacy, tolerability or safety profile in a SOC population with acne vulgaris. Other studies identified through reading relevant literature were also included. The treatment algorithm incorporating these therapies for mild-to-severe acne vulgaris in patients with SOC is summarized in Figure 1.

Discussion

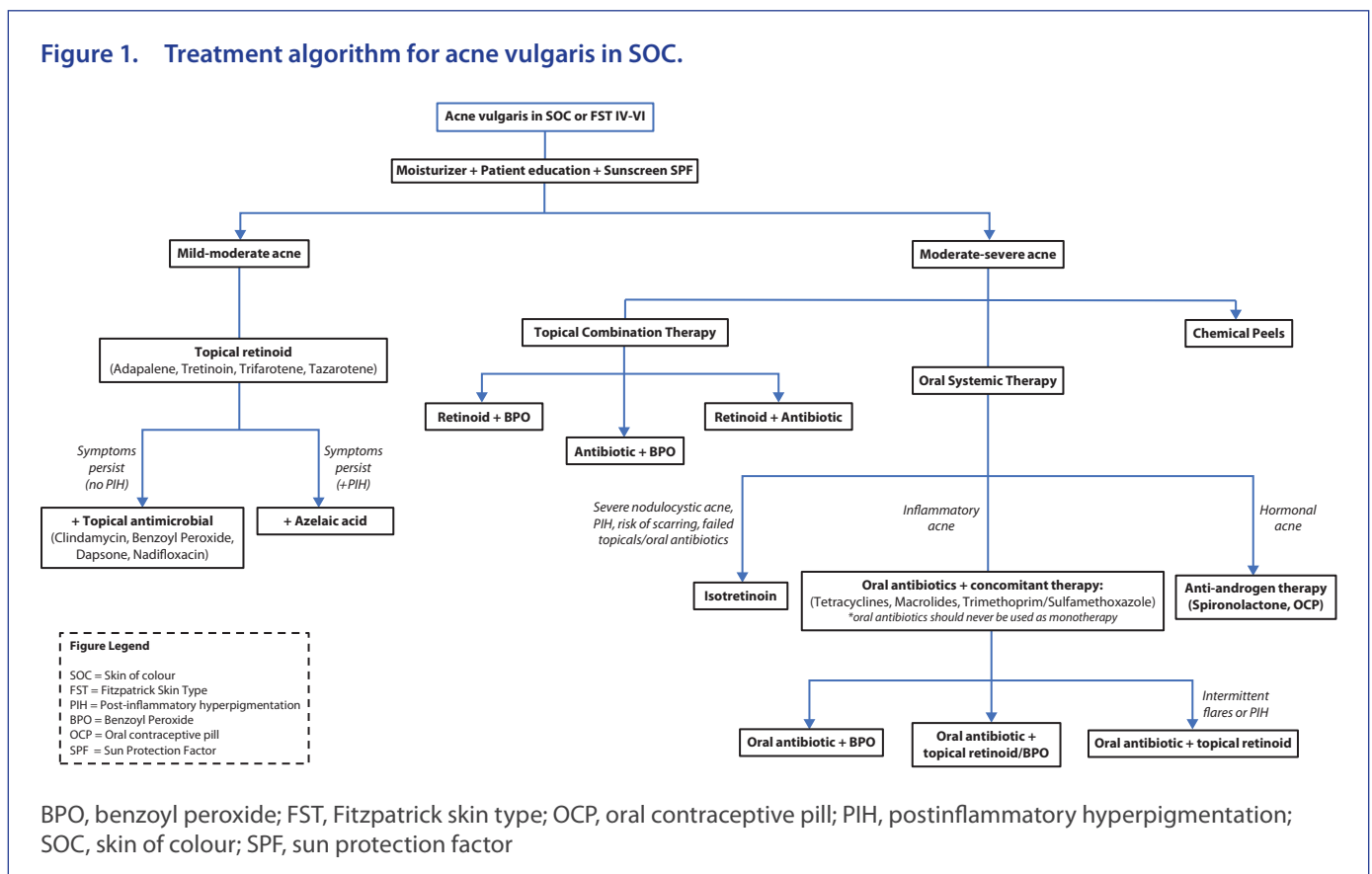
Topical therapies

When treating all skin phototypes, topical therapies are appropriate as first-line monotherapy for mild-to-moderate acne and as an adjunct for severe acne.⁷ In addition, patients should be counselled on skincare practices, including gentle cleansing and regular skin barrier control with non-comedogenic moisturizers. When treating patients with SOC, patients should also be reminded to incorporate daily sunscreen and reduce sun exposure to prevent further pigment darkening.

Topical retinoids

Retinoids, derived from vitamin A, are an important group of drugs for treating acne. They are effective against both non-inflammatory comedogenic and inflammatory lesions by reducing hyperkeratinization at the cellular level and inhibiting inflammatory mediators. By suppressing tyrosine kinases and pathophysiological processes of hyperpigmentation (including dermal and epidermal melanosis), retinoids have the added benefit of treating coexisting PIH. Thus, these multimodal effects make retinoids an important first-line treatment for mild-to-moderate acne in patients with SOC. However, retinoids are also known for their potential irritation and must be prescribed with adequate education on proper use.

Figure 1. Treatment algorithm for acne vulgaris in SOC.



The risk of retinoid dermatitis must be considered in individuals with SOC especially, as the irritation may lead to further PIH. Therefore, proper skincare to maintain the skin barrier should be discussed.⁶

Retinoids have demonstrated comparable high efficacy in patients with SOC and Caucasian patients. A novel formulation of a 0.05% tretinoin lotion improved baseline hyperpigmentation in Blacks,⁴ Hispanics⁹ and Asians.¹⁰ Hyperpigmentation was neither exacerbated nor induced by irritation from the treatment itself.^{9,10} Treatment-related hypopigmentation was also not observed.^{4,9} In the Asian population study, it reduced both inflammatory and non-inflammatory lesions in subjects with moderate-to-severe acne.¹⁰ Adapalene gel 0.1% also significantly reduced inflammatory lesions in Asians,¹¹ and both inflammatory and non-inflammatory lesions in Blacks.¹² Adapalene gel 0.1% cleared significantly more inflammatory lesions in Black patients compared to Caucasians in a 2002 meta-analysis.¹³ Similarly, hyperpigmentation improved with therapy and was not reported as a treatment-side effect.¹²

Although adverse effects (AEs) were still reported, some studies found newer formulations of retinoids to be better tolerated in all skin types, particularly in individuals with SOC.^{4,9–14} In a group of healthy volunteers of various ethnicities, adapalene gel 0.1% was more tolerable than 0.025% tretinoin gel.¹⁴ Treatment-related irritation, including erythema and skin dryness, was present in Asian¹¹ and Black skin^{12,13} following adapalene gel 0.1% application but was generally well tolerated. Interestingly, overall tolerability was greater in Black than in White patients.¹³ The novel 0.05% tretinoin lotion previously described was well tolerated and safe in Black patients,⁴ Hispanics⁹ and Asians.¹⁰ One study found no treatment-related AEs,¹⁰ whilst others found mild-to-moderate treatment-related AEs.^{4,9} The most common AEs were application site pain, erythema, pruritus and dryness.^{4,9} Scaling decreased in Blacks⁴ whilst it transiently increased in Asians.¹⁰ Likewise, this tretinoin 0.05% lotion was better tolerated in Hispanic subjects compared to non-Hispanics.⁹

Overall, newer formulations of topical retinoids have been shown to be efficacious and safe in patients with SOC with lower risks of hyperpigmentation or hypopigmentation. These are important features of a product as the minimal inflammatory reactions will improve adherence and reduce the risk of PIH from therapy.

Topical antibiotics

Topical antibiotics prevent colonization by causative pathogens, including *Cutibacterium acnes*, but carry an increased risk of resistance compared to oral antibiotics. They are not recommended to be used as monotherapy and are typically used in combination with benzoyl peroxide (BPO), topical retinoids or azelaic acid (AzA), perhaps as a second-line therapy. Nadifloxacin, a topical fluoroquinolone, has been

approved in some regions of the world, including Europe and Asia, for use in mild-to-moderate acne. It has been shown that topical nadifloxacin, in combination with other acne therapies (adapalene, BPO and AzA) was well tolerated by subjects without increased irritant reactions.¹⁵ Application of 1% nadifloxacin cream reduced the severity of inflammatory lesions, non-inflammatory lesions and acne severity as early as 2 weeks in Korean patients with acne.¹⁶ No serious AEs were reported following 1% nadifloxacin cream, only transient mild erythema and dryness.¹⁶ Clindamycin, another topical antibiotic, is very effective in acne management but is not used as monotherapy and will be discussed later in combination therapy.¹⁷

Dapsone

Dapsone is a sulfone with dual antimicrobial and anti-inflammatory activity. Dapsone 5% gel was studied in 68 women with SOC with twice daily application over 12 weeks. It was found to be safe and effective for the treatment of both inflammatory and non-inflammatory lesions without tolerability issues.¹⁸ A post hoc analysis from two pooled phase III studies of dapsone 7.5% gel applied once daily in moderate acne for 12 weeks did not show any efficacy difference with respect to FST. In this analysis, almost 50% of study participants had FST IV–VI. Improvement of inflammatory, non-inflammatory and total lesions were the same in this group compared to those with phototypes I–III, along with similar tolerability.¹⁹

One concern about dapsone is the risk of haemolytic anaemia in those with glucose-6-phosphate dehydrogenase (G6PD) deficiency, which is more common in patients with SOC, particularly males. A study was conducted using topical dapsone 5% gel twice daily in patients with known G6PD deficiency and acne vulgaris; 64 patients with SOC were enrolled and treated for 12 weeks in a cross-over design, receiving dapsone gel or vehicle. Over the 28-week study period, no clinical or laboratory evidence of haemolytic anaemia was noted and the authors concluded dapsone was a safe treatment for all patients, including those with SOC and G6PD deficiency.²⁰

Benzoyl peroxide

The effects of BPO on acne pathogenesis are also multimodal. It has antiseptic/antimicrobial and anti-inflammatory actions. Additionally, its keratolytic and comedolytic properties are beneficial for the treatment of non-inflammatory lesions. Unlike topical antibiotics, bacterial resistance is less likely.

In a study on Japanese patients, total, non-inflammatory and inflammatory lesions were significantly reduced by week 4 using BPO 3% topical gel.²¹ This efficacy in reducing lesion count in Japanese patients was also comparable to a White population.²² Transient AEs, including facial pain, pruritus, dry skin and erythema, were reported after BPO 3% topical gel application.²¹ When comparing the safety profile in Japanese

to Caucasian patients, there were fewer AEs reported from the latter but similar types of AEs were experienced, primarily skin irritation.²²

Azelaic acid

AzA is an important agent in the management of patients with SOC because it can target both acne and PIH simultaneously due to its anti-inflammatory and antiseptic properties, and antikeratolytic and antityrosinase properties, respectively.

By week 4, AzA gel 15% significantly reduced total and inflammatory acne lesion counts in patients with FST IV.²³ Additionally, marked improvement of both PIH distribution and severity was reported in Japanese patients with mild-to-moderate acne.²³ Two-thirds of patients were PIH-free and there was a 98% reduction in total lesion count at the end of 16 weeks. Thus, coexisting acne and PIH were improving at an early time point of 4 weeks and continued to improve until week 16.²³ At the end of the trial period, erythema and dryness were no longer reported, neither were serious AEs, highlighting the good tolerability in this population.²³

Combination therapies

By targeting multiple pathogenic processes underlying acne pathogenesis, combination therapies may have synergistic effects that better treat acne and PIH compared to monotherapy with any agent.

Combined retinoid and BPO

In a 12-week study, adapalene 0.1%–BPO 2.5% gel significantly reduced total, inflammatory and non-inflammatory lesions as early as 1 week in a subgroup analysis of Black patients. Additionally, PIH was not reported as a side effect.²⁴ This same combination gel reduced inflammatory and non-inflammatory lesions in Korean patients more than adapalene alone, highlighting the additional benefit of BPO.²⁵ Although increased AEs were noted in the combination therapy group, these were transient and tolerable.²⁵ This formulation was also compared to the application of BPO 2.5% alone and the combination group had superior efficacy for inflammatory and non-inflammatory lesions at earlier time points. Local irritation was increased, however, but declined with ongoing therapy.²⁶ A more potent formulation with adapalene 0.3%–BPO 2.5% gel also reduced acne severity and degree of PIH in FST IV–VI.²⁷ Adapalene–BPO combination gels were generally well tolerated with proper patient counselling.^{24,27}

Combined antibiotic and BPO

Three studies demonstrated the efficacy of clindamycin phosphate 1.2%–BPO 2.5% gel in reducing inflammatory, non-inflammatory and total lesion counts of severe acne in patients with SOC.^{28–30} This combination was safe in patients with SOC with minimal irritation.^{28–30} Callender found increased erythema in FST I–III compared to FST IV–VI, though this may

be attributed to difficult visualization of erythema in deeply pigmented skin.³⁰ Another formulation of clindamycin 1%–BPO 5% gel was compared to 0.1% adapalene monotherapy. The combined treatment group demonstrated greater efficacy in reducing lesions, especially inflammatory lesions. Surprisingly, the combined group had better tolerability than adapalene alone. AEs included transient erythema and dry skin.³¹

Combined antibiotic and retinoids

Combination therapy with retinoids has previously been shown to effectively improve hyperpigmentation in patients with SOC by Taylor in 2007.³² A clindamycin phosphate 1.2% and tretinoin 0.025% aqueous-based gel is available, and it was shown to be more effective treating acne than vehicle alone in a randomized controlled trial.³³ A pilot study in patients with SOC compared this combination gel to vehicle specifically in 33 participants with FST IV–VI. Although the study was insufficiently powered to demonstrate statistical significance, there was a numerical trend to lesion reduction and improvement in acne severity compared to vehicle. Existing PIH was not worsened with the combination gel, and PIH improved more in the treatment group compared to vehicle.³⁴

Adjunctive therapies and strategies

Moisturizers

Chularojanamontri et al.¹¹ compared the efficacy of adapalene gel 0.1% alone to a combination of adapalene gel with an anti-inflammatory moisturizer (containing licochalcone A, L-carnitine and 1,2-decanediol). Highest rates of inflammatory and total lesion reduction occurred in the combination group, with an earlier onset at 2 weeks. Additionally, symptoms of erythema, dryness, scaling, stinging/burning and pruritus were lowest in the combination group.¹¹ Similarly, Kulthanan et al. found the use of a moisturizer (containing licochalcone A, decanediol, L-carnitine and salicylic acid) after topical treatment maintained the clinical response with the benefit of reducing irritation and thus had the potential to prevent acne relapse.³⁵ In addition to regular moisturization, patients with SOC should be reminded to use sunscreen regularly to prevent further pigment darkening.

Patient education

Patient education regarding application techniques (amount, area), useful treatment adjuncts (i.e. non-comedogenic moisturizers) and explanation of disease processes (i.e. comedogenesis) are key to improved outcomes. The importance of adherence to therapy should also be discussed along with managing expectations, such that any noticeable improvement may take weeks of treatment. Improvement of acne and prevention of outbreaks can minimize the development of PIH. A trial evaluating the effects of a topical medication application tutorial was assessed in Koreans with mild-to-moderate acne. Reduced frequency and intensity of treatment-related side effects were found in those educated

with the tutorial. Benefits included reduced erythema, scaling and dryness that improved earlier during the treatment course. By reducing unfavourable effects, patient adherence may be increased, simultaneously improving treatment outcomes.²⁶

Additional pointers to minimize irritation following topical therapy

Certain approaches regarding treatment vehicle, prescribing and application techniques may curtail the potential irritation of topical treatments. First, using a lotion or cream vehicle may be less irritating⁷ and more tolerable than a gel vehicle.⁵ In the tutorial proposed by Kwon et al., a non-comedogenic moisturizer or lotion should be applied 10 minutes prior to medication application.²⁶ Initial dosage should be lowest and titrated up slowly as tolerance increases. Less frequent dosing (e.g. every other day) may induce less irritation.^{5,7} Furthermore, a very small quantity should be applied thinly by rubbing it between two fingertips. Treatment should start with an area <2 cm diameter on the first day and increased by 1 cm for each subsequent application.²⁶

Systemic therapies

Systemic therapy is reserved for patients with moderate-to-severe inflammatory acne or those who do not respond to topical treatments. Given the risk of PIH in patients with SOC, a lower threshold for initiating systemic therapy should be considered in those patients not responding to topicals.

Oral antibiotics

Oral antibiotics can act as an anti-inflammatory as well as an antibacterial agent when treating inflammatory acne in all skin types.³⁶ It is not recommended to use oral antibiotics as monotherapy or for long periods due to the risk of antibiotic resistance.³⁷ To decrease the risk of resistance, a BPO or a topical retinoid should be used concomitantly.^{6,36}

The preferred antibiotics to prescribe are the tetracycline class (doxycycline, minocycline, tetracycline, sarecycline) but macrolides (azithromycin) and trimethoprim/sulfamethoxazole (TMP/SMX) may be prescribed in certain situations where tetracyclines are contraindicated or not tolerated.⁶

Erythromycin and clindamycin are no longer used orally due to their high rates of antibiotic resistance.³⁸ Macrolides and tetracyclines are bacteriostatic, inhibit protein synthesis and also have anti-inflammatory properties. Recommended dosages of tetracyclines are doxycycline 100 mg per day, minocycline 100 mg per day or tetracycline 500 mg twice per day.³⁹ TMP/SMX inhibits bacterial DNA synthesis and the suggested initial dose of TMP/SMX is 160/800 mg twice daily, then switched to once daily if prolonged maintenance therapy is required. It is advised to stop treatment once the number of new lesions is few or none and persistent erythema or hyperpigmentation has diminished.⁴⁰

There are minimal data exploring the use of oral antibiotics specifically for acne management in patients with SOC. Ullah

et al. conducted a trial comparing the efficacy of doxycycline 100 mg daily to azithromycin 500 mg for four consecutive days monthly over 3 months in a Pakistani population. They found doxycycline significantly more effective with 66.8% responders compared to 25.9% with azithromycin.⁴¹ Another study in an Iranian population compared doxycycline (100 mg OD) to azithromycin (500 mg three times weekly) with concomitant tretinoin cream every other day for 12 weeks and did not find significant differences between the two combinations.⁴² Combination therapy of oral antibiotics (doxycycline or minocycline) plus a topical retinoid for an inflammatory flare of acne, followed by continued use of the retinoid for maintenance, has been a well-established treatment regimen in the general population, particularly for patients with SOC.^{6,36}

The most common AEs observed in patients on tetracyclines are gastrointestinal upset and photosensitivity, though less common in deeply pigmented skin.³⁶ Typically, tetracyclines are a very safe class of medications, but more serious AEs should be considered in the benefit-to-risk assessment for treatment. Muller et al.⁴³ performed a study in Guadeloupe to assess the susceptibility of ethnic groups to drug hypersensitivity syndrome (DHS) in a population with predominantly African ancestry. They found the annual incidence rate of DHS was 0.9 in 100,000 and 14% of the cases were likely caused by minocycline.⁴³ Minocycline-induced DHS has been reported in a 20-year-old Japanese patient treated for acne.⁴⁴ A fatal case of DHS was also reported in a 15-year-old African girl treated with minocycline for acne.⁴⁵ In addition to these hypersensitivity reactions, other AEs of minocycline include autoimmune disorders (polyarteritis nodosa, autoimmune hepatitis and lupus-like syndrome) as well as blue/black/grey discoloration of the skin, nails, teeth, sclera, oral mucosa, thyroid, heart valves and bones.⁴⁶ Due to the increased risks of therapy with minocycline, without any added benefit for efficacy, it is used less frequently than doxycycline. The potential adverse reactions seen with TMP/SMX include DHS and Stevens–Johnson syndrome, which, though uncommon, limit its use.³⁶

Isotretinoin

Isotretinoin is most commonly used for severe nodular acne or as an early treatment option in those that are at an increased risk for scarring or who have failed oral antibiotics. It has also been effective in treating PIH, which makes it a suitable option for patients with SOC.⁶ It is important to start at a lower dose and gradually increase to avoid the possibility of an early onset flare.⁶ The typical dosage of isotretinoin is 0.5–1 mg per kg daily with a standard cumulative maximum dose of 120–150 mg per kg per treatment course. After reaching the desired dosage, isotretinoin should be discontinued, even if the acne is not completely clear, as improvement continues for 1–2 months.⁴⁷ Patients treated with isotretinoin had clinical improvement with prolonged remission. Those who experienced resolution of their acne had dramatic improvements in self-esteem as well as social interactions.^{6,36}

Specific data regarding the use of isotretinoin in SOC are limited, but a small open-label study by Kelly et al.⁴⁸ evaluated the efficacy of isotretinoin in 10 African American patients with recalcitrant nodulocystic acne. Of the eight patients who remained in the study, early flares in the temporal and submandibular areas that did not have lesions prior to treatment were noted. PIH improved but an ashen or greyish facial hue due to the drying and desquamative effects was observed. This study highlighted the importance of discussing the clinical course and treatment expectations, and to encourage the patients to continue with therapy despite possible early flares. In conclusion, Kelly et al. determined isotretinoin provided benefit in African Americans as it prevented new acne lesions and improved old, postinflammatory hyperpigmentation.⁴⁸

There are several systemic side effects that can occur with isotretinoin but most relevant to the SOC population are those mucocutaneous effects, such as xerosis and dermatitis, which may increase the risk of PIH. Careful patient selection is necessary as well as education regarding skin barrier management with adjunctive therapies, such as moisturizers and sunscreen, to mitigate this risk.⁴⁹

Oral contraception

Oral contraception (OCP) can effectively treat inflammatory acne⁶ by decreasing sebum production stimulated by androgens.³⁶ It is most commonly used to treat acne in the setting of hyperandrogenism, late-onset acne, jawline and neck distribution, acne with menstrual flare, comedonal acne with seborrhoea, and acne that is resistant to conventional therapy.⁵⁰ There are currently three OCPs that are approved for the treatment of acne by the US Food and Drug Administration; Ortho Tri-Cyclen (norgestimate/ethinyl oestradiol), Estrostep (norethindrone acetate/ethinyl oestradiol) and Yaz (drospirenone/ethinyl oestradiol). Treatment expectations should be discussed because it may take 3–6 months to reach treatment efficacy,⁵⁰ and relapses are common if the medication is discontinued.⁴⁴ There have not been specific studies assessing the role of OCP for acne in patients with SOC. However, OCP should be considered in any woman with SOC who requires birth control, is not planning a family or presents with features of hormonal acne.

Spiroinolactone

Spiroinolactone is used off-label to treat hormonal acne that typically worsens around the menstrual cycle. It is a selective aldosterone blocker that is highly effective for treating acne in adult women. At low doses, it acts as a potassium-sparing diuretic and, at higher doses, it blocks the androgen receptors, reducing sebum production. It has been reported that spiroinolactone at higher doses of 50–200 mg/day can reduce acne lesion counts by 33–85% but specific studies in patients with SOC are lacking.⁴⁹

A study of 139 Japanese patients were treated for 20 weeks with a tapered regimen of oral spiroinolactone. It reported a 100% response rate with approximately 50% of patients having an excellent response.⁵¹ Spiroinolactone has also been used in combination with other acne therapies, including topical retinoids and OCPs that contain drospirenone. These combination treatments have proven both efficacious and well tolerated and could be considered in women with SOC presenting with hormonal acne, particularly those requiring a longer-term treatment.⁵⁰

Chemical peels

Chemical peels in patients with SOC can address both acne and PIH simultaneously.³⁶ Patients with FST IV–VI will typically undergo superficial or medium depth peels with glycolic acid (GA) or salicylic acid (SA). GA, a naturally occurring alpha-hydroxy acid, is used in concentrations of 20–70% and works by inducing epidermolysis, dispersing basal layer melanin and increasing dermal collagen synthesis. SA causes keratolysis by disrupting the intercellular lipid linkages between the epithelioid cells and is used in superficial peels at a concentration of 20–30%.³⁶

It is important to obtain a complete history from the patient prior to treating with a chemical peel, including current oral and topical medications, past reactions to procedures, a history of herpes simplex virus infection, keloids, and hypertrophic scarring or PIH.^{36,52} PIH can develop transiently after a peel in patients with SOC; therefore, common approaches to minimize this are pre-treatment or post-treatment with hydroquinone, starting peels at a lower concentration, repeating peels at less frequent intervals, stopping all retinoid therapies 7 days pre-treatment and educating the patient on the importance of sun protection.³⁶

Many clinical studies have demonstrated the efficacy of improving PIH with chemical peels in patients with SOC.⁵² A study of 44 Indian individuals with facial acne, post-acne scarring and PIH were divided into two groups who received six peels of either GA 35% or SA 20%–mandelic acid (MA) 10% at 2-week intervals. Both peels led to a highly significant reduction and improvement in the total acne score (GA 27.3% versus SA-MA 52.3%) as well as in post-acne hyperpigmentation (GA 46.3% versus SA-MA 59.8%). There was an improvement in ice pick (GA 10.4% versus SA-MA 13.2%) and boxcar (GA 20.1% versus SA-MA 23.3%) scars but no change in rolling scars with either agent.⁵³ Grimes assessed the clinical efficacy and safety of superficial SA peels in individuals with FST V–VI.⁵⁴ Of 25 patients with SOC, 9 had acne vulgaris, 5 had PIH, 6 had melasma and 5 had rough, oily, skin with enlarged pores. All 25 individuals were pretreated with hydroquinone 4% for 2 weeks before undergoing five salicylic acid chemical peels 20–30%, 2 weeks apart. Moderate-to-significant improvement was obtained in 88% of patients with acne and in 100% of those with PIH.⁵⁴

In addition to treating PIH with chemical peels, various other physical modalities, such as microneedling, dermabrasion and laser, can also be used to manage the resulting PIH post-acne but these are beyond the scope of this review and will not be discussed here.

Conclusion

Acne vulgaris is one of the most common cutaneous conditions regardless of race or ethnicity. There is a unique and challenging characteristic in patients with SOC, namely hyperpigmentation remaining after acne lesions have resolved, which is often more problematic than the acne itself.³⁶ Early treatment is important in patients with SOC to reduce inflammation early on and to reduce the risk of PIH development.³⁹ In addition to regular gentle skincare practices and sun protection, both topical and systemic therapies as well as procedures are available, and their use should be tailored to each patient individually. Topical therapy should be used first line, with retinoids and AzA favoured in SOC due to their added benefit with PIH treatment. Topical therapies may also be initiated at lower concentrations to avoid skin irritation and potential iatrogenic PIH, increasing use as tolerated.

Combination therapies with retinoids plus BPO, antibiotics plus BPO, or antibiotics plus retinoids may be more effective by targeting multiple pathogenic factors, with retinoids plus BPO favoured as first-line treatment. AzA can be effective in preventing PIH due to its antityrosine activity. Systemic treatment should be considered early if topical therapy fails. Procedural therapies, including chemical peels with GA or SA, can be beneficial as well. Although there are many treatment options available, more evidence is needed in the SOC population to determine the best approach to managing acne in ethnic skin, especially regarding PIH. Other areas requiring further clarification include investigating the tolerability and efficacy of specific concentrations and vehicles between FST, developing new treatments with dual efficacy for both active acne and hyperpigmentation, and therapies that specifically target PIH. Further investigations should explore potential cultural factors that may exacerbate acne. With increased knowledge about acne in patients with SOC, prescribers can be educated on the importance of the early introduction of appropriate treatments, proper skincare, and sun protection to prevent or treat resulting hyperpigmentation. Appropriate management can reduce the significant burden and impact that acne carries on these patients.

Key practice points

- For patients with skin of colour (SOC), appropriate regimens should prioritize targeting inflammatory processes early to prevent postinflammatory hyperpigmentation (PIH), reduce existing PIH and have minimal treatment-related irritation to avoid causing new PIH.
- Regular moisturizer use can maintain the skin barrier and reduce irritant effects of topical treatments (e.g. retinoids) and prevent flare-up of inflammatory lesions. Adherence to medication may be increased, improving overall outcomes.
- Sun protection, including sun avoidance and sunscreen application, should be counselled to help prevent the development or worsening of PIH.
- Patient education regarding the application (size, amount, technique) can reduce treatment-related adverse effects and improve subsequent adherence and outcomes.
- Topical retinoids, topical antibiotics, benzoyl peroxide (BPO) and azelaic acid, when used properly, will reduce PIH and not exacerbate it further.
- Combinations of topical therapies are more effective than monotherapy.
- Early aggressive treatments that are tolerable should be considered to prevent PIH.
- Consider a lower treatment initiation threshold and start systemic treatment earlier on in patients with SOC as the risk for hyperpigmentation and keloid scarring is higher in this population.
- Avoid long-term use of oral antibiotics, and during short-term use, BPO should be used concomitantly to reduce the risk of developing antibiotic resistance.
- Oral antibiotics combined with a topical retinoid with or without BPO should be used during an inflammatory acne flare followed by continued use of the topical retinoid as maintenance in patients with SOC.
- Isotretinoin is useful for treating nodulocystic acne, acne that is resistant to topical treatment or oral antibiotics and can improve PIH.
- There are currently three oral contraceptive pills approved for the treatment of acne vulgaris by the US Food and Drug Administration; Ortho Tri-Cyclen (norgestimate/ethinyl oestradiol), Estrostep (norethindrone acetate/ethinyl oestradiol) and Yaz (drospirenone/ethinyl oestradiol).
- Spironolactone is highly effective in treating acne in adult women and can be used in combination with topical therapies, such as retinoids, to prevent or treat PIH.
- Chemical peels can address both acne and PIH simultaneously.

Contributions: CC and MW did the original literature search, and MG did a separate search to check. All participated in writing and editing. All named authors meet the International Committee of Medical Journal Editors (ICMJE) criteria for authorship for this article, take responsibility for the integrity of the work as a whole, and have given their approval for this version to be published.

Disclosure and potential conflicts of interest: CC and MW have no conflicts to disclose. MJG has been an investigator, speaker and/or advisor for: AbbVie, Amgen, Akros, AnaptysBio, Aslan, Arcutis, Bausch Health, BMS, Boehringer Ingelheim, Celgene, Dermira, Dermavant, Eli Lilly, Galderma, GSK, Incyte, Janssen, Kyowa Kirin, LEO Pharma, MedImmune, Merck, Novartis, Pfizer, Regeneron, Roche, Sanofi Genzyme, Sun Pharma, and UCB. The International Committee of Medical Journal Editors (ICMJE) Potential Conflicts of Interests form for the authors is available for download at: <https://www.drugsincontext.com/wp-content/uploads/2022/02/dic.2021-10-9-COI.pdf>

Acknowledgements: None.

Funding declaration: There was no funding associated with the preparation of this article.

Copyright: Copyright © 2022 Chiang C, Ward M, Gooderham M. Published by *Drugs in Context* under Creative Commons License Deed CC BY NC ND 4.0, which allows anyone to copy, distribute and transmit the article provided it is properly attributed in the manner specified below. No commercial use without permission.

Correct attribution: Copyright © 2022 Chiang C, Ward M, Gooderham M. <https://doi.org/10.7573/dic.2021-10-9>. Published by *Drugs in Context* under Creative Commons License Deed CC BY NC ND 4.0.

Article URL: <https://www.drugsincontext.com/dermatology-how-to-manage-acne-in-skin-of-colour>

Correspondence: Melinda Gooderham, SKiN Centre for Dermatology, 775 Monaghan Road South, Peterborough, ON K9J 5K2, Canada. Email: mgooderham@centrefordermatology.com

Provenance: Invited; externally peer reviewed.

Submitted: 31 October 2021; **Accepted:** 10 January 2022; **Publication date:** 31 May 2022.

Drugs in Context is published by BioExcel Publishing Ltd. Registered office: Plaza Building, Lee High Road, London, England, SE13 5PT.

BioExcel Publishing Limited is registered in England Number 10038393. VAT GB 252 7720 07.

For all manuscript and submissions enquiries, contact the Editorial office editorial@drugsincontext.com

For all permissions, rights and reprints, contact David Hughes david.hughes@bioexcelpublishing.com

References

1. Williams HC, Dellavalle RP, Garner S. Acne vulgaris. *Lancet*. 2012;379(9813):361–372. [https://doi.org/10.1016/S0140-6736\(11\)60321-8](https://doi.org/10.1016/S0140-6736(11)60321-8)
2. GBD 2016 Disease and Injury Incidence and Prevalence Collaborators. Global, regional, and national incidence, prevalence, and years lived with disability for 328 diseases and injuries for 195 countries, 1990–2016: a systematic analysis for the Global Burden of Disease Study 2016. *Lancet*. 2017;390:1211–1259. [https://doi.org/10.1016/s0140-6736\(17\)32154-2](https://doi.org/10.1016/s0140-6736(17)32154-2)
3. Davis SA, Narahari S, Feldman SR, et al. Top dermatologic conditions in patients of color: an analysis of nationally representative data. *J Drugs Dermatol*. 2012;11:466–473.
4. Bhatia ND, Werschler WP, Cook-Bolden FE, Guenin E. Tolerability of tretinoin lotion 0.05% for moderate to severe acne vulgaris: a post hoc analysis in a black population. *Cutis*. 2020;106(1):45–50;E1. <https://doi.org/10.12788/cutis.0059>
5. Kundu RV, Patterson S. Dermatologic conditions in skin of color: part I. Special considerations for common skin disorders. *Am Fam Physician*. 2013;87(12):850–856.
6. Yin NC, McMichael AJ. Acne in patients with skin of color: practical management. *Am J Clin Dermatol*. 2014;15(1):7–16. <https://doi.org/10.1007/s40257-013-0049-1>
7. Shah SK, Alexis AF. Acne in skin of color: practical approaches to treatment. *J Dermatolog Treat*. 2010;21(3):206–211. <https://doi.org/10.3109/09546630903401496>
8. Bell MA, Whang KA, Thomas J, Aguh C, Kwatra SG. Racial and ethnic disparities in access to emerging and frontline therapies in common dermatological conditions: a cross-sectional study. *J Natl Med Assoc*. 2020;112(6):650–653. <https://doi.org/10.1016/j.jnma.2020.06.009>
9. Harper JC, Roberts WE, Zeichner JA, Guenin E, Bhatt V, Pillai R. Novel tretinoin 0.05% lotion for the once-daily treatment of moderate-to-severe acne vulgaris: assessment of safety and tolerability in subgroups. *J Dermatolog Treat*. 2020;31(2):160–167. <https://doi.org/10.1080/09546634.2019.1587884>
10. Han G, Armstrong AW, Desai SR, Guenin E. Novel tretinoin 0.05% lotion for the once-daily treatment of moderate-to-severe acne vulgaris in an asian population. *J Drugs Dermatol*. 2019;18(9):910–916.

11. Chularojanamontri L, Tuchinda P, Kulthanan K, Varothai S, Winayanuwattikun W. A double-blinded, randomized, vehicle-controlled study to assess skin tolerability and efficacy of an anti-inflammatory moisturizer in treatment of acne with 0.1% adapalene gel. *J Dermatolog Treat.* 2016;27(2):140–145. <https://doi.org/10.3109/09546634.2015.1079298>
12. Jacyk WK. Adapalene in the treatment of African patients. *J Eur Acad Dermatol Venereol.* 2001;15(Suppl. 3):37–42. <https://doi.org/10.1046/j.0926-9959.2001.00011.x>
13. Czernielewski J, Poncet M, Mizzi F. Efficacy and cutaneous safety of adapalene in black patients versus white patients with acne vulgaris. *Cutis.* 2002;70(4):243–248.
14. Goh CL, Tang MB, Briantais P, Kaoukhov A, Soto P. Adapalene gel 0.1% is better tolerated than tretinoin gel 0.025% among healthy volunteers of various ethnic origins. *J Dermatolog Treat.* 2009;20(5):282–288. <https://doi.org/10.1080/09546630902763164>
15. Wilhelm KP, Wilhelm D, Neumeister C, Zsolt I, Schwantes U. Lack of irritative potential of nadifloxacin 1% when combined with other topical anti-acne agents. *Clin Exp Dermatol.* 2012;37:112–117. <https://doi.org/10.1111/j.1365-2230.2011.04214.x>
16. Jung JY, Kwon HH, Yeom KB, Yoon MY, Suh DH. Clinical and histological evaluation of 1% nadifloxacin cream in the treatment of acne vulgaris in Korean patients. *Int J Dermatol.* 2011;50(3):350–357. <https://doi.org/10.1111/j.1365-4632.2010.04701.x>
17. Guay DR. Topical clindamycin in the management of acne vulgaris. *Exp Opin Pharmacother.* 2007;8:2625–2664. <https://doi.org/10.1517/14656566.8.15.2625>
18. Alexis AF, Burgess C, Callender VD, et al. The efficacy and safety of topical dapsone gel, 5% for the treatment of acne vulgaris in adult females with skin of color. *J Drugs Dermatol.* 2016;15(2):197–204.
19. Taylor SC, Cook-Bolden FE, McMichael A, et al. Efficacy, safety, and tolerability of topical dapsone gel, 7.5% for treatment of acne vulgaris by Fitzpatrick skin phototype. *J Drugs Dermatol.* 2018;17(2):160–167. <https://doi.org/10.1016/j.jval.2017.08.3004>
20. Piette WW, Taylor S, Pariser D, Jarratt M, Sheth P, Wilson D. Hematologic safety of dapsone gel, 5%, for topical treatment of acne vulgaris. *Arch Dermatol.* 2008;144(12):1564–1570. <https://doi.org/10.1001/archdermatol.2008.518>
21. Kawashima M, Hashimoto H, Alio Sáenz AB, Ono M, Yamada M. Is benzoyl peroxide 3% topical gel effective and safe in the treatment of acne vulgaris in Japanese patients? A multicenter, randomized, double-blind, vehicle-controlled, parallel-group study. *J Dermatol.* 2014;41(9):795–801. <https://doi.org/10.1111/1346-8138.12580>
22. Kawashima M, Nagare T, Doi M. Clinical efficacy and safety of benzoyl peroxide for acne vulgaris: comparison between Japanese and Western patients. *J Dermatol.* 2017;44(11):1212–1218. <https://doi.org/10.1111/1346-8138.13996>
23. Kircik LH. Efficacy and safety of azelaic acid (Aza) gel 15% in the treatment of post-inflammatory hyperpigmentation and acne: a 16-week, baseline-controlled study. *J Drugs Dermatol.* 2011;10(6):586–590.
24. Alexis AF, Johnson LA, Kerrouche N, Callender VD. A subgroup analysis to evaluate the efficacy and safety of adapalene-benzoyl peroxide topical gel in black subjects with moderate acne. *J Drugs Dermatol.* 2014;13(2):170–174.
25. Kim WJ, Park JM, Ko HC, Kim BS, Kim MB, Song M. A split-faced, observer-blinded comparison study of topical adapalene/benzoyl peroxide and adapalene in the treatment of Asian acne patients. *J Drugs Dermatol.* 2013;12(2):149–151.
26. Kwon HH, Park SY, Yoon JY, Min S, Suh DH. Do tutorials on application method enhance adapalene-benzoyl peroxide combination gel tolerability in the treatment of acne? *J Dermatol.* 2015;42(11):1058–1065. <https://doi.org/10.1111/1346-8138.12979>
27. DuBois J, Ong GCW, Petkar G, et al. Patient-Reported outcomes in acne patients with skin of color using adapalene 0.3%-benzoyl peroxide 2.5%: a prospective real-world study. *J Drugs Dermatol.* 2019;18(5):514.
28. Eichenfield LF, Krakowski AC. Moderate to severe acne in adolescents with skin of color: benefits of a fixed combination clindamycin phosphate 1.2% and benzoyl peroxide 2.5% aqueous gel. *J Drugs Dermatol.* 2012;11(7):818–824.
29. Cook-Bolden FE. Treatment of moderate to severe acne vulgaris in a Hispanic population: a post-hoc analysis of efficacy and tolerability of clindamycin phosphate 1.2%/benzoyl peroxide 2.5% gel. *J Drugs Dermatol.* 2012;11(4):455–459.
30. Callender VD. Fitzpatrick skin types and clindamycin phosphate 1.2%/benzoyl peroxide gel: efficacy and tolerability of treatment in moderate to severe acne. *J Drugs Dermatol.* 2012;11(5):643–648.
31. Ko HC, Song M, Seo SH, Oh CK, Kwon KS, Kim MB. Prospective, open-label, comparative study of clindamycin 1%/benzoyl peroxide 5% gel with adapalene 0.1% gel in Asian acne patients: efficacy and tolerability. *J Eur Acad Dermatol Venereol.* 2009;23(3):245–250. <https://doi.org/10.1111/j.1468-3083.2008.02920.x>
32. Taylor SC. Utilizing combination therapy for ethnic skin. *Cutis.* 2007;80(Suppl. 1):15–20.
33. Jarratt MT, Brundage T. Efficacy and safety of clindamycin-tretinoin gel versus clindamycin or tretinoin alone in acne vulgaris: a randomized, double-blind, vehicle-controlled study. *J Drugs Dermatol.* 2012;11(3):318–326.
34. Callender VD, Young CM, Kindred C, Taylor SC. Efficacy and safety of clindamycin phosphate 1.2% and tretinoin 0.025% gel for the treatment of acne and acne-induced post-inflammatory hyperpigmentation in patients with skin of color. *J Clin Aesthet Dermatol.* 2012;5(7):25–32.

35. Kulthanan K, Trakanwittayarak S, Tuchinda P, Chularojanamontri L, Limphoka P, Varothai S. A double-blinded, randomized, vehicle-controlled study of the efficacy of moisturizer containing licochalcone a, decanediol, l-carnitine, and salicylic acid for prevention of acne relapse in Asian population. *Biomed Res Int*. 2020;2020:2857812. <https://doi.org/10.1155/2020/2857812>
36. Davis EC, Callender VD. A review of acne in ethnic skin: pathogenesis, clinical manifestations, and management strategies. *J Clin Aesthet Dermatol*. 2010;3(4):24–38.
37. Dreno B, Thiboutot D, Gollnick H, et al. Antibiotic stewardship in dermatology: limiting antibiotic use in acne. *Eur J Dermatol*. 2014;24:330–334. <https://doi.org/10.1684/ejd.2014.2309>
38. Baldwin H. Oral antibiotic treatment options for acne vulgaris. *J Clin Aesthet Dermatol*. 2020;13(9):26–32.
39. Bagatin E, Florez-White M, Arias-Gomez MI, Kaminsky A. Algorithm for acne treatment: Ibero-Latin American consensus. *An Bras Dermatol*. 2017;92(5):689–693. <https://doi.org/10.1590/abd1806-4841.20177003>
40. McCarty M, Rosso JQ. Chronic administration of oral trimethoprim-sulfamethoxazole for acne vulgaris. *J Clin Aesthet Dermatol*. 2011;4(8):58–66.
41. Ullah G, Noor SM, Bhatti Z, Ahmad M, Bangash AR. Comparison of oral azithromycin with oral doxycycline in the treatment of acne vulgaris. *J Ayub Med Coll Abbottabad*. 2014;26:64–67.
42. Moravvej H, Mousazadeh HA, Yousefi M, Givrad S. Efficacy of doxycycline versus azithromycin in the treatment of moderate facial acne vulgaris. *Iran J Dermatol*. 2012;15(1):7–10.
43. Muller P, Dubreil P, Mahé A, Lamaury I, Salzer B, Deloumeaux J, Strobel M. Drug hypersensitivity syndrome in a West-Indian population. *Eur J Dermatol*. 2003;13(5):478–481.
44. Tsuruta D, Someda Y, Sowa J, Kobayashi H, Ishii M. Drug hypersensitivity syndrome caused by minocycline. *J Cutan Med Surg*. 2006;10:131–135. <https://doi.org/10.2310/7750.2006.00019>
45. Eshki M, Allanore L, Musette P, et al. Twelve-Year analysis of severe cases of drug reaction with eosinophilia and systemic symptoms. *Arch Dermatol*. 2009;145(1):67–72. <https://doi.org/10.1001/archderm.145.1.67>
46. Garner SE, Eady A, Bennett C, Newton JN, Thomas K, Popescu CM. Minocycline for acne vulgaris: efficacy and safety. *Cochrane Database Syst Rev*. 2012;(8):CD002086. <https://doi.org/10.1002/14651858.cd002086.pub2>
47. Johnson B, Nunley J. Use of systemic agents in the treatment of acne vulgaris. *Am Fam Physician*. 2000;62(8):1823–1830.
48. Kelly AP, Sampson DD. Recalcitrant nodulocystic acne in black Americans: treatment with isotretinoin. *J Natl Med Assoc*. 1987;79(12):1266–1270.
49. Lawson CN, Hollinger J, Sethi S, et al. Updates in the understanding and treatments of skin & hair disorders in women of color. *Int J Womens Dermatol*. 2017;3(Suppl. 1):S21–S37. <https://doi.org/10.1016/j.ijwd.2017.02.006>
50. Trivedi MK, Shinkai K, Murase JE. A Review of hormone-based therapies to treat adult acne vulgaris in women. *Int J Womens Dermatol*. 2017;3(1):44–52. <https://doi.org/10.1016/j.ijwd.2017.02.018>
51. Sato K, Matsumoto D, Iizuka F, Aiba-Kojima E, Watanabe-Ono A, Suga H. Anti-androgenic therapy using oral spironolactone for acne vulgaris in Asians. *Aesthet Plast Surg*. 2006;30:689–694. <https://doi.org/10.1007/s00266-006-0081-0>
52. Roberts WE. Chemical peeling in ethnic/dark skin. *Dermatol Ther*. 2004;17:196–205. <https://doi.org/10.1111/j.1396-0296.2004.04020.x>
53. Garg VK, Sinha S, Sarkar R. Glycolic acid peels versus salicylic–mandelic acid peels in active acne vulgaris and post-acne scarring and hyperpigmentation: a comparative study. *Dermatol Surg*. 2009;35:59–65. <https://doi.org/10.1111/j.1524-4725.2008.34383.x>
54. Grimes PE. The safety and efficacy of salicylic acid chemical peels in darker racial-ethnic groups. *Dermatol Surg*. 1999;25:18–22. <https://doi.org/10.1046/j.1524-4725.1999.08145.x>