

Original Article

Asian Pacific Journal of Tropical Biomedicine

journal homepage: www.apjtb.org



doi: 10.4103/2221-1691.311755

Impact Factor: 1.90

Origanum vulgare L. leaf extract alleviates finasteride-induced oxidative stress in mouse liver and kidney

Qi-Feng Sun¹, Shi-Xiang Chen², Zhang-Feng Tang³, Xiao-Yi Song³, Fa Jing³, Hao-Tian Wu³, Zhong-Yang Ding³, Attalla El-kott^{4,5}, Daa Massoud^{6,7}, Heba Khalifa⁵

¹Department of Hepatobiliary and Vascular Surgery, Jinan City People's Hospital, Jinan, Shandong Province, 271100, China

²Department of Hepatology, Zhejiang University Ming Zhou Hospital, Ningbo, Zhejiang Province, 315199, China

³Department of General Surgery, Wuxi Traditional Chinese Medicine Hospital Affiliated to Nanjing University of Traditional Chinese Medicine, Wuxi, Jiangsu Province, 214023, China

⁴Biology Department, College of Science, King Khalid University, Abha, Saudi Arabia

⁵Zoology Department, College of Science, Damanhour University, Damanhour, Egypt

⁶Biology Department, College of Science, Jouf University, P.O. Box 2014, Sakaka, Al-Jouf, Saudi Arabia

⁷Zoology Department, Faculty of Science, Fayoum University, Fayoum, Egypt

ABSTRACT

Objective: To investigate the hepatorenoprotective effects of *Origanum vulgare* L. against finasteride-induced oxidative injury in the liver and kidney of mice.

Methods: Liquid chromatography-electrospray ionization-tandem mass spectrometry (LC-ESI/MS) analysis was utilized to yield a fingerprint of *Origanum vulgare* polyphenolic constituents. Thirty BALB/c mice received 0.5 mL/day distilled water, finasteride (25 mg/kg/day for 10 d), and 100, 200, or 400 mg/kg/day finasteride + *Origanum vulgare* extract with 6 mice per group for five weeks. On day 36, liver and kidney function as well as pro- and anti-inflammatory (IFN- γ , IL-12, IL-6, TNF- α , IL-1 β , and IL-10) cytokines were measured. The total antioxidant status, nitric oxide (NO), and malondialdehyde levels as well as the activities of NO synthase and catalase were also evaluated. Histopathological study was conducted to assess the effect of *Origanum vulgare* extract on finasteride-induced renal and hepatic toxicities.

Results: Twenty-five major polyphenolic compounds were identified in the *Origanum vulgare* extract by LC-ESI/MS. *Origanum vulgare* extract, especially at 200 and 400 mg/kg/day doses, significantly improved liver and kidney biochemical indices, decreased inflammatory cytokines, increased total antioxidant status and NO synthase and catalase activities, as well as decreased plasma NO and malondialdehyde levels in a dose-dependent manner as compared to the finasteride group. Histopathological results further confirmed the protective effect of *Origanum vulgare* extract.

Conclusions: *Origanum vulgare* extract ameliorates finasteride-induced hepatic and renal biochemical and histopathological alterations, and restores antioxidant/oxidant balance.

KEYWORDS: Kidney; Liver; *Origanum vulgare* L.; Inflammation; Antioxidant

1. Introduction

Finasteride (propecia) is a synthetic selective 5- α reductase type II inhibitor that suppresses the conversion of testosterone to dihydrotestosterone[1]. Finasteride is used to treat a variety of disorders including androgenic alopecia, benign prostatic hyperplasia, and prostate cancer, but its application is limited due to its different side effects such as alternation in sexual behavior, ejaculation disorder, and liver and kidney toxicities[2]. Many studies have shown that 25-250 mg/kg/day of finasteride significantly increases the activity of liver enzymes and induces hepatocyte hyperplasia and hepatic parenchyma degeneration and fibrosis, especially in people with acute androgenic alopecia and benign prostatic hyperplasia who receive high doses of this drug[3].

✉To whom correspondence may be addressed. E-mail: dzy7758@sina.com

This is an open access journal, and articles are distributed under the terms of the Creative Commons Attribution-Non Commercial-ShareAlike 4.0 License, which allows others to remix, tweak, and build upon the work non-commercially, as long as appropriate credit is given and the new creations are licensed under the identical terms.

For reprints contact: reprints@medknow.com

©2021 Asian Pacific Journal of Tropical Biomedicine Produced by Wolters Kluwer-Medknow. All rights reserved.

How to cite this article: Sun QF, Chen SX, Tang ZF, Song XY, Jing F, Wu HT, et al. *Origanum vulgare* L. leaf extract alleviates finasteride-induced oxidative stress in mouse liver and kidney. Asian Pac J Trop Biomed 2021; 11(5): 194-204.

Article history: Received 14 July 2020; Revision 27 August 2020; Accepted 28 December 2020; Available online 5 April 2021

Although the mechanism of hepatotoxicity of finasteride is unknown, it seems that the azasteroids metabolized by cytochrome P450 (CYP 3A4) are likely to interfere with the activity of hepatocytes and Ito cells and eventually alter the liver physiological activity[4]. Besides, due to the renal excretion of 36%-42% of finasteride metabolites, damage to the glomerular basement membrane and the podocytes and epithelial cells of proximal convoluted tubules is expectable. Also, it has been shown that low doses (e.g. 5 mg/kg) of finasteride can induce IL-6 production, renal tubular epithelial cell apoptosis, and thickening of the collagen surrounding the tubules, eventually causing renal lymphocytic infiltration, tubular fibrosis, and glomerulosclerosis[5]. Moreover, finasteride promotes the formation of tubular casts and calcium oxalate (CaOx) kidney stones through androgenic receptor-dependent signaling pathways[6]. Various studies have also shown that finasteride reduces renal physiological activity and ultimately leads to chronic kidney disease through triggering inflammatory pathways and interfering with androgenic receptor-regulated renal hormonal homeostasis and hemodynamics[7].

Origanum vulgare L. (*O. vulgare*) belongs to the Lamiaceae family and grows in Asia and Europe. This plant has always been used in traditional medicine due to the presence of important flavonoid compounds such as apigenin, kaempferol, myricetin, quercetin, naringenin, and rosmarinic acid and its antioxidant, anti-inflammatory, anti-cancer, anti-depressant, anti-viral, and anti-microbial properties[8]. Therefore, the present study was conducted to investigate the protective effects of *O. vulgare* hydroalcoholic extract against finasteride-induced hepatic and renal toxicities in mice.

2. Materials and methods

2.1. Preparation of *O. vulgare* extract

O. vulgare leaves were gathered from the rivers of Shaanxi province, China, identified by a botanist (voucher NO: XBGH710061), and dried in dark at 40°C. After grinding, the dried leaves were poured into 70% ethanol, mixed gently, and then the extract solution was passed through a filter paper (Whatman no. 42, Millipore, USA. Cat no. 1442125), condensed by a rotary evaporator (Buchi RE111) at 50°C, and finally dried at room temperature for 72 h. The final dried *O. vulgare* extract (35 g) was stored at 4°C until use[9].

2.2. Liquid chromatography–electrospray ionization–tandem mass spectrometry (LC–ESI/MS) analysis

The Agilent G6410 Triple Quadrupole Mass spectrometer (Agilent, Waldbronn, Germany) equipped with the Agilent zorbax SB-C18 (15 cm, 3.5 µm) column coupled with a HCTultra ion trap MS detector was used to analyze polyphenolic compounds in the plant. The LC condition was set as follows: mobile phase A: acetonitrile 0.1% (v/v) + formic acid 0.1% (v/v), and B: H₂O + formic acid 0.1% (v/v).

Linear gradients included 0%, 5%, 95% (repeated twice), and 100% for solution A and 0%, 95%, 5% (repeated twice), and 100% for solution B with applying 0.3 mL/min washing time for 75 min. The injection volume was set as 20 µL with a flow rate of 0.2 mL/min in negative ion mode (ESI) using an ESI ion source electrospray (Bruker Daltonik GmbH, Bremen, Germany). Also, gain and probe voltage of LC detection were 1.8 kV and 3.5 kV, respectively. The nebulizer gas was N₂ (grade 5) at the 1.2 mL/min flow rate, 285°C block temperature, and 30 psi N₂ nebulizing pressure. To identify the extract compounds, quality control samples were prepared by diluting separate analytic stock solutions using the same volume of a known internal standard[9].

2.3. Experimental design, animals, and treatment groups

Thirty BALB/c male mice [7 to 8-week-old, weighing (30 ± 4) g] were obtained from the Animal House Section of People's Hospital, Jinan City, Shandong Province, China. The animals were kept in polypropylene cages (6 animals per cage) and maintained under 12:12 h light: dark cycles in a well-ventilated room at (25±2)°C and (50±5)% relative humidity. The animals were fed with water and solid standard pellets for mice *ad libitum* in accordance with internationally accepted guidelines for use and care of laboratory animals (EEC Directive of 1986; 86/09/EEC; National Institutes of Health publication 85-23, revised 1985). After acclimation, the mice were randomly divided into five groups (*n* = 6 per group) as follows: Group 1: Normal (vehicle control) group, receiving 0.5 mL/day distilled water by gavage; Group 2: Model group, receiving 25 mg/kg/day of finasteride in 0.5 mL distilled water by gavage; Group 3-5: Treatment groups, receiving 100, 200 and 400 mg/kg/day of *O. vulgare* extract in 0.5 mL distilled water[10], respectively, and 25 mg/kg/day of finasteride in 0.5 mL distilled water by gavage[11].

There were no specific criteria for selection of mice in this study, and the animals that received finasteride and were eligible to continue the study were randomly assigned to the groups 2-5. Treatments continued daily for 35 d.

2.4. Acute toxicity test (LD₅₀)

The Lork's two-step method was used to determine the acute toxicity dose (lethal dose- LD₅₀) of *O. vulgare* extract in mice. In this method, three groups of mice (three animals per group) were first injected intraperitoneally with the extract doses of 100, 500, and 1000 mg/kg. During a 24-hour period, the survival of mice and toxic effects of the extract were evaluated in each group. At the second step, three mice each received the extract doses of either 1000, 3000, or 4500 mg/kg *via* intraperitoneal injection, and the potential toxic effects of these doses were investigated. Finally, LD₅₀ of the extract was calculated using the following equation:

$$LD_{50} = (D_0 \times D_{100})^{1/2}$$

Where D₀ is the highest dose in which no mortality occurred, and D₁₀₀ is the lowest dose that caused mortality[12].

2.5. Total phenolic content (TPC)

A modified Folin-Ciocalteu assessment was used to determine the TPC of *O. vulgare* extract by using gallic acid as a standard. In this method, gallic acid (50 µL) at concentrations of 0.024, 0.075, 0.105, 0.3, and 0.4 mg/mL was gently mixed with sodium carbonate (Na₂CO₃) 7.5% (0.8 mL), Folin-Ciocalteu's reagent (1.0 mL), and *O. vulgare* ethanolic extract (50 µL). After two hours of incubation at 30 °C, the solution optical density (OD) was read at 765 nm with a spectrophotometer (Shimadzu UV-Vis spectrophotometer, Shimadzu, Japan). Finally, the TPC of *O. vulgare* extract was expressed as mg of gallic acid equivalent per gram of dried plant (mg GAE/g)[13].

2.6. Total flavonoid content (TFC)

A modified Miliauskas-Venskutonis assessment was used to determine the TFC of *O. vulgare* extract. In this method, an alcoholic mixture of ethanol/methanol (1 to 5 ratio) was prepared and added slowly to another solution containing potassium acetate 1 M (0.1 mL), aluminum trichloride (AlCl₃) 0.1 M (0.1 mL), and distilled water (2.8 mL). Then 10 mg of *O. vulgare* ethanolic extract was added to this solution and incubated at 25 °C for 30 min. Finally, the obtained solution absorbance was read at 415 nm by a spectrophotometer (Shimadzu UV-Vis spectrophotometer, Shimadzu, Japan), and the TFC of *O. vulgare* extract was expressed as mg of rutin equivalent (RE) per 1 g of *O. vulgare* extract (mg RE/g)[14].

2.7. 2,2-diphenyl-1-picrylhydrazyl (DPPH) radical scavenging activity

A modified Brand-Williams assay was used to determine the DPPH radical scavenging activity of *O. vulgare* extract. For this, 3 mL of methanol DPPH radical solution (0.06 mM) was added to 25 to 170 µL aliquots of *O. vulgare* extract, and the solution was incubated at 25 °C for 3 h. Then the OD of the resulted solution was read at 516 nm by a spectrophotometer (Shimadzu UV-Vis spectrophotometer, Shimadzu, Japan) at dark, and according to the Trolox calibration curve, the DPPH radical scavenging activity of the extract was expressed as µM Trolox equivalent per 10 g of dried extract (µmol TE/10 g plant)[15].

2.8. Ferric reducing antioxidant power (FRAP) assay

A modified Benzie-Strain assay was used to determine the antioxidant activity of *O. vulgare* extract. In this pH-dependent method (pH = 3.6), the yellow Fe (III)-tripirydyltriazine complex is converted to the Fe (II)-tripirydyltriazine complex. *O. vulgare* extract was dissolved in methanol to reach 1 mg/mL concentration, and 20 µL of this solution was added to 180 µL distilled water containing 2 µL FRAP solution. Then the ODs of the obtained solution and methanol (as blank) were read at 593 nm by a spectrophotometer (Shimadzu UV-Vis spectrophotometer, Shimadzu, Japan), and the results were expressed as mM Fe (II) sulfate heptahydrate per mg of

O. vulgare extract [mmol Fe (II)/mg plant][16].

2.9. Biochemical analysis

After 24 hours of fasting, the animals were weighed and sacrificed (on day 36) by cervical dislocation using standard laboratory animal protocols. Blood samples were collected through cardiac puncture and incubated at 37 °C for 15 min to allow clot formation. Then serum samples were separated by centrifugation (3000 g for 15 min) to assess the liver and kidney biochemical parameters. The liver and kidney tissues were dissected, weighed with a digital scale (AND FA 2014, China) and fixed in 10% formalin solution for histopathological evaluation. Serum levels of the liver and kidney function parameters including alkaline phosphatase (ALP) (Cat No: 102395H917), aspartate aminotransferase (AST) (Cat No: 118408H912), alanine aminotransferase (ALT) (Cat No: 119395H917), gamma-glutamyl transferase (GGT) (Cat No: 120158H917), albumin (ALB) (Cat No: 101504H917), total bilirubin (TB) (Cat No: 105395H917), and total protein (TP) (Cat No: 128395H917), as well as serum creatinine (Cr) (Cat No: 109395H917) and blood urea nitrogen (BUN) (Cat No: 129395H917) levels were measured using ELISA quantification commercial kits following the manufacturer's protocols (Pars Azmoon, Tehran, Iran) and applying a spectrophotometer (SINCO)[17]. Also, the serum levels of sodium and potassium ions were measured by a photometric method (Jenway Flame photometer PFP)[18].

2.10. Determination of pro- and anti-inflammatory cytokines

Commercial ELISA kits (IFN-γ Cat. No.: 88-7314-88; IL-12 Cat. No.: 88-7121-88; IL-10 Cat. No.: 88-7105-22; IL-6, Cat. No.: 88-7064-88; TNF-α, Cat. No.: 88-7324-88; and IL-1β, Cat. No.: 88-7013-88) were purchased from Invitrogen; Thermo Fisher Scientific Inc. (Heidelberg, Germany) to determine serum levels of the cytokines according to the manufacturer's standard protocols. All the experiments were performed in duplicate. Briefly, a 96-well plate was first pre-coated and incubated with primary antibodies and 10× coating buffer at 37 °C for 24 h. Then the plates were washed three times with phosphate buffered saline, and 5× ELISA/ELISPOT diluent was added for blocking. After 1-hour incubation at 37 °C, the standard dilution of serum samples was prepared and added to the tubes. Then a diluted (detecting) secondary biotin-conjugated antibody was added to the tubes which afterward were incubated for 30 min at 37 °C. Finally, the color produced by the chromogenic substrate of 3,3',5,5'-tetramethylbenzidine was read using an ELISA reader (Biotek Instruments, USA) at 450 nm. Serum levels of IFN-γ, IL-1β, IL-6 and TNF-α (pg/mL) as well as IL-10 and IL-12 (ng/mL) were reported[19].

2.11. Evaluation of oxidative stress

2.11.1. Nitric oxide (NO) assay

The Griess colorimetric method was used to measure NO level. Briefly, 6 mg of zinc sulfate was added to 400 µL of serum samples,

and the mixture was centrifuged at 12000 *g* for 12 min. Then the supernatant was added to a solution containing 50 μ L sulfanilamide, 50 μ L *N*-(1-naphthyl) ethylenediamine dihydrochloride, and 100 μ L vanadium chloride and incubated at 37 °C for 100 min. The absorption of the resulting solution was read by an ELISA reader (Biotek Instruments, USA) at 540 and 630 nm wavelengths and reported as mmol/mL[20].

2.11.2. Measurement of malondialdehyde (MDA) level, total antioxidant status (TAS), and nitric oxide synthase (NOS) and catalase (CAT) activities

Colorimetric assay kits (Randox Cat No: NX2332; Randox Laboratories Ltd., Crumlin, Antrim, United Kingdom) were used for measuring serum TAS level according to the manufacturer's recommendations using an ELISA reader (Biotek Instruments, USA) at the wavelength of 600 nm. The results were reported as mM/L. Briefly, this method is based on the bleaching of the color produced by a peroxidase (such as hydrogen peroxidase) and the conversion of unstable 2,2'-azino-di-(3-ethylbenzthiazoline sulphonate) radicals to stable ones upon the addition of antioxidants to serum samples. The ODs of samples were finally measured at 600 nm[21].

NOS catalyzes the production of NO from *L*-arginine and plays an important role in neurotransmission, vascular regulation, apoptosis, and immune and inflammation responses. NOS activity kit (colorimetric) (Abcam Cat No: ab211083; Abcam, Cambridge, MA, USA) was used for measuring the activity of NOS according to the manufacturer's instructions. Based on this colorimetric assay, the NO produced by NOS participates in a series of reactions with Griess reagents and generates a colored product. Its intensity was measured at 540 nm using an ELISA reader (Biotek Instruments, USA) and reported as U/mL[22].

ZellBio GmbH quantitative colorimetric kit (ZellBio GmbH Cat No: ZB-CAT-96A; ZellBio GmbH Laboratories Ltd, Germany) was used to determine serum CAT activity according to the manufacturer's instructions. Hydrogen peroxide (H₂O₂) is generated in cells by various oxidative reactions, and its accumulation causes the oxidation of cellular components including cell membrane lipids and DNA, leading to apoptosis. The CAT is an enzyme that detoxifies this compound by catalyzing H₂O₂ to water and oxygen. Briefly, in this two-step kit which contains H₂O₂, after the addition of a sample containing CAT, the enzyme was quenched with a quencher, and extra H₂O₂ reacted with a chromogen. Finally, the OD was read at 405 nm by an ELISA reader (Biotek Instruments, USA), and serum CAT activity was expressed as U/mL[23].

Spectrophotometric method was used to measure the amount of MDA level based on thiobarbituric acid (TBA) reactivity. Briefly, 150 μ L of TBA solution was added to 150 μ L of 30% trichloroacetic acid (Merck) and after centrifugation of the resulting solution (3000 rpm for 5 min), the supernatant was added to 200 μ L of 1% TBA (Merck) in a boiling water bath for 30 min and incubated for 10 min on an ice-cold water bath. The absorbance of the final solution was read at 532 nm at room temperature. The extent of lipid peroxidation was expressed as MDA (nmol/mL)[24].

2.12. Histopathological investigation

The liver and kidney tissues were fixed in 10% formalin, and by routine tissue processing, 5 μ m sections (with LEICA SM2010RV1.2 microtomes, Germany) were prepared from paraffin-embedded blocks and stained with either hematoxylin and eosin (H&E) for the liver or periodic acid–Schiff (PAS) for the kidney. Each section was examined at \times 100 magnification using a light microscopy system (Olympus IX71 microscope, Japan). Hepatic central venules and the portal triad (portal bile duct, artery, and vein), as well as renal glomeruli, tubules (proximal, distal, Henle, and collecting), and arteries were examined[20].

2.13. Statistical analysis

Graph Pad Prism version 8.0 for Windows (Graph Pad Software, San Diego, CA, USA) was used for drawing graphs. Statistical analysis was conducted in SPSS v. 16. The normality and homogeneity of the data were determined by the Kolmogorov-Smirnov test ($P > 0.05$), and one-way analysis of variance (ANOVA) was utilized to compare the differences of means between groups, followed by the Tukey's *post hoc* test. All results were expressed as mean \pm SD, and $P < 0.05$ indicated statistical significance.

2.14. Ethical statement

All the protocols were performed under the supervision of the Ethics Committee of Nanjing University of Traditional Chinese Medicine (Approval number: 20190800358) and were in line with the guidelines of the Animal Ethics Committee (NIH Publication 80-23, 1996).

3. Results

3.1. LC-ESI/MS analysis

Based on *m/z* (molecular weights [M–H]), the retention time of standard compounds in the negative ion mode, the count (mass-to-charge, $\times 10^4$) of expected polyphenolic compounds, and the peaks recorded in chromatogram (Supplementary Figure 1), a total of 25 major polyphenols (*i.e.* 25 peaks with an intensity of $> 5 \times 10^4$) were identified (Table 1).

3.2. Acute toxicity test (LD₅₀)

After monitoring the toxic effects of the *O. vulgare* extract on mice for 24 h, it was found that one mouse died after exposure to the dose of 4500 mg/kg, and no death or toxic signs were observed in the mice exposed to other doses. According to the results of this study, the LD₅₀ of *O. vulgare* extract was 3.67 g/kg, which means that the doses of less than 3670 mg/kg would have no toxic effects on mice

and could be used in experiments.

3.3. TPC, TFC, and antioxidant capacity of *O. vulgare* extract

The results showed that the TPC of the *O. vulgare* extract was (89.17 ± 2.19) mg GAE/g, and TFC was (75.16 ± 2.16) mg RE/g. The *O. vulgare* extract showed the antioxidant activity with (8920.15 ± 19.13) mmol Fe(II)/mg and (192.16 ± 4.61) μmol TE/10 g, respectively by FRAP and DPPH assays. These results indicated that the *O. vulgare* extract had a high antioxidant capacity, probably due to the presence of various polyphenolic compounds.

3.4. Effects of *O. vulgare* extract on the body, liver, and kidney weights in finasteride-treated mice

At the end of the study, it was found that finasteride significantly reduced the body weight ($P=0.023$) and increased the weights of the liver ($P=0.006$) and kidneys ($P=0.026$) in mice compared to the normal group. However, treatment with the *O. vulgare* extract restored the weights of the body and the organs in a dose-dependent manner. The group receiving 400 mg/kg of *O. vulgare* extract showed significant improvement in the weights of the body and the organs (Figure 1).

3.5. Effects of *O. vulgare* extract on biochemical parameters in finasteride-treated mice

Finasteride significantly increased the levels of all examined liver enzymes [ALT ($P=0.001$), AST ($P=0.004$), ALP ($P=0.016$), and

GGT ($P=0.008$)] compared to the normal group (Figure 2). However, a dose-dependent reduction was noticed in the liver enzymes after administration of *O. vulgare* extract (Figure 2A).

Moreover, finasteride significantly reduced serum levels of ALB ($P=0.016$) and TP ($P=0.006$) and also increased TB ($P=0.004$) compared to the normal group (Figure 2B). The *O. vulgare* extract treatment restored serum levels of ALB, TP, and TB towards normal (Figure 2B).

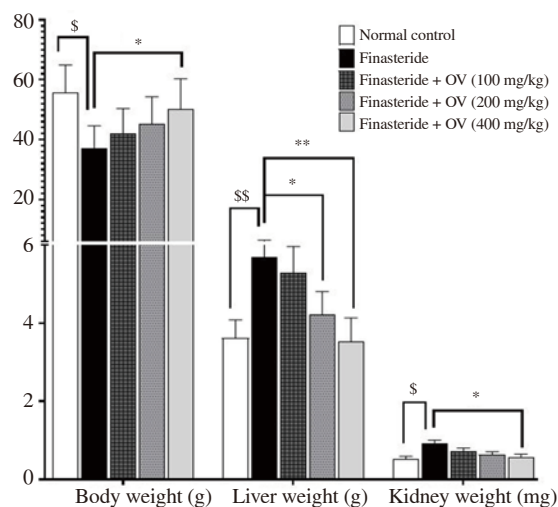


Figure 1. Body weight, and liver and kidney weight in different groups. The data are expressed as mean ± SD. $^{\$}P < 0.05$, $^{SS}P < 0.01$ compared with the normal group; $^*P < 0.05$ and $^{**}P < 0.01$ compared with the finasteride group. OV: *Origanum vulgare*.

Table 1. Qualitative evaluation of *Origanum vulgare* flavonoids based on LC-ESI/MS analysis.

Compounds	m/z	MS/MS fragments	Acquisition time	Counts (Mass-to-charge) × 10 ⁴
Cinnamic acid	149	149	1.72	4.8
3- <i>O</i> -(<i>Z</i>)- <i>p</i> -Coumaroylquinic acid		337		
Epigallocatechin		306		
Coumaric acid- <i>O</i> -pentoside	295	295	10.3	23.4
Kaempferol galloylglucoside		599		
Quercetin-3,7-diglucoside		625		
Kaempferol-3,7-di- <i>O</i> -glucoside	609	609	10.7	49.2
Quercetin-3-d-galactoside	463	463	10.92	234.6
Quercetin-3- <i>O</i> -galactoside		464		
Apigenin 7- <i>O</i> -glucuronide	445	445	12.6	6.8
Formononetin		267		
Genistein		268		
Daidzein 7- <i>O</i> -β- <i>D</i> -glucoside		417		
α-Tocopherol	501	501	12.7	7.8
Apigenin-7- <i>O</i> -glucoside	431	431	13.5	11.22
Biochanin A		283		
Malvidin	331	331	14.6	4.06
Gallocatechin		307		
Apigenin 6,8-diglucoside		593		
Daidzin 4'- <i>O</i> -glucuronide	592	592	15	5.36
Kaempferol-3- <i>O</i> -sophoroside-7- <i>O</i> -glucoside		777		
Coumaric acid- <i>O</i> -rhamnoside		309		
Paeoniflorin	480	480	17	6.52
Genistein 8- <i>C</i> -glucoside-xyloside		311		
Quercetin-3- <i>O</i> -pentoside		433		

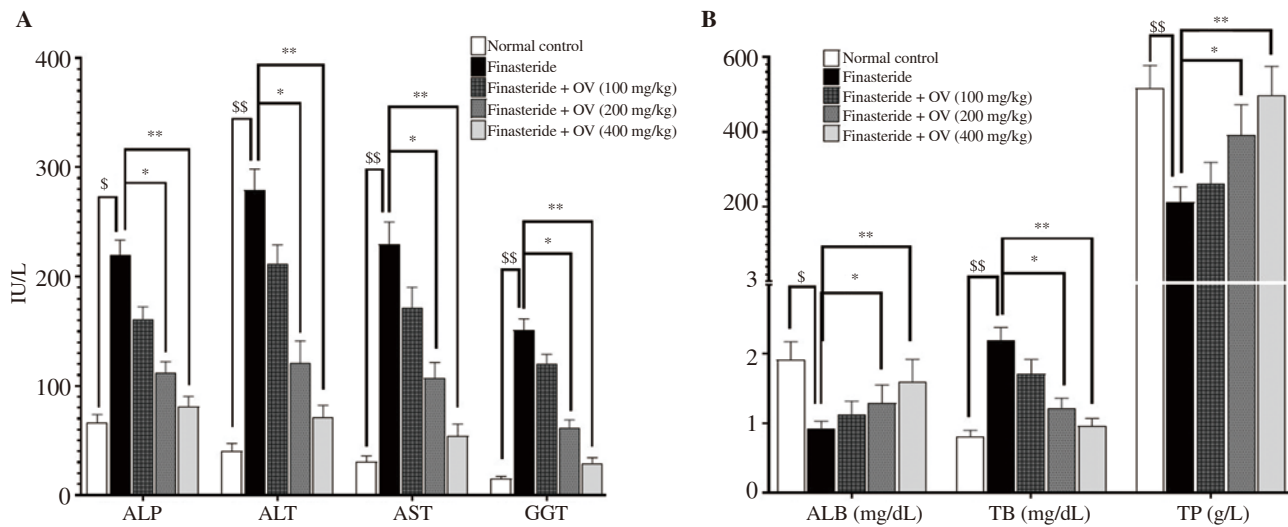


Figure 2. Serum activity of ALT, AST, ALP and GGT (A), and serum levels of ALB, TB and TP (B) after treatment with *Origanum vulgare* extract. The data are expressed as mean±SD. ^s $P < 0.05$, ^{ss} $P < 0.01$ compared with the normal group; * $P < 0.05$, ** $P < 0.01$ compared with the finasteride group. ALP: alkaline phosphatase; AST: aspartate aminotransferase; ALT: alanine aminotransferase; GGT: gamma-glutamyl transferase; ALB: albumin; TB: total bilirubin; TP: total protein.

3.6. Effects of *O. vulgare* extract on serum Cr, BUN, Na⁺, and K⁺ levels in finasteride-treated mice

Finasteride significantly increased serum BUN ($P=0.002$) and Cr ($P=0.004$) while reducing serum Na⁺ ($P=0.014$) and K⁺ ($P=0.008$) compared to the normal group (Figure 3). The *O. vulgare* extract improved serum levels of all these parameters in a dose-dependent manner, and 400 mg/kg of the extract markedly reduced finasteride-induced changes (Figure 3).

3.7. Effects of *O. vulgare* extract on serum levels of pro- and anti-inflammatory cytokines in finasteride-treated mice

Finasteride significantly increased the serum levels of pro-inflammatory cytokines [IFN- γ ($P=0.007$), IL-12 ($P=0.034$), IL-6 ($P=0.011$), TNF- α ($P=0.015$), and IL-1 β ($P=0.024$)] and reduced anti-inflammatory cytokine IL-10 ($P=0.014$) compared to the normal group (Figure 4A). On the other hand, *O. vulgare* extract at the dose of 400 mg/kg significantly reduced the serum levels of pro-inflammatory cytokines [IFN- γ ($P=0.007$), IL-6 ($P=0.002$), TNF- α ($P=0.006$), and IL-1 β ($P=0.009$)] and increased IL-10 level ($P=0.04$) compared to the finasteride-treated group (Figure 4A).

3.8. Effects of *O. vulgare* extract on serum CAT and NOS activities and NO, MDA, and TAS levels in finasteride-treated mice

Serum activities of CAT ($P=0.019$) and NOS ($P=0.021$) and the serum level of TAS ($P=0.011$) were significantly decreased in the finasteride group. Moreover, significant elevations were observed in the serum levels of NO ($P=0.002$) and MDA ($P=0.005$) in finasteride-exposed mice compared to the normal group (Figure 4B). However, *O. vulgare* extract improved the serum levels of these oxidative stress-related parameters dose-dependently (Figure 4B).

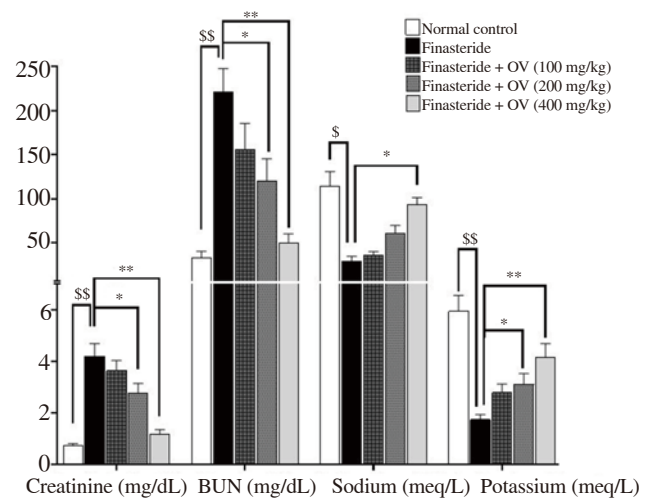


Figure 3. Serum levels of Cr, BUN, Na⁺ and K⁺ after treatment with *Origanum vulgare* extract. The data are expressed as mean±SD. ^s $P < 0.05$, ^{ss} $P < 0.01$ compared with the normal group; * $P < 0.05$, ** $P < 0.01$ compared with the finasteride group. Cr: creatinine; BUN: blood urea nitrogen.

3.9. Histopathological findings

Pyknotic heterochromatin in the nuclei and the cytoplasm filled with eosinophilic granules were seen in the liver of finasteride-treated mice. Also, around the liver central venules and portal triad, dense lymphocytic infiltration was observed. The destruction of hepatocytes inhibited the bile and blood flow into sinusoidal spaces. Swelling, obstruction, and congestion were also seen in central venules (Figure 5 A1 & A2). Treatment with *O. vulgare* extract improved the hexagonal structure of hepatic lobules and cytoplasmic structure of hepatocyte. There were no lymphocytic infiltrations, congestion, and obstruction around the central venules (Figure 5B-D).

In the kidney, finasteride increased lymphocytic infiltrations around arteries and glomeruli, destructed the normal architecture of renal

tissue, and finally induced necrosis in cortical and medullary renal tubules. Finasteride also damaged renal physiological function and resulted in congestion and hyperemia in renal arteries (Figure 6 A1 & A2). However, *O. vulgare* extract protected the renal tissue and preserved the normal histological structure. The extract also reduced lymphocytic infiltration, congestion, and hyperemia in renal arteries

(Figure 6B-D).

4. Discussion

The present study investigated the potential protective effects of *O.*

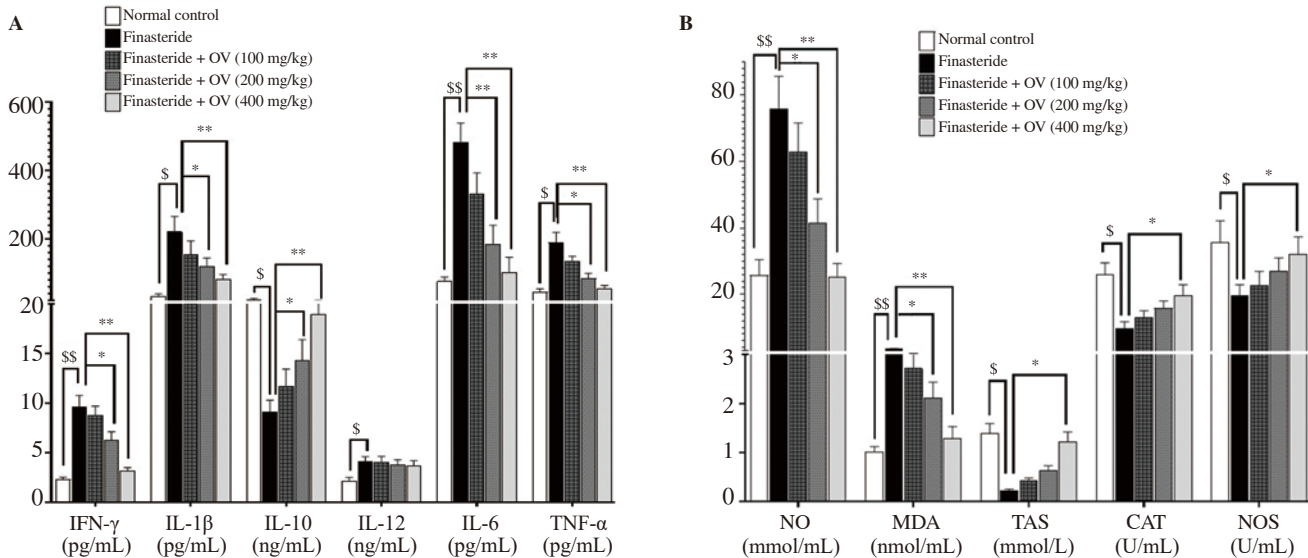


Figure 4. Effect of *Origanum vulgare* extract on oxidative stress and inflammatory cytokines in finasteride-exposed mice. (A) Serum levels of cytokines including IFN- γ , IL-6, TNF- α , IL-1 β , IL-10, and IL-12. (B) Serum levels of CAT, NOS, NO, TAS, and MDA. The data are expressed as mean \pm SD. $^{\$}P < 0.05$, $^{**}P < 0.01$ compared with the normal group; $^{*}P < 0.05$, $^{**}P < 0.01$ compared with the finasteride group. CAT: catalase; TAS: total antioxidant status; NOS: nitric oxide synthase; MDA: malondialdehyde; NO: nitric oxide; IFN- γ : interferon- γ ; IL-6: interleukin-6; TNF- α : tumor necrosis factor- α ; IL-1 β : interleukin-1 β ; IL-10: interleukin-10; IL-12: interleukin-12.

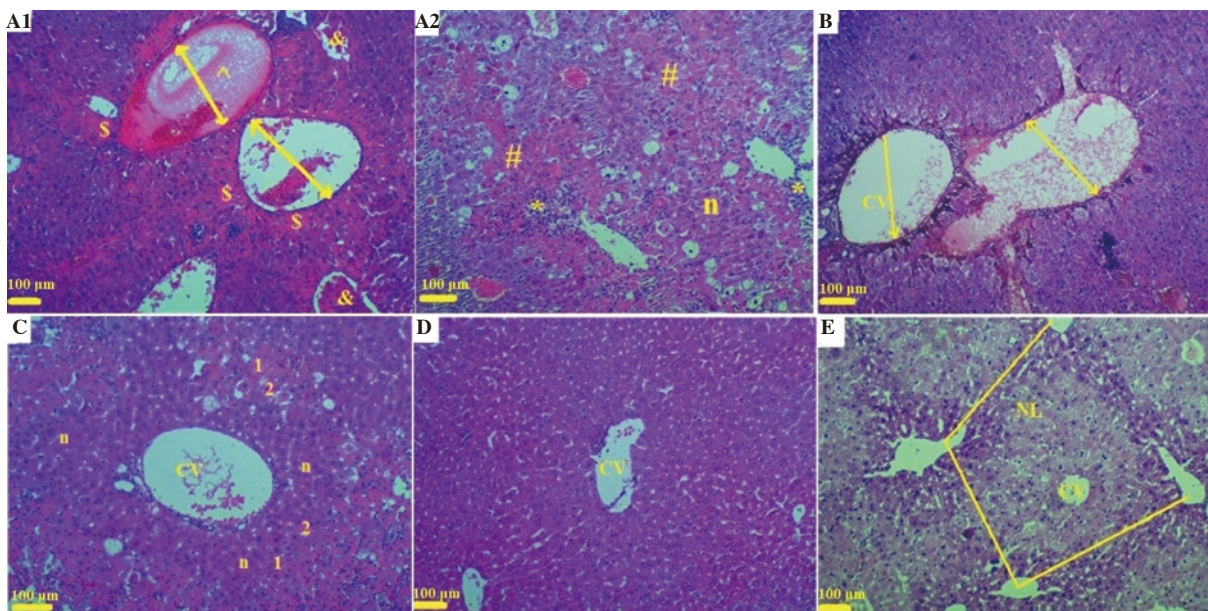


Figure 5. Histopathological results of the liver in mice. (A1-A2) The finasteride group shows parenchymal inflammation (*), hepatocellular necrosis (#), and sinusoidal obstruction (\$). Endothelial injuries in small hepatic venules (&) lead to endothelial swelling, thrombosis, and luminal occlusion (^). (A2 & C) Sinusoidal dilatation and congestion, as well as the destruction of hepatocytes' nuclei and some necrotic hepatocytes with the basophilic (1) and residual eosinophilic (2) bodies filled with granules are seen. (B, C and D) The treatment groups (100, 200 and 400 mg/kg/day of *Origanum vulgare* extract) show improved structure of the liver, which is more pronounced at the dose of 400 mg/kg. Hepatocytes have a normal structure (without eosinophilic granules). No congestion and obstruction of the central venule or lymphocyte infiltration is observed. (E) The normal group shows the normal structure of the hepatocytes, central venules, and liver arteries. n: normal hepatocytes; 1: basophilic hepatocytes; 2: eosinophilic hepatocytes; CV: central venule and NL: normal lobule [A1, A2, B, C, D, and E, H&E $\times 100$ (scale bar = 100 μ m)].

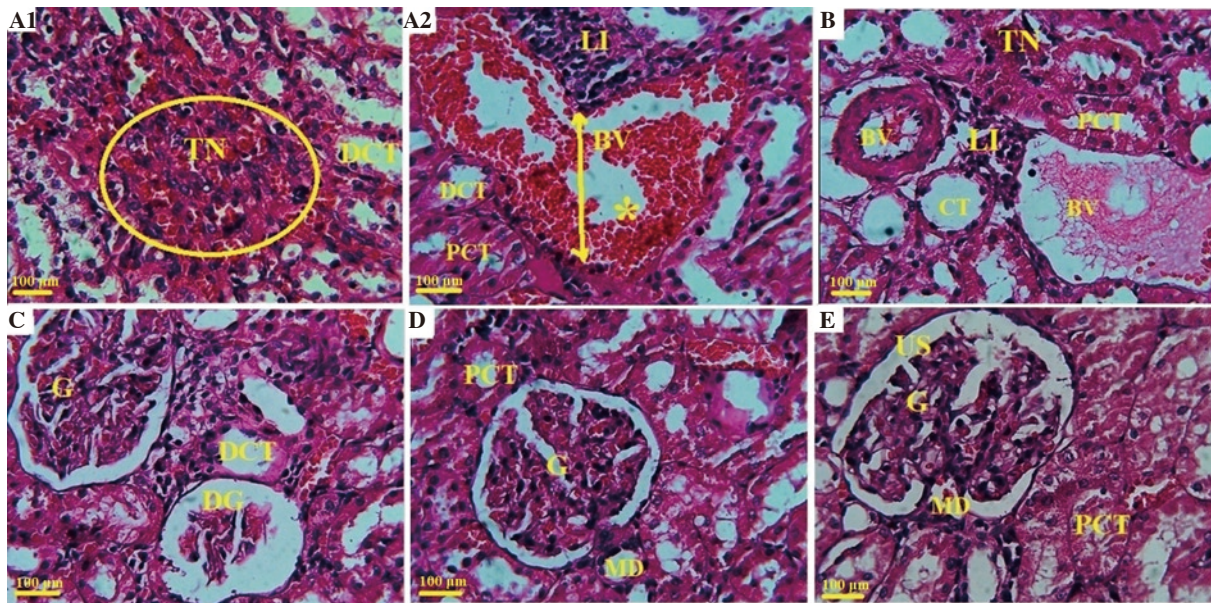


Figure 6. Histopathological results of the kidney in mice. (A1-A2) The finasteride group shows hyperemia in the renal arteries (*) and tubular necrosis (TN) in PCT and DCT in the glomeruli, and lymphocytic infiltration (LI) between the tubules. (B, C and D) The treatment groups (100, 200 and 400 mg/kg/day of *Origanum vulgare* extract) show improved structure of the liver, which is more pronounced at the dose of 400 mg/kg. No tubular necrosis, lymphocyte infiltration, and vascular hyperemia are observed. (E) The normal group shows the normal structure of the tubules, glomeruli, and renal arteries. G: normal glomerulus; BV: blood vessel; PCT: proximal convoluted tubule; DCT: distal convoluted tubule; US: urinary space; DG: glomerular degeneration; CT: collecting tubules; MD: macula densa [A1, A2, B, C, D, and E, PAS×100, (scale bar = 100 μm)].

vulgare extract against finasteride-induced liver and kidney injuries. As biochemical and histopathological examinations showed, *O. vulgare* extract effectively improved the structural and functional defects observed in the liver and kidney of finasteride-treated mice.

In the present study, 25 mg/kg of finasteride had adverse effects on biochemical parameters and histological structure of mouse liver and kidneys. Previous studies revealed that high (5 and 25 mg/kg/day and higher) or low (1 mg/kg/day) doses of finasteride increased the production of reactive oxygen species (ROS) and caused oxidative stress[25,26]. ROS then induced destructive effects *via* activating apoptotic pathways (*i.e.* ROS-mediated activation of GRP-78, p-IRE1, p-JNK, procaspase-3, p53, and caspase-3) in hepatocytes and epithelial cells of renal proximal convoluted tubule and distal convoluted tubule[27]. In this study, CAT and NOS activities were significantly reduced in finasteride-treated animals, which was in agreement with previous reports. Although apoptosis was not directly determined in the present research, remarkable apoptotic changes were observed in histopathological evaluation of the liver and kidney. Finasteride triggered kidney damage such as glomerulosclerosis, tubulointerstitial fibrosis, and infiltration of mononuclear cells *via* affecting androgen homeostasis and reducing androgen receptor expression[5,25]. On the other hand, androgen receptor has been described as a factor responsible for the deterioration of renal function[7].

Plants with anti-inflammatory, antioxidant, and anti-apoptotic properties inhibit the production of inflammatory cytokines and ROS and thereby protect hepatic and renal parenchymal cells

against the damage caused by these factors and ultimately maintain their physiological function[28,29]. Protecting hepatocytes and renal tubular epithelial cells against damages on DNA and other cellular components that were induced by chemical drugs and toxins is attributed to the presence of phytochemicals such as flavonoids which have anti-oxidative and anti-inflammatory properties[30]. ROS results in oxidative stress accompanied by various injuries to tissues and organs, especially the liver[31], which was found in the current study. A previous study showed that treatment with *O. vulgare* extract prevented the increase of liver enzymes[32], which is in agreement with our results. In this study, treatment with *O. vulgare* leaf extract not only significantly decreased serum ALT, AST, and ALP but also prevented liver damage in finasteride-exposed mice. Moreover, *O. vulgare* extract normalized the increased levels of inflammatory cytokines and suppressed finasteride-induced oxidative stress. Our findings also indicated that *O. vulgare* promoted antioxidant activities by enhancing antioxidant enzymatic storage. Furthermore, *O. vulgare* extract with its antioxidant properties inhibited lipid peroxidation as evidenced by decreased levels of MDA and inflammatory cytokines. A previous study showed that *O. vulgare* leaf extract was rich in rosmarinic acid, caffeic acid, and other phenolic compounds such as flavonoids, which could inhibit lipid peroxidation[33].

Based on the results of this study, the significant elevation in the levels of pro-inflammatory cytokines including IFN- γ , IL-12, IL-6, TNF- α , and IL-1 β was accompanied by tissue infiltration by immune cells. It has been reported that T cells and macrophages express testosterone-binding sites[34], and macrophages also demonstrate

5 α -reductase activity similar to finasteride[35]. Thus, androgens could have directly affected immune cells (especially T and B lymphocytes) and contributed to the tissue infiltration. Besides, sex hormones not only control renal hemodynamics, mesangial cell proliferation, and extracellular matrix metabolism, but also affect the synthesis and release of some cytokines and other growth factors, which in turn affect the progression of renal diseases[36]. Furthermore, humoral and cellular immune responses are considered to be regulated by sex hormones[35]. Therefore, an impaired sex hormones ratio in finasteride-treated animals can directly modulate the function of immune cells and the production of pro-inflammatory factors. It has been shown that finasteride can induce apoptosis in hepatic and renal cells *via* increasing the secretion of inflammatory cytokines through c-Jun amino-terminal kinase pathways[37,38]. Therefore, the adverse effects of finasteride can be partly attributed to the inhibition of testosterone-dihydrotestosterone conversion, leading to impaired androgen/estrogen homeostasis and eventually characteristic pathomorphological and functional changes.

In the current study, finasteride-induced toxicity was associated with increased levels of TNF- α and NO, indicating intensified inflammatory and oxidative stress processes, respectively. On the other hand, the levels of these mediators were diminished significantly in the animals receiving *O. vulgare* extract compared to control groups. These findings were consistent with the results of similar studies[39,40]. Decline in the serum levels of TNF- α and NO proved that the nephroprotective and hepatoprotective effects of *O. vulgare* extract might be partly due to its high antioxidant capacity (as shown in DPPH and FRAP assays). These results were also in line with previous reports. Sharifi-Rigi *et al.* reported that the oral administration of *O. vulgare* extract increased renal superoxide dismutase and CAT activities and decreased serum level of MDA and the gene expression of TNF- α in rat models of paraquat-induced nephrotoxicity[41]. In another study, *O. vulgare* extract protected the liver against paraquat-induced hepatotoxicity in rats partly by scavenging free radicals and improving hepatic structure and function[42]. In histopathological study, we observed mononuclear cell infiltration and fibrosis around renal atrophic lesions. It has been reported that T cells can express TGF- β and directly induce adjacent tubular epithelial cells to transform into proliferating fibroblasts that migrate across the tubular basement membrane and generate fibrotic lesions in the renal interstitium[43].

In line with the results of other studies, LC-ESI/MS analysis showed that *O. vulgare* hydroalcoholic extract contained flavonoids such as quercetin, apigenin, genistein, α -tocopherol, kaempferol, coumaric acid, epigallocatechin, and daidzein, some of which have potent antioxidant properties, and others are effective in reinforcing the hypothalamic-pituitary-gonadal axis. Studies have shown that some polyphenolic compounds of *O. vulgare* extract, such as apigenin[44], quercetin[45], and ferulic acid[46], regulate the secretion of testosterone from Leydig cells and protect Sertoli cells and the

spermatogenic lineage against ROS destructive effects, which can reduce the release of inflammatory cytokines from damaged cells and ultimately maintain the structure of tissues and cells.

In conclusion, the present study showed that the hydroalcoholic extract of *O. vulgare* prevented the nephrotoxic and hepatotoxic effects induced by finasteride. We also demonstrated that these protective effects were executed through the antioxidant and anti-inflammatory properties of the extract. This plant can be used to improve tissue injuries in patients with kidney and liver problems. It is recommended to purify the effective compounds of this plant and investigate their therapeutic effects in drug discovery studies.

There were some limitations in the current study. Pro-apoptotic and anti-apoptotic factors including NF- κ B, Bax, p53, and Bcl-2 were not assessed in the present study. Therefore, it is advisable to investigate the possible anti-apoptotic properties of *O. vulgare* leaf extract in future studies to further understand its mechanisms of action.

Conflict of interest statement

The authors declare that there is no conflict of interest.

Acknowledgments

The authors extend their appreciation to the Deanship of Scientific Research at King Khalid University, Abha, KSA for funding this work through Research Group Project under grant number R.G.P.2/80/41 and also Wuxi Municipal Health and Family Planning Commission (WXQ201832).

Funding

This work was financially supported by King Khalid University, Abha, KSA through Research Group Project under grant number R.G.P.2/80/41 and Wuxi Municipal Health and Family Planning Commission (WXQ201832).

Authors' contributions

QFS, SXC, AE, and HK designed and conducted the experiment, and performed data analysis. ZFT and YYS contributed to manuscript writing and performing experimental study. FJ, HTW, AE, HK, and ZYD participated in definition of intellectual content, literature search, statistical analysis, and manuscript preparation. AE got the research fund and DM performed language editing. All the authors reviewed the data, read, and approved the manuscript.

References

- [1] Fukuzumi H, Ikeda T, Narita H, Takubo T, Matsuda T, Taniguchi T. Pharmacological and clinical profile of finasteride (PROPECIA). *Nihon Yakurigaku Zasshi* 2006; **127**(6): 495-502.
- [2] Libecco JF, Bergfeld WF. Finasteride in the treatment of alopecia. *Expert Opin Pharmacother* 2004; **5**(4): 933-940.
- [3] Ioannidis PA. Finasteride toxicity information: “limited”, “poor quality”, “biased”. *React Wkly* 2015; **1547**: 9-18.
- [4] Alkahtane AA, Albasher G, Al-Sultan NK, Alqahtani WS, Alarifi S, Almeer RS, et al. Long-term treatment with finasteride induces apoptosis and pathological changes in female mice. *Hum Exp Toxicol* 2019; **38**(7): 762-774.
- [5] Baig MS, Kolasa-Wołoskiuk A, Pilutin A, Safranow K, Baranowska-Bosiacka I, Kabat-Koperska J, et al. Finasteride-induced inhibition of 5 α -reductase type 2 could lead to kidney damage—animal, experimental study. *Int J Environ Res Public Health* 2019; **16**(10): 1726.
- [6] Liang L, Li L, Tian J, Lee SO, Dang Q, Huang CK, et al. Androgen receptor enhances kidney stone-CaOx crystal formation *via* modulation of oxalate biosynthesis & oxidative stress. *Mol Endocrinol* 2014; **28**(8): 1291-1303.
- [7] Guan Y. Nuclear receptors link gender dimorphism of renal disease progression. *Kidney Int* 2006; **70**(11): 1889-1890.
- [8] Bahmani M, Khaksarian M, Rafieian-Kopaei M, Abbasi N. Overview of the therapeutic effects of *Origanum vulgare* and *Hypericum perforatum* based on Iran’s ethnopharmacological documents. *J Clin Diag Res* 2018; **12**(7): FE01-FE04.
- [9] Akbari Bazm M, Khazaei M, Khazaei F, Naseri L. *Nasturtium officinale* L. hydroalcoholic extract improved oxymetholone-induced oxidative injury in mouse testis and sperm parameters. *Andrologia* 2019; **51**(7): e13294.
- [10] Habibi E, Shokrzadeh M, Ahmadi A, Chabr A, Naghshvar F, Keshavarz-Maleki R. Genoprotective effects of *Origanum vulgare* ethanolic extract against cyclophosphamide-induced genotoxicity in mouse bone marrow cells. *Pharm Biol* 2015; **53**(1): 92-97.
- [11] Chen X, Feng H, El-kott AF, Abd-Ella EM. *Origanum vulgare* L. leaves extract alleviates testis and sperm damages induced by finasteride: Biochemical, Immunohistological and apoptosis genes based evidences. *Andrologia* 2020. Doi: 10.1111/and.13823.
- [12] Ighodaro OM, Akinloye OA. *Sapium ellipticum* (Hochst.) Pax leaf extract: *In-vitro* antioxidant activities and lethal dose (LD₅₀) determination in Wistar rats. *J Adv Med Med Res* 2016; **29**: 1-7.
- [13] Yaldiz G. Effects of potassium sulfate [K₂SO₄] on the element contents, polyphenol content, antioxidant and antimicrobial activities of milk thistle [*Silybum marianum*]. *Pharmacogn Mag* 2017; **13**(49): 102-107.
- [14] Miliuskas G, Venskutonis PR, Van Beek TA. Screening of radical scavenging activity of some medicinal and aromatic plant extracts. *Food Chem* 2004; **85**(2): 231-237.
- [15] Yang B, Zhao M, Shi J, Yang N, Jiang Y. Effect of ultrasonic treatment on the recovery and DPPH radical scavenging activity of polysaccharides from longan fruit pericarp. *Food Chem* 2008; **106**(2): 685-690.
- [16] Ghanbari E, Khazaei MR, Ahangar P, Khazaei M. Crab shell extract improves sperm parameters and antioxidant status in testes of diabetic rats. *J Diet Suppl* 2019; **16**(2): 215-226.
- [17] Zin SR, Omar SZ, Khan NL, Musameh NI, Das S, Kassim NM. Effects of the phytoestrogen genistein on the development of the reproductive system of Sprague Dawley rats. *Clinics* 2013; **68**(2): 253-262.
- [18] Bazm MA, Khazaei M, Ghanbari E, Naseri L. Protective effect of *Vaccinium arctostaphylos* L. fruit extract on gentamicin-induced nephrotoxicity in rats. *Com Clin Pathol* 2018; **27**(5): 1327-1334.
- [19] Palová-Jelínková L, Dáňová K, Drašarová H, Dvořák M, Funda DP, Fundová P, et al. Pepsin digest of wheat gliadin fraction increases production of IL-1 β *via* TLR4/MyD88/TRIF/MAPK/NF- κ B signaling pathway and an NLRP3 inflammasome activation. *PLoS One* 2013; **8**(4): e62426.
- [20] Naseri L, Khazaei M, Ghanbari E, Bazm MA. *Rumex alveollatus* hydroalcoholic extract protects CCl₄-induced hepatotoxicity in mice. *Com Clin Pathol* 2019; **28**(2): 557-565.
- [21] Budiman I, Tjokropranoto R, Widowati W, Fauziah N, Erawijantari PP. Potency of turmeric (*Curcuma longa* L.) extract and curcumin as anti-obesity by inhibiting the cholesterol and triglycerides synthesis in HepG2 cells. *Int J Res Med Sci* 2015; **3**(5): 1165-1171.
- [22] Lee I, Kim S, Nagar H, Choi SJ, Jeon BH, Piao S, et al. CR6-interacting factor 1 deficiency reduces endothelial nitric oxide synthase activity by inhibiting biosynthesis of tetrahydrobiopterin. *Sci Rep* 2020; **10**(1): 1-3.
- [23] Pezeshk F, Babaei S, Abedian Kenari A, Hedayati M, Naseri M. The effect of supplementing diets with extracts derived from three different species of macroalgae on growth, thermal stress resistance, antioxidant enzyme activities and skin colour of electric yellow cichlid (*Labidochromis caeruleus*). *Aquac Nutr* 2019; **25**(2): 436-443.
- [24] Bhutia Y, Ghosh A, Sherpa ML, Pal R, Mohanta PK. Serum malondialdehyde level: Surrogate stress marker in the Sikkimese diabetics. *J Nat Sc Biol Med* 2011; **2**(1): 107.
- [25] McConnell JD, Bruskewitz R, Walsh P, Andriole G, Lieber M, Holtgrewe HL, et al. The effect of finasteride on the risk of acute urinary retention and the need for surgical treatment among men with benign prostatic hyperplasia. *N Engl J Med* 1998; **338**(9): 557-563.
- [26] Hirshburg JM, Kelsey PA, Therrien CA, Gavino AC, Reichenberg JS. Adverse effects and safety of 5-alpha reductase inhibitors (finasteride, dutasteride): A systematic review. *J Clin Aesthet Dermatol* 2016; **9**(7): 56.
- [27] Chen Y, Feng X, Hu X, Sha J, Li B, Zhang H, et al. Dexmedetomidine ameliorates acute stress-induced kidney injury by attenuating oxidative stress and apoptosis through inhibition of the ROS/JNK signaling pathway. *Oxid Med Cell Longev* 2018; **2018**: 4035310.
- [28] Zhu G, Liang L, Li L, Dang Q, Song W, Yeh S, et al. The expression and evaluation of androgen receptor in human renal cell carcinoma. *Urology* 2014; **83**(2): e19-e24.
- [29] Abouzeinab NS. Antioxidant effect of silymarin on cisplatin-induced renal oxidative stress in rats. *J Pharmacol Toxicol* 2015; **10**(1): 1-19.
- [30] Khan MI. Plant betalains: Safety, antioxidant activity, clinical efficacy, and bioavailability. *Compr Rev Food Sci Food Safety* 2016; **15**(2): 316-

- 330.
- [31]Sun Y, Zhang J, Yan Y, Chi M, Chen W, Sun P, et al. The protective effect of c-phycocyanin on paraquat-induced acute lung injury in rats. *Environ Toxicol Pharmacol* 2011; **32**(2): 168-174.
- [32]Sikander M, Malik S, Parveen K, Ahmad M, Yadav D, Bin-Hafeez Z, et al. Hepatoprotective effect of *Origanum vulgare* in Wistar rats against carbon tetrachloride-induced hepatotoxicity. *Protoplasma* 2013; **250**(2): 483-493.
- [33]Zhang XL, Guo YS, Wang CH, Li GQ, Xu JJ, Chung HY, et al. Phenolic compounds from *Origanum vulgare* and their antioxidant and antiviral activities. *Food Chem* 2014; **152**: 300-306.
- [34]Tomaszewska K, Kozłowska M, Kaszuba A, Lesiak A, Narbutt J, Zalewska-Janowska A. Increased serum levels of IFN- γ , IL-1 β , and IL-6 in patients with alopecia areata and nonsegmental vitiligo. *Oxid Med Cell Longev* 2020; **3**: 2020.
- [35]Chaiyana W, Punyoyai C, Somwongin S, Leelapornpisid P, Ingkaninan K, Waranuch N, et al. Inhibition of 5 α -reductase, IL-6 secretion, and oxidation process of *Equisetum debile* Roxb. ex vaucher extract as functional food and nutraceuticals ingredients. *Nutrients* 2017; **9**(10): 1105.
- [36]de Melo Junior AF, Dalpiaz PL, da Silva Escouto L, Sousa GJ, Aires R, Oliveira ND, et al. Involvement of sex hormones, oxidative stress, ACE and ACE2 activity in the impairment of renal function and remodeling in SHR. *Life Sci* 2020; **23**: 118138.
- [37]Huskey SW, Dean DC, Miller RR, Rasmusson GH, Chiu SH. Identification of human cytochrome P450 isozymes responsible for the *in vitro* oxidative metabolism of finasteride. *Drug Metab Dispos* 1995; **23**(10): 1126-1135.
- [38]Verzola D, Villaggio B, Procopio V, Gandolfo MT, Gianiorio F, Famà A, et al. Androgen-mediated apoptosis of kidney tubule cells: Role of c-Jun amino terminal kinase. *Biochem Biophys Res Commun* 2009; **387**(3): 531-536.
- [39]Kubatka P, Kello M, Kajo K, Kruzliak P, Výbohá D, Mojžiš J, et al. *Oregano* demonstrates distinct tumour-suppressive effects in the breast carcinoma model. *Eur J Nutr* 2017; **56**(3): 1303-1316.
- [40]Mirzaei A, Maleki R, Ghavamizadeh M. Nephro-protective effects of *Origanum vulgare* hydroalcoholic extract against gentamicin-induced nephrotoxicity in rats. *Int Med J* 2016; **23**: 26-29.
- [41]Sharifi-Rigi A, Heidarian E. Therapeutic potential of *Origanum vulgare* leaf hydroethanolic extract against renal oxidative stress and nephrotoxicity induced by paraquat in rats. *Avicenna J Phytomed* 2019; **9**(6): 563-573.
- [42]Sharifi-Rigi A, Heidarian E, Amini SA. Protective and anti-inflammatory effects of hydroalcoholic leaf extract of *Origanum vulgare* on oxidative stress, TNF- α gene expression and liver histological changes in paraquat-induced hepatotoxicity in rats. *Arch Physiol Biochem* 2019; **125**(1): 56-63.
- [43]Robertson H, Ali S, McDonnell BJ, Burt AD, Kirby JA. Chronic renal allograft dysfunction: The role of T cell-mediated tubular epithelial to mesenchymal cell transition. *J Am Sci Nephrol* 2004; **15**: 390-397.
- [44]Li W, Pandey AK, Yin X, Chen JJ, Stocco DM, Grammas P, et al. Effects of apigenin on steroidogenesis and steroidogenic acute regulatory gene expression in mouse Leydig cells. *J Nutr Biochem* 2011; **22**(3): 212-218.
- [45]Kanter M, Aktas C, Erboga M. Protective effects of quercetin against apoptosis and oxidative stress in streptozotocin-induced diabetic rat testis. *Food Chem Toxicol* 2012; **50**(3-4): 719-725.
- [46]Thyagaraju BM. Ferulic acid supplements abrogate oxidative impairments in liver and testis in the streptozotocin-diabetic rat. *Zoolog Sci* 2008; **25**(8): 854-860.

Origanum vulgare L. leaf extract alleviates finasteride-induced oxidative stress in mouse liver and kidney

Qi-Feng Sun¹, Shi-Xiang Chen², Zhang-Feng Tang³, Xiao-Yi Song³, Fa Jing³, Hao-Tian Wu³, Zhong-Yang Ding^{3*}, Attalla El-kott^{4,5}, Diao Massoud^{6,7}, Heba Khalifa⁵

¹Department of Hepatobiliary and Vascular Surgery, Jinan City People's Hospital, Jinan, Shandong Province, 271100, China

²Department of Hepatology, Zhejiang University Ming Zhou Hospital, Ningbo, Zhejiang Province, 15199, China

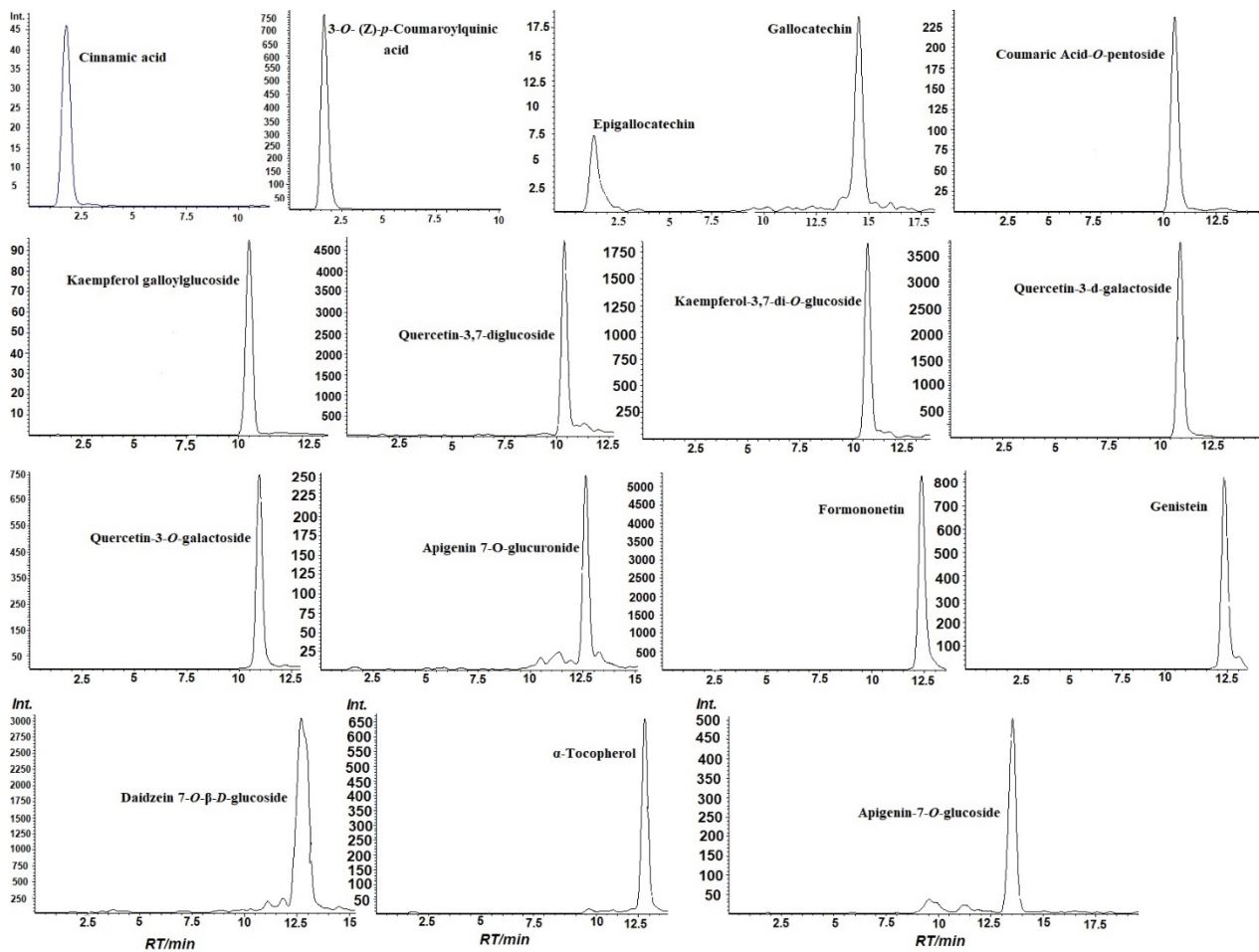
³Department of General Surgery, Wuxi Traditional Chinese Medicine Hospital Affiliated to Nanjing University of Traditional Chinese Medicine, Wuxi, Jiangsu Province, 214023, China

⁴Biology Department, College of Science, King Khalid University, Abha, Saudi Arabia

⁵Zoology Department, College of Science, Damanhour University, Damanhour, Egypt

⁶Biology Department, College of Science, Jouf University, P.O. Box 2014, Sakaka, Al-Jouf, Saudi Arabia

⁷Zoology Department, Faculty of Science, Fayoum University, Fayoum, Egypt



Supplementary figure 1. LC-ESI/MS metabolite fingerprints of *O. vulgare* using an ion trap analyzers operated in the negative ion mode [Intensity (104) with counts vs. mass to charge (m/z)].