

## The accuracy of cone-beam computed tomography in the detection of the number of root canals: An in vitro study

Masoumeh Mohsen pourian<sup>1</sup>, Azin Alasvand Javadi<sup>2</sup>, Mohammad Yazdizadeh<sup>3</sup>✉

1. Dental Student, Department of Endodontics, Faculty of Dentistry, Ahvaz Jundishapur University of Medical Sciences, Ahvaz, IR Iran.
2. General Dentist, Researcher, Ahvaz, IR Iran
3. Assistant Professor, Department of Endodontics, Faculty of Dentistry, Ahvaz Jundishapur University of Medical Sciences, Ahvaz, IR Iran.

✉**Corresponding Author:** Mohammad Yazdizadeh, Faculty of Dentistry, Ahvaz Jundishapur University of Medical Sciences, Ahvaz, IR Iran.

**Email:** yazdizadeh-m@ajums.ac.ir

**Tel:** +986133377181

**ORCID** (0000-0003-2827-1913)

Received: 8 Sept 2020

Accepted: 28 Mar 2021

### Abstract

**Introduction:** Effective endodontic treatment requires identification of all root canals. The inability of dentists to locate all root canals can lead to failure in endodontic treatment. Consequently, an accurate diagnostic device is essential to detect all root canals. The aim of this study was to examine the accuracy of cone-beam computed tomography (CBCT) as a diagnostic tool to detect the root canals of maxillary first premolars in a selected Iranian population.

**Material & Methods:** In this in vitro study, 48 human extracted maxillary first premolar teeth were scanned by CBCT, and then all teeth were sectioned. In the current study, sectional method was chosen as the gold standard. The CBCT scans were observed by an oral and maxillofacial radiologist, and the sections were evaluated by an endodontist using stereomicroscope. Finally, the collected data were entered into SPSS- 22 and analyzed by Kappa coefficient and Chi-square test. Significance level was set at 0.05.

**Results:** The agreement between CBCT and sectional methods for root canal detection was 97.2% which was significant (95.8% in the first section, 97.9% in the second and third sections), ( $p < 0.001$ ).

**Conclusion:** It seems that CBCT is a safe and non-invasive tool that can be used to detect root canals if other low-dose radiation imaging techniques do not provide acceptable results.

**Keywords:** Cone-beam computed tomography, Root canal, Premolar, Tooth root

**Citation for article:** Mohsen pourian M, Alasvand Javadi A, Yazdizadeh M. The accuracy of cone-beam computed tomography in the detection of the number of root canals: An in vitro study. Caspian J Dent Res 2021; 10:57-63.

## بررسی دقت توموگرافی کامپیوتری با اشعه مخروطی در تشخیص تعداد کانال های ریشه: یک مطالعه آزمایشگاهی

معصومه محسن پوریان<sup>۱</sup>، آذین علاسوند جوادی<sup>۲</sup>، محمد یزدیزاده<sup>۳\*</sup>

۱. دانشجوی دندانپزشکی، گروه اندودونتیکس، دانشکده دندانپزشکی، دانشگاه علوم پزشکی جندی شاپور اهواز، اهواز، ایران.

۲. دندانپزشک عمومی، محقق، اهواز، اهواز، ایران.

۳. استادیار، گروه اندودونتیکس، دانشکده دندانپزشکی، دانشگاه علوم پزشکی جندی شاپور اهواز، اهواز، ایران.

\* نویسنده مسئول: محمد یزدی زاده، دانشکده دندانپزشکی، دانشگاه علوم پزشکی جندی شاپور اهواز، اهواز، ایران.

پست الکترونیکی: yazdizadeh-m@ajums.ac.ir    تلفن: +۹۸۶۱۳۳۳۷۷۱۸۱

### چکیده

**مقدمه:** درمان کارآمد ریشه دندان نیاز به شناسایی کلیه کانال های ریشه دارد. عدم توانایی دندانپزشکان در یافتن کلیه کانالهای ریشه می تواند منجر به عدم موفقیت در درمان ریشه شود. در نتیجه، ضرورت وجود یک دستگاه تشخیصی دقیق برای تشخیص کلیه کانالهای ریشه ملموس است. هدف از مطالعه حاضر بررسی دقت توموگرافی کامپیوتری با اشعه مخروطی به عنوان ابزاری تشخیصی در تشخیص کانالهای ریشه در دندانهای پره مولر اول فک بالا در یک جمعیت منتخب ایرانی بود.

**مواد و روش ها:** در این مطالعه آزمایشگاهی ۴۸ دندان کشیده شده پرمولر فک بالای انسان توسط CBCT اسکن و سپس همه دندانها برش داده شدند. در این مطالعه روش سکشنال به عنوان استاندارد طلایی انتخاب شد. اسکن های CBCT توسط رادیولوژیست دهان، فک و صورت مشاهده شد و سکشن ها با استفاده از استریومیکروسکوپ توسط متخصص ریشه ارزیابی شدند. سپس داده های جمع آوری شده وارد نرم افزار SPSS-22 و با استفاده از ضریب کاپا و آزمون مجذور کای مورد تجزیه و تحلیل قرار گرفتند. سطح معناداری ۰/۰۵ تعیین شد.

**یافته ها:** درصد توافق بین روش CBCT و روش سکشنال برای تشخیص کانال ریشه ۹۷/۲٪ بود که (در بخش اول ۹۵/۸ درصد، در بخش دوم و سوم ۹۷/۹ درصد) معنا دار میباشد ( $p < 0.001$ ).

**نتیجه گیری:** به نظر میرسد CBCT ابزاری مطمئن و غیر تهاجمی است که میتواند در تشخیص کانال های ریشه در صورتیکه سایر روشهای تصویر برداری تابشی با دوز پایین نتایج قابل قبولی ارائه ندهند مورد استفاده قرار گیرد.

**واژگان کلیدی:** توموگرافی کامپیوتری با اشعه مخروطی، کانال ریشه، پره مولر، ریشه دندان

### Introduction

There are anatomical variations in all types of teeth.<sup>[1]</sup> Many dentists assume that a given tooth has a fixed number of roots or root canals.<sup>[2]</sup> A precise assessment of the published papers; however, illustrates that variation in root anatomy is common. In-depth knowledge of the internal and external features of the root can shrink the chances of not finding a canal during root canal treatment, increasing the success rate of root canal treatment.<sup>[3]</sup> Prior to the start of root canal treatment, several periapical radiographs are usually taken from different angles to determine the number of root canals.<sup>[4,5]</sup> Multiple periapical radiographs are needed since these radiographs provide a two-dimensional image of a complex three-dimensional

anatomy.<sup>[6]</sup> In other words, in conventional radiographic methods such as periapical or panoramic, the superimposed structures and image distortion, especially in the maxilla can conceal the canals, predominantly the canals located at the buccolingual plane which are not distinguishable effortlessly from each other.<sup>[6]</sup> Among the different in vivo methods of root canal morphology detection, Cone-Beam Computed Tomography is a relatively new diagnostic method that may be beneficial when conventional radiographs provide narrow information, while more details are desired.<sup>[7]</sup> The CBCT imaging has advantages such as lower size and price (compared to conventional CT), fast acquisition, submillimeter resolution, relatively low patient radiation dose (compared to conventional CT), and interactive

analysis.<sup>[8]</sup> Perhaps, the most important advantage of CBCT as a non-invasive technique over other conventional radiography techniques such as intraoral and panoramic radiographs is that it exhibits anatomical features in high-quality 3D images without superimposing structures. In addition, the CBCT enables dentists to examine the anatomy of structures in sagittal, coronal and axial sections.<sup>[9]</sup> Given the pervasive use of CBCT in dentistry and the significance of knowing the numbers of root canals in root canal treatment, the aim of this study was to investigate the accuracy of CBCT in detecting root canals. It is worth mentioning that numerous studies have reported that maxillary premolars have a highly variable internal canal configuration, which can be different based on the race and geographical derivation. The reported incidence of maxillary first premolars with 1 root varies from 22% to 66%, with 2 roots from 33% to 84% and with 3 roots from 0% to 6%. The variation of roots and canal systems in this group of teeth possibly will demonstrate a challenge for root canal treatment.<sup>[10]</sup> To our best knowledge, no study has been performed to evaluate the accuracy of CBCT through investigating the frequency of root canals of maxillary first premolars in Iranian population, and in the aim of the current study was to fill this study gap. Moreover, the sectional method was selected as the golden standard following the authoritative study of Michetti et al which was conducted on the same subject as our study.<sup>[11]</sup>

## Materials & Methods

**Sample collecting:** This study was confirmed by Ethics Committee of Jundishapur University of Medical Sciences IRAJUMS.REC.1397.758. "All procedures followed were in accordance with the ethical standards of the responsible committee on human experimentation (Jundishapur University of Medical Sciences) and with the Helsinki Declaration of 1975, as revised in 2008". In present experimental study, 48 human maxillary first premolars extracted recently for therapeutic purposes were collected from Ahvaz's dental clinics regardless of the age, gender and race of patients, and were stored in 100% humidity at room temperature. The criteria for teeth exclusion were: primary teeth, open apex, external root resorption and fractured root, in addition to, any kinds of restoration and previous root canal treatment.

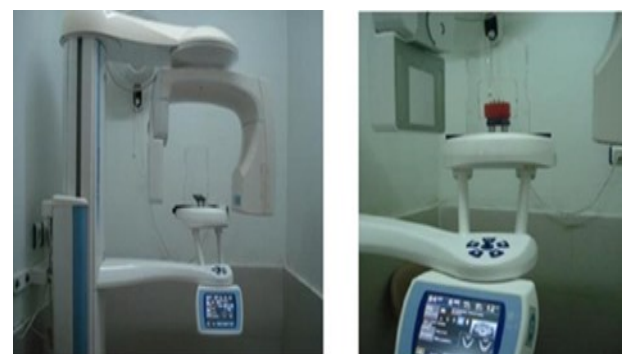**Acrylic block preparation:** The samples were randomly organized in four groups (twenty in each

group). The teeth from CEJ zone were kept within a block made of an equal mixture of Cold-Cure Acrylic powder (Acropars, Marlic Co, Iran), and bone powder of sheep skull to simulate hard tissue trabecular (Figure 1). The roots of the teeth were inserted into the molten red wax (Cavex, Netherlands) to create a resemblance through the PDL space and were then embedded in the mixture of the acrylic and bone powder.




**Figure1. The Preparation of the Block for Teeth Maintenance**

**CBCT Scans:** The CBCT images of each block were made by a CBCT device (NewTom VGi, Verona, Italy) with the exposure parameters of mAS60 / 63, KV84 S4 / 5 and field-of-view (FOV) = 8 × 8, while protection protocol against X-rays was implemented (Figure 2). All images were imported to a desktop computer with a Samsung SyncMaster 2220WM 22-inch LCD monitor (Samsung, Seoul, South Korea). The CBCT images were evaluated using NNT Viewer version 3.00 [QR Srl]. The axial and cross-sectional image slices (1 mm thickness at 0.5 mm intervals) were examined by the assistance of a qualified oral and maxillofacial radiologist with the guidance of an eligible endodontist. None of the observers had prior knowledge of CBCT scans (Figure 3). Each examiner was permitted to use the Viewer software to regulate contrast, brightness and angulations in line with individual inclination.




**Figure2. The Samples placed on NewTom CBCT**



**Figure3. Images of samples captured by CBCT**

**Tooth sectioning:** To perform clinical sectioning as the gold standard, each tooth was embedded in a transparent acrylic block (Ouake acrylic products Co, Shenzhen, China) (Figure 4). The roots of each tooth were horizontally cut into three sections at a thickness of 3 mm from the apex part (CM08-240 disc, 0.2 mm, Lahore, Pakistan). Then, the cut teeth were examined by a different proficient endodontist who was not aware of the morphology of the teeth using a stereomicroscope (motic k series, San Antonio, USA) to evaluate the sections in order to determine the number of root canals as Michetti et al. did in their study.<sup>[11]</sup> It is noteworthy that in order to test intraexaminer reliability, the CBCT images and sections of 25 teeth were randomly nominated and re-evaluated by the observers. The intraexaminer reliability in evaluation of CBCT images and the sections was determined to be 92%.



**Figure4. The samples of tooth sectioning**

**Statistical Methods:** Frequency and percentage of data were used to describe the data. The collected data were entered into SPSS (SPSS version 22, SPSS, SAS, Chicago, IL, USA) and analyzed by Kappa coefficient and Chi-square test. It should be noted that the Kappa coefficient is the coefficient of reliability or agreement that indicates agreement between samples and gold standard. This coefficient ranges from -1 to +1; the closer to +1 indicates a direct agreement. Measures close to -1 indicate inverse agreement and values close to zero point to disagreement. Significance level was set at 0.05.

## Results

In the current study, in all three sections, 29 teeth sections (20.1%) had single canal according to sectional images and CBCT. Moreover, 108 (75%) and 3 (2/1%) teeth sections showed two and three canals based on both methods, respectively. However, in two (1.4%) tooth sections, two canals were found in sectional method while one canal was seen in CBCT, in two (1.4%) teeth sections, one canal was observed in sectional method whereas CBCT indicated two canals. Overall agreement between CBCT and sectional methods was 97.2% with Kappa coefficient of 0.925.

## Discussion

The widespread application of CBCT in all aspects of dentistry including endodontics on the one hand, and the importance of knowing the numbers of root canals in root canal treatment on the other hand, led us to evaluate the accurateness of CBCT in determining the numbers of root canals. In general, in the first section (3 mm away from apex), 11 (22.91%) teeth had one canal either in sectional method or CBCT scans. Based on both methods, 1 (1/2%) and 34 (70.8%) teeth had three and two canals, respectively. In the first section, 1 tooth had one canal based on sectional method and had two canals using CBCT while 1 (1/2%) tooth had two canals according to sectional method and one canal using CBCT. In the first section, p-value was <0.001, Kappa coefficient was 0.897 and agreement was 95.8%. Percentage of agreement, p-value and Kappa coefficient, all, point out significant agreement between sectional and CBCT methods.

It is noteworthy that in the present study, medium FOV was used to record CBCT images. Theoretically, all types of FOV can be used in endodontics, but small FOV is the most suitable one to be used in endodontics because the smaller the FOV illustrates the higher the resolution.<sup>[12]</sup> The CBCT images revealed only one canal of a tooth with two canals in the first section. It might be because of the resolution of the CBCT scan which was not high enough due to the use of medium FOV. Domark et al. conducted a study similar to ours to compare the accuracy of CBCT, Micro CT and digital periapical radiography in detecting the number of mesiobuccal root canals of maxillary molars. They collected 13 maxillary first molars and 14 maxillary second molars. They concluded that for maxillary molar teeth, the number of canals determined by Micro CT as

gold standard was significantly different from the numbers of canals determined by digital periapical radiographs (p-value=0.04). However, there was no significant difference between the number of canals identified using CBCT (p-value=0.52).<sup>[13]</sup> Nevertheless, in the ongoing study, there was no major difference between the results obtained from CBCT scans and those from sectional method as gold standard. In abovementioned study, Domark et al. have believed that the result of their study may be more optimistic than what was happening to patients, as there are more soft and hard tissues around the patient's teeth as well as patients may move during capturing CBCT images. Domark et al.'s arguments seem rational; insomuch the patient's movements diminish the precision of CBCT results due to the motion artifact which is clearly true in the present study.

Besides, the results of the ongoing study demonstrated that in the second section of the samples (6 mm away from apex), 9 (18.8%) teeth had single canal, in both sectional and CBCT methods. Furthermore, based on both methods, 1(2/1%) and 37 (77%) teeth had three and two canals, respectively. Nonetheless, in 1 (2/1%) tooth with two canals using sectional method, the CBCT revealed one canal. In this section, the p-value, Kappa coefficient and agreement were <0.001, 0.941 and 97.9%, respectively, representing direct agreement between CBCT and sectional methods. Kappa coefficient and agreement were higher in the second section than in the first section. Domark et al. investigated the ability of i-cat CBCT to accurately detect the presence or absence of a second canal in the mesiobuccal root of maxillary first and second molars.<sup>[13]</sup> In the study of Blattner et al. in 2010, 20 maxillary first and second molars were stored at 1% thymol at room temperature.<sup>[14]</sup>

Of these 20 teeth, 12 and 8 ones had restoration and caries, respectively. Teeth were then implanted in the maxilla of a pig. The teeth were axially sectioned after CBCT imaging, and the exact numbers of canals were determined. In their study, the CBCT detected the presence of the second mesiobuccal canal in 57.9% of the samples while the sectional method detected it in 68.4% of the samples. Both of these percentages were relatively inferior to other studies like the present study, which could be due to the smaller number of samples in Blattner et al.'s study. However, in their study there was a 79% positive agreement between CBCT and sectional methods. Another reason that led us to reach higher

agreement was that the tooth samples in the ongoing study had not been restored with any kinds of restoration materials. Following the interpretation of the results of the present study, it should be explained that in the second section of samples, the CBCT showed only one canal for one tooth which had two canals according to the gold standard. The error might be due to the fact that the teeth were extracted for therapeutic purposes, and the current study evaluated them regardless of the exact cause of each tooth extraction. To be more specific, one tooth might have been extracted because of having grade 3 mobility and the other tooth due to irreversible pulpitis and the patient's reluctance to undergo root canal treatment. This is significant because some teeth may experience irritation for a long time, which can stimulate the canals, resulting in the formation of reactionary dentin or other calcification, which makes it difficult to detect the canal in CBCT.

In the present study, the results for the last section (9 mm away from apex) were as follow; 9 (18.8%) teeth showed single canal in both sectional and CBCT methods as well as 1 (2/1%) and 37 (77%) teeth had three and two canals based on both methods, respectively. One (2/1%) tooth had one canal based on sectional method although CBCT exhibited two canals for this tooth. In the last section, p-value, Kappa coefficient and agreement was <0.001, 0.941 and 97.9%, respectively, and this section like two previous sections represented a significant agreement between CBCT and sectional methods.<sup>[14]</sup> Additionally, Matherne et al. conducted a study to evaluate the accuracy of CBCT via detecting the frequency of root canals.<sup>[15]</sup> They designed an in vitro study to compare the images of CBCT as gold standard in determining the numbers of root canals with those of charged-couple device (CCD) and photostimulable phosphor plate (PSP) digital radiography.

They collected 72 extracted mandibular incisors, first mandibular premolars and maxillary first molars as well as maintained at 100% humidity after extraction. Concluded that the endodontists could not detect at least one root canal in 40% of teeth through using digital radiographs (regardless of the used system) compared to CBCT images. In other words, the CBCT images always have superior results in determining the number of canals than CCD and PSP images. In general, in the current study, the Kappa coefficient for all three sections was 0.925 (97.2%). Therefore, the positive

values of coefficient suggested that both CBCT and sectional methods had significant agreement with each other. Furthermore, the p-value for all sections was <0.001, indicating the rejection of the hypothesis of difference between the results obtained from CBCT and sectional methods. The present study like aforementioned studies recommended the CBCT as a high-precision diagnostic device to determine the frequency of root canals. However, it should be noted that the ongoing study like other studies had some limitations such as uncertainty of patients' age and gender, number of samples, type of CBCT machine, FOV used in the study. Hence, it is recommended to perform further studies using other types of CBCT device and more samples by considering age<sup>[16]</sup>, gender<sup>[17]</sup> and race of patients.<sup>[18]</sup>

## Conclusions

In conclusion, CBCT is reliable as a precise diagnostic device to detect root canals, although it should be noted that CBCT should be used when other conventional low-dose radiation imaging techniques such as periapical or panoramic radiography do not provide adequate data for efficient root canal treatment.

**Funding:** This study was a research project (B-97105), supported and funded by Jundishapur University of Medical Sciences.

**Conflict of interest:** We declare no conflict of interest.

## Authors' Contribution

Mohammad Yazdizadeh developed the study concept and designed as well as performed the study supervision. Masoumeh Mohsen pourian performed the experimental study, and recorded clinical indices. Azin Alasvand Javadi collected and interpreted data, performed statistical analysis, as well as prepared and edited the manuscript.

## References

- Estrela C, Bueno MR, Couto GS, Rabelo LE, Alencar AH, Silva RG ,et al. Study of Root Canal Anatomy in Human Permanent Teeth in A Subpopulation of Brazil's Center Region Using Cone-Beam Computed Tomography - Part 1. *Braz Dent J* 2015;26:530-6.
- Ahmed HMA, Versiani MA, De-Deus G, Dummer PMH. A new system for classifying root and root canal morphology. *Int Endod J* 2017;50:761-70.
- Kottoor J, Velmurugan N, Surendran S. Endodontic management of a maxillary first molar with eight root canal systems evaluated using cone-beam computed tomography scanning: a case report. *J Endod* 2011;37:715-9.
- Patel S, Wilson R, Dawood A, Foschi F, Mannocci F. The detection of periapical pathosis using digital periapical radiography and cone beam computed tomography - part 2: a 1-year post-treatment follow-up. *Int Endod J* 2012;45:711-23.
- Ee J, Fayad MI, Johnson BR. Comparison of endodontic diagnosis and treatment planning decisions using cone-beam volumetric tomography versus periapical radiography. *J Endod* 2014;40:910-6.
- Shah N, Bansal N, Logani A. Recent advances in imaging technologies in dentistry. *World J Radiol* 2014 ;6:794-807.
- Shin HS, Nam KC, Park H, Choi HU, Kim HY, Park CS. Effective doses from panoramic radiography and CBCT (cone beam CT) using dose area product (DAP) in dentistry. *Dentomaxillofac Radiol* 2014; 43: 20130439.
- Adibi S, Zhang W, Servos T, O'Neill PN. Cone beam computed tomography in dentistry: what dental educators and learners should know. *J Dent Educ* 2012;76:1437-42.
- Machado GL. CBCT imaging - A boon to orthodontics. *Saudi Dent J* 2015;27:12-21.
- Abella F, Teixidó LM, Patel S, Sosa F, Duran-Sindreu F, Roig M. Cone-beam Computed Tomography Analysis of the Root Canal Morphology of Maxillary First and Second Premolars in a Spanish Population. *J Endod* 2015;41: 1-7.
- Michetti J, Maret D, Mallet JP, Diemer F .Validation of Cone Beam Computed Tomography as a Tool to Explore Root Canal Anatomy. *J Endod* 2010; 36:1187-90.
- Abella F, Patel S, Durán-Sindreu F, Mercadé M, Bueno R, Roig M. An evaluation of the periapical status of teeth with necrotic pulps using periapical radiography and cone-beam computed tomography. *Int Endod J* 2014;47:387-96.
- Domark JD, Hatton JF, Benison RP, Hildebolt CF. An ex vivo comparison of digital radiography and

- cone-beam and micro computed tomography in the detection of the number of canals in the mesiobuccal roots of maxillary molars. *J Endod* 2013;39:901-5.
14. Blattner TC, George N, Lee CC, Kumar V, Yelton CD. Efficacy of cone-beam computed tomography as a modality to accurately identify the presence of second mesiobuccal canals in maxillary first and second molars: a pilot study. *J Endod* 2010; 36: 867-70.
  15. Matherne RP, Angelopoulos C, Kulild JC, Tira D. Use of cone-beam computed tomography to identify root canal systems in vitro. *J Endod* 2008; 34: 87-9.
  16. Martins JNR, Ordinola-Zapata R, Marques D, Francisco H, Caramês J. Differences in root canal system configuration in human permanent teeth within different age groups. *Int Endod J* 2018;51:931-41.
  17. Pérez-Heredia M, Ferrer-Luque CM, Bravo M, Castelo-Baz P, Ruíz-Piñón M, Baca P. Cone-beam Computed Tomographic Study of Root Anatomy and Canal Configuration of Molars in a Spanish Population. *J Endod* 2017;43:1511-6.
  18. Martins JNR, Gu Y, Marques D, Francisco H, Caramês J. Differences on the Root and Root Canal Morphologies between Asian and White Ethnic Groups Analyzed by Cone-beam Computed Tomography. *J Endod* 2018;44:1096-104.