

## ***Rib Fracture Fixation, a new Era in Treatment of Chest Trauma in Albania***

Fatmir ÇAUSHI<sup>1\*</sup>

Received: 6 February 2020 / Accepted: 5 March 2020 / Published online: 20 July 2020

© The Author(s) 2020. This article is published with open access at <https://journal.astes.org.al>

### ***Abstract***

Rib fractures are a consequence of the forces of various arthritis that the chest wall and the thoracic cage itself undergo, and are most often due to closed injuries (eg, motor vehicle collision, falls from height, and Hits with strong objects ..), but penetrating injuries (eg, wounds with sharp tools, gunshot injuries ...) can also result in rib fractures. Non-operative treatment is based on pain control and pulmonary support, which mainly aim to avoid the need for intubation, which is associated with increased levels of pulmonary disorders until death.

For patients who continue to have acute pain or instability of the chest wall (eg, flail chest), each of which impedes pulmonary function despite maximal medical therapy, or those with non-consolidating rib fractures and causing pain in the persistence and impairment of pulmonary function, surgical stabilization of fractured ribs, also known as osteosynthesis, are now well-known procedures that improve the quality of treatment of the traumatized patient.

The thoracic wall injury association has been established to better study all aspects related to the consequences, diagnosis and treatment of thoracic wall injuries [1].

Indications for osteosynthesis, patient preparation, operative technique for stabilizing fractured ribs and the results are quite significant.

**Keyword:** Rib fractures, Chest wall, trauma, osteosynthesis...

### ***Introduction***

Chest wall trauma now days are common, and contribute significantly to morbidity and mortality of trauma patients. Blunt trauma to the chest wall and rib fractures are remarkably frequent. Rib fractures accounted for up to 10% of the total number of traumatic hospitalizations.[1, 2, 3] (Fig.1) Blunt thoracic trauma causes pulmonary dysfunction through three primary mediators: inefficient ventilation

through disruption of pulmonary mechanics, atelectasis due to pain, and pulmonary contusion.(Fig.2) Generalized management of multiple rib fractures and flail chest in last 50 years consists of adequate pain control, management of pulmonary dysfunction by invasive and noninvasive means and in some cases, surgical fixation. Rib fractures can be interpreted as signs of significant trauma.[1, 2, 3, 4, 5]

The greater the number of fractured ribs, the higher the mortality and morbidity rates. Rib fixation has the potential to improve pulmonary mechanics and reduce pain from fracture displacement. Multiple studies have shown that patients with flail chest have substantial benefit when they undergo surgery compared with nonoperative management. [4, 5, 6]

Operative rib fixation has the potential to reduce ventilator days and ICU stay and subsequently hospital costs in selected patients with severe traumatic flail chest requiring mechanical ventilation. Rib-specific plating systems have started to be used in the last 10 years. These have inaugurated in the modern era of rib repair with chest wall stabilization (CWS) techniques that are safer, easier to perform, and more efficient. (Fig. 3) Traditional CWS with a large incision has been a controversial approach due to extensive injury and several complications. However, with

Original article, no submission or publication in advance or in parallel

#### **\* Corresponding author:**

Asc. Prof. Dr. Fatmir ÇAUSHI MD, PhD,

✉ [fcaushi@yahoo.com](mailto:fcaushi@yahoo.com)

<sup>1</sup> Head of Department of Thoracic Surgery, University Hospital  
"Shefqet Ndroqi" Tirana, Albania

the recent development of new materials and technologies, CWS has become relatively simple, and the complications associated with it have been significantly reduced. (Fig. 4) The rib fracture types can be roughly divided into anterior (anterior axillary line), lateral (between anterior axillary line and posterior axillary line), and posterior (posterior axillary line). All these can be accomplished by minimal muscle dissociation or scapular distraction. de Campos and White, in their study, described the choice of incision and the technique of muscle protection during exposure in detail. [7, 8, 9] Care must be taken to avoid damage to the long thoracic nerve that descends along the anterior axillary line and is present above the serratus anterior muscle. Because of the proximity to the processus transversus, costal angle and subscapularis, the posterior fractures are considered as the most difficult to repair. Recent consensus statements have sought to define the indications and contraindications, as well as the when, the how, and the technical details of CWS. Repair should be considered for patients who have:

1. True flail chest – Based on evidence and EAST guidelines
2. Severely displaced (bi-cortical) rib fractures (as judged by admitting physician), generally three or more. – Based on limited evidence and expert opinion [9, 10]
3. Refractory pain or respiratory compromise – Based on limited evidence and expert opinion [9, 10]

The rib fixation is contraindicated:

1. Patients with severe traumatic brain injury.
2. Patients with severe pulmonary contusion as the major driver of respiratory dysfunction and likely to require long term positive pressure ventilation. [11, 12]

In order to take a decision for the rib fixation according to UK rib fixation guidelines we have to take in consideration these steps:

1. Obtain 3D reconstructions of chest CT in patients who meet the above criteria. 3D recons are not indicated if not meeting these criteria unless discussed with trauma attending, including those with multiple non-displaced rib fractures regardless of the number fractured.
2. Evaluate for retained hemothorax for potential clearance at combined operation. (Fig. 5)
3. Discuss with candidacy for rib fixation with Trauma

Attending, establish operative plan and positioning.

- Rib fixation is optimally performed within the first 72 hours after imaging for maximum benefit.
- Regional analgesia should be considered/ attempted for all patients undergoing rib fixation without specific contraindications.
- Data are sparse on infection rate of hardware. Empyema should be considered a strong but relative contraindication to rib fixation.
- Not every level needs to be fixed, the goal is to restore general chest wall integrity. Attempt to stabilize both fractures in flail chest, but balance

this with the need for further incisions. [13, 14]

- Ribs 3-9 contribute the most to respiratory function. Avoid plating 1,2, 11, 12.
  - Posterior fractures, those well buttressed by latissimus dorsi and trapezius are generally well tolerated, avoid plating these and anything within 2.5 cm of the transverse process of the vertebrae.
4. Contact Synthes representative regarding availability of hardware sets.
  5. Contact OR front desk preferably the night before to discuss timing (<72 hours) and importance of performing operation during daytime hours.
  6. Plan incisions for maximal benefit and minimal morbidity, split muscles instead of dividing, use right angle instruments if needed. [15]
  7. Consider intra-operative x-ray to rule out pneumothorax if no current chest tube and no plans to place at time of surgery.
  8. Consider use of fluoroscopy or intra-operative x-ray to confirm hardware placement when utilizing intramedullary splinting. (Fig. 6)

Meanwhile in Albania, as in other fields, this protocol is entering so timidly facing prejudiced thoughts and economic difficulties but with very convincing results. During the last 3 years, 10 cases of chest stabilization have been treated in our clinic by positioning a specific plate system for the ribs. The result was excellent in 9 of them. (Fig. 7) These patients left the hospital after 7 days in excellent condition. (Fig. 8) Meanwhile, in one case, three days after surgery an acute kidney failure was installed which led to an unpleasant situation. However, even this separate case raises the issue of equipping our hospital facilities with the equipment needed to treat complex patients as a trauma patient.

## Conclusions

The thoracic wall injury association has been established to better study all aspects related to the consequences, diagnosis and treatment of thoracic wall injuries [1].

Indications for osteosynthesis, patient preparation, operative technique for stabilizing fractured ribs and the results are quite significant.

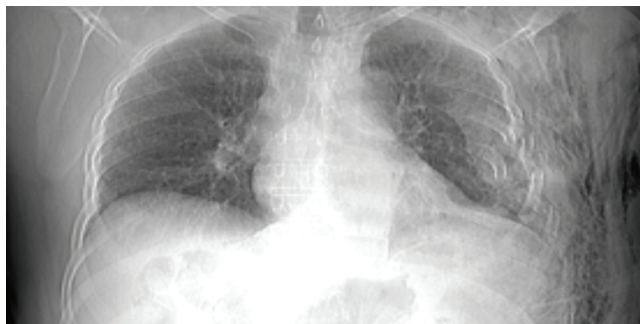
**COI Statement:** This paper has not been submitted in parallel. It has not been presented fully or partially at a meeting or podium or congress. It has not been published nor submitted for consideration beforehand.

All authors declare that there is no conflict of interest.

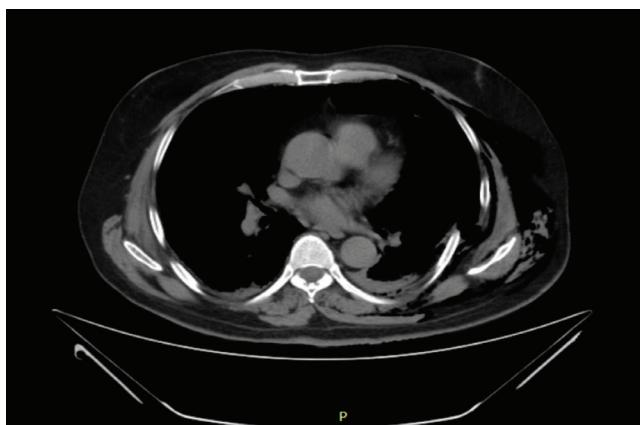
**This research received no specific grant from any funding agency in the public, commercial, or nonprofit sectors.** There are no relevant or minor financial relationships from authors, their relatives or next of kin with external companies.

**Figures:**

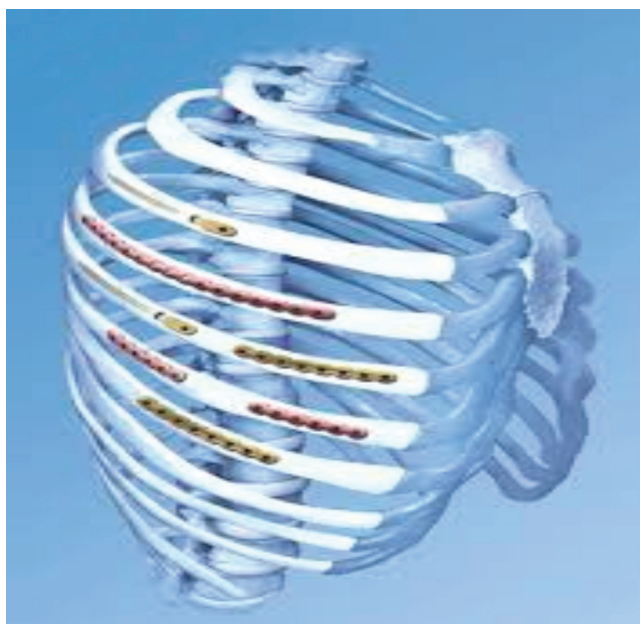*Fig. 1 X-ray of the thorax in a patient with fractured and dislocated ribs in the left hemithorax*



*Fig. 2 Ct-scan of the thorax in a patient with fractured and dislocated ribs in the left hemithorax*

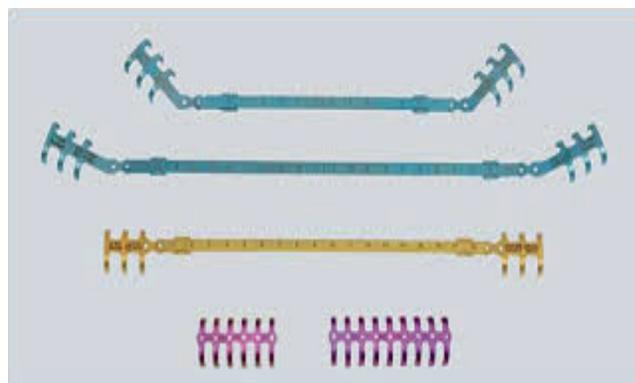


*Fig. 3 A model of rib fixation*



*Fig. 4 Several types of plates for rib fixation (a, b, c)*

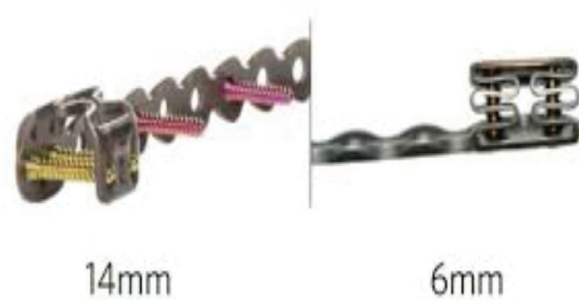
a)



b)



c)



*Fig. 5 Rib fixation after evacuating hemothorax*

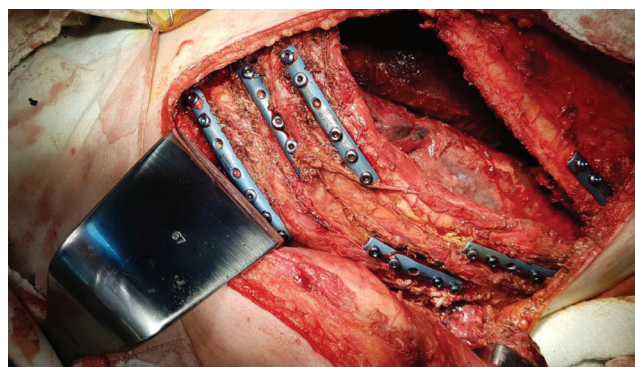




Fig. 6 X-ray after rib fixation in the right hemithorax

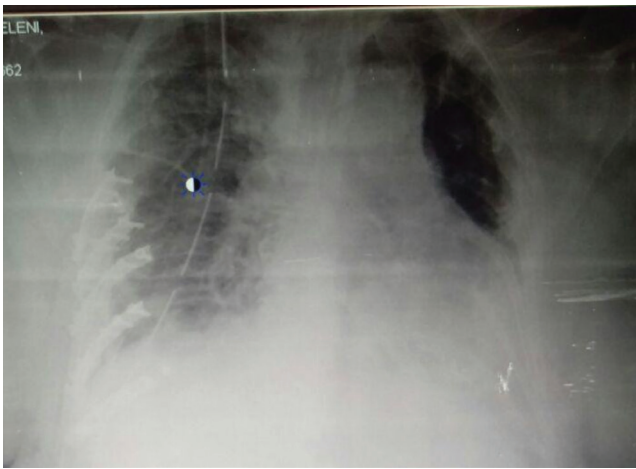
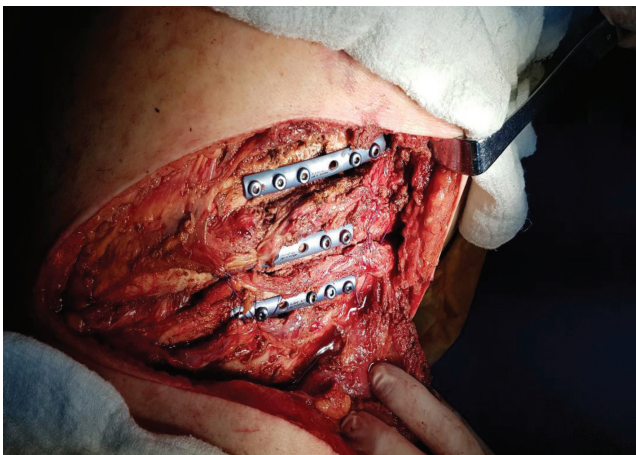


Fig. 7 Episodes of rib fixation in surgery

- a) Lady of 70 years with three dislocated broken ribs (4, 5, 6) on the right hemithorax  
 b) Gentleman of 65 years with five broken ribs (4, 5, 6, 7, 8) and flail chest on the left hemithorax

a)



b)

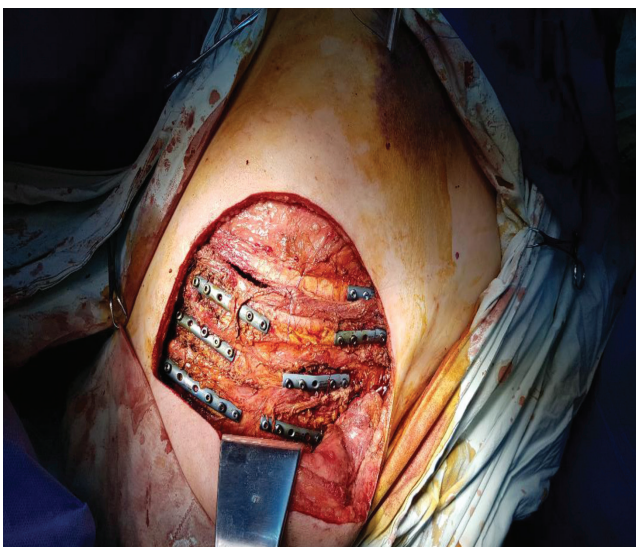
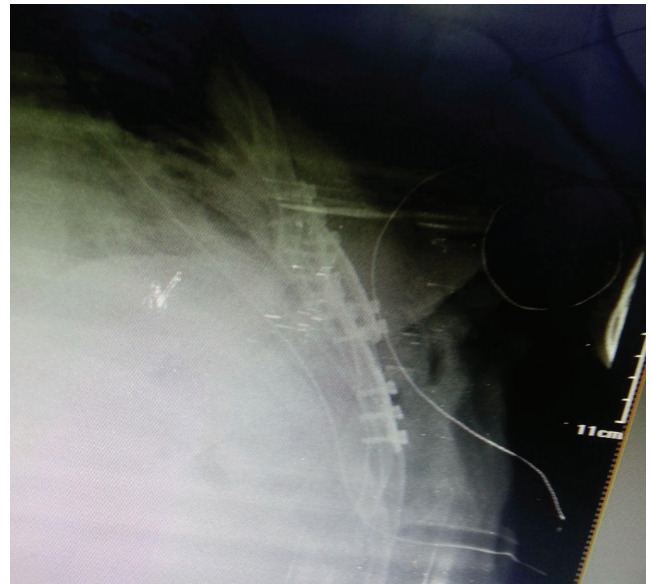
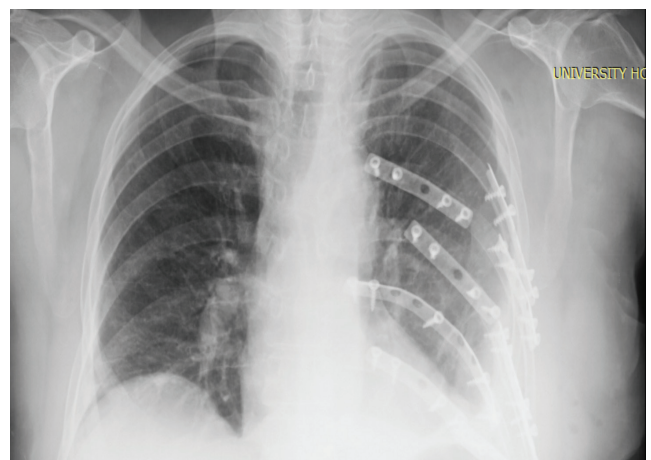Fig. 8 X-ray after rib fixation

- c) Lady of 70 years with three dislocated broken ribs (4, 5, 6) on the right hemithorax  
 d) Gentleman of 65 years with five broken ribs (4, 5, 6, 7, 8) and flail chest on the left hemithorax

a)



b)



## References

1. Qiang Zhang, Lei Song, Shaonan Ning, Hao Xie, Nan Li, and Yanbin Wang. Recent advances in rib fracture fixation. *J Thorac Dis*. 2019 May; 11(Suppl 8): S1070–S1077.
2. Michelitsch C, Acklin YP, Hässig G, et al. Operative Stabilization of Chest Wall Trauma: Single-Center Report of Initial Management and Long-Term Outcome. *World J Surg* 2018;42:3918-26. 10.1007/s00268-018-4721-8
3. Ziegler DW, Agarwal NN. The morbidity and mortality of rib fractures. *J Trauma* 1994;37:975-9. 10.1097/00005373-199412000-00018
4. Lafferty PM, Anavian J, Will RE, et al. Operative treatment of chest wall injuries: indications, technique, and outcomes. *J Bone Joint Surg Am* 2011;93:97-110. 10.2106/JBJS.I.00696
5. Fraser SF, Tan C, Kuppusamy MK, et al. The role of a video-assisted thoracic approach for rib fixation. *Eur J Trauma Emerg Surg* 2017. 43:185-90. 10.1007/s00068-016-0641-1
6. Solberg BD, Moon CN, Nissim AA, et al. Treatment of chest wall implosion injuries without thoracotomy: technique and clinical outcomes. *J Trauma* 2009;67:8-13; discussion 13. 10.1097/TA.0b013e3181a8b3be
7. Tarng YW, Liu YY, Huang FD, et al. The surgical stabilization of multiple rib fractures using titanium elastic nail in blunt chest trauma with acute respiratory failure. *Surg Endosc* 2016;30:388-95. 10.1007/s00464-015-4207-9
8. De Campos JRM, White TW. Chest wall stabilization in trauma patients: why, when, and how? *J Thorac Dis* 2018;10:S951-S962. 10.21037/jtd.2018.04.69
9. Davignon, et. Al. Patholophysiology and management of the flail chest, *Minerva Anesthesiol*. 2004 Apr;70(4):193-9
10. Kasotakis, G. et. al. Operative fixation of rib fractures after blunt trauma. *J Trauma AcuteCareSurg*. 2017 Mar;82(3):618-626.
11. Voggenreiter G, Neudeck F, Aufmkolk M, Obertacke U, Schmit-Neuerburg KP. Operative chest wall stabilization in flail chest—outcomes of patients with or without pulmonary contusion. *J Am Coll Surg*. 1998;187:130–138.
12. Teng J, Cheng Y, Ni D, et al. Outcomes of traumatic flail chest treated by operative fixation versus conservative approach. *Journal of Shanghai Jiaotong University*. 2009;29:1495–1498.
13. Brasel, K et. al. Western Trauma Association Critical Decisions in Trauma: Management of Rib Fractures. *J Trauma Acute Care Surg*. 2017;82: 200–203.
14. Majercik, S., Pieracci, F. *Thorac Surg Clin*. 2017 May;27(2):113-121.
15. Hasenboehler E, et. al. Treatment of traumatic flail chest with muscular sparing open reduction and internal fixation: description of a surgical technique. *J Trauma*. 2011 Aug;71(2):494-501.