

Solitary Cecal Diverticulitis During Surgery for Acute Appendicitis.

Rovena Bode¹, Eriol Braholli¹, Asfloral Haxhiu¹, Xheladin Draçini¹, Etmont Çeliku¹

Abstract

Background: Cecal diverticulitis is an unusual condition that presents clinically similar to appendicitis. The diagnosis is not always easy and in the majority of cases it is usually made during laparotomy.

The aim of the present study is to retrospectively report our experience with solitary cecal diverticulitis, to determine its incidence in patients presenting as an acute abdomen, as well as identify the symptoms and clinical features that may aid in making a pre-operative diagnosis. And to compare this with a review of the literature, focusing on the surgical treatment and also on the indication of appendectomy in the presence of cecal diverticulitis not requiring surgery.

Material and methods: Data was collected in patients hospitalized for acute appendicitis or acute abdomen, in the surgical emergency unit of University Hospital Centre "Mother Teresa" Tirana, in a period of 3 years (2015-2017). Sex, age, duration of symptoms, preoperative diagnosis, management, intraoperative findings, histologic examination, length of hospital stay and complications of all patients affected by solitary cecal diverticulitis were reviewed.

Results: In the study period, 15 patients presented with a solitary cecal diverticulitis. All patients presented with abdominal pain, additional symptoms were nausea, vomiting and fever. The mean white blood cell count was from 8500-19.200/mm³, while the remaining laboratory results were normal. There were no specific findings on abdominal X-ray or ultrasonography. Intraoperative findings ranged from localized /circumscribed peritonitis to generalised peritonitis due to acute diverticulitis and a normal appendix. Surgery ranged from diverticulum resection accompanied to appendectomy, to ileocecal resection, and right hemicolectomy.

Conclusions: Cecal diverticulitis should be included in the differential diagnosis of the cases with pain in the right lower quadrant. Preoperative diagnosis of cecal diverticulitis cannot always be made, since the signs and symptoms are similar to acute appendicitis, but is important in order to decide how to manage this condition. Diverticulectomy and incidental appendectomy are the preferred method of treatment in uncomplicated cases. Right hemicolectomy is a recommended treatment option in complicated patients or those suspicious for tumor during surgery.

Keywords: Solitary, Cecum, Diverticulum, Appendectomy

***Corresponding Author:** Rovena Bode

✉ **Email:** rovenabode@gmail.com

¹University Hospital Centre "Mother Theresa" Tirana, Albania

Introduction

The cecal diverticula described for the first time by Potier in 1912[1] remain a rare entity, especially if solitary, with an incidence between 1:50 and 1:300 of that of appendicitis[2]. In Europe and in The United States, right side colon diverticulitis remains a rare and uncommon pathological finding.

The incidence of solitary cecal diverticulum (SCD) in North America is about 1-2 %, while in Corea, China and Japan the incidence is ten times higher, accounting for 43-50 % of all cases of colonic diverticulosis [3]. Cecal diverticula form 3.6 % of all colonic diverticula, and 13 % of these develop inflammation at some time [3][4][5]. The mean age of patients is around 40 years, with male predominance of 60% [3][4][5].

Cecal diverticulae are classified as congenital or acquired. The congenital cecal diverticulae are true diverticulae; these include all the layers of the cecal wall and develop at 6 weeks gestation from a transient out-pouching of the cecum[3].The false or acquired diverticula are similar to sigmoid diverticula, and contain no muscular layer[3].

Cecal diverticula can also be classified as solitary or multiple, and can be found in the appendix, cecum, and ascending colon [8]. The area which is 2.5 cm from the ileocecal junction is the area from which 80% of CD stem [6]. About 50 % are on the anterior cecal wall and may cause peritonitis [7]. When the cecal diverticula are

posterior, this may cause inflammatory masses that simulate carcinoma [7]. Acute appendicitis is the clinical diagnosis in 85 % of the cases of cecal diverticulitis [3]. Despite advances in radiological examinations, a correct preoperative clinical diagnosis occurs in only 4- 16 % of cases [9].

Aim of study

The aim of our study is to identify the symptoms and clinical features that may aid surgeons to make a preoperative diagnosis.

Material and methods

This is a retrospective analysis performed to identify patients with solitary cecal diverticulitis who presented with "acute surgical abdomen" at "Mother Teresa" University Hospital Center of Tirana, from September 2014 to September 2017.

They underwent surgery for a preliminary diagnosis of acute appendicitis and were diagnosed intraoperatively with SCD. Demographic characteristics, causes of hospital admissions and their past medical histories were recorded. Preoperative laboratory and radiological evaluations were also reviewed. Operative findings, surgical methods, early postoperative follow-

up and pathologic examination results were evaluated.

Results

During the study period, 1808 surgeries were performed for acute appendicitis. The study group consisted of 15 patients, with an incidence of 0.8% or 1:120 appendectomies.

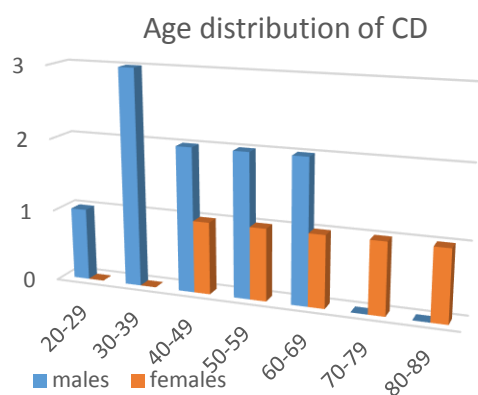


Chart 4.1: Age distribution of patients diagnosed with SCD in our study.

Their mean age was 52 years (range: 24-88). Ten patients were male and five were female (male / female 2:1). [Chart 4.1]. The SCD patients presented to the Emergency Department with localized RIF pain of 3-7 days duration.

Acute appendicitis was the clinical diagnosis in 10 (66.7%) of them and acute abdomen for determination in 5 (33.3%) of them. The reported abdominal pain was similar to that seen in acute appendicitis, but with the pain felt higher than Mc Burney's point and often milder in description.

Presenting symptoms	Nr. of Pts.	Percentage %
Right sided abdominal pain	9	60
Infraumbilical pain	6	40
Diarrhea	4	26.6
Anorexia	5	33.3
Constipation	4	26.6
Nausea	4	26.6
Fever	6	40
Vomiting	4	26.6
Sweats	5	33.3

Table 4.1: Presenting symptoms of patients with confirmed cecal diverticulitis.

Pain was experienced for a longer duration (four to seven days) and with a lack of toxicity. Those who reported having diarrhea had symptoms for a week prior to their admission due to the inflammation from the cecum affecting the nearby terminal ileum [Table 4.1]. Blood tests showed an elevated white blood cell count in eleven patients (73%). In four of them were normal. [Table 4.2]

Diagnosis of SCD was confirmed in 5 of the 15 patients on imaging studies alone. An ultrasound exam was useful in three cases (n = 3/15, 20%), while a computed tomography (CT) scan was done in only four cases, and resulted in strong suspicious for the pathology in only two cases (n = 2/15, 13.3%). In the other 2 patients great suspicions were for cecal tumor mass.

Nine patients were operated by McBurney incision, in two of them the incision was converted to median

inferior, in 5 of them the median incision was used from the beginning and in one patient a pararectal incision was used. [Table 4.2]

In two of 15 cases (13.3%) the cecal mass was located medially above the ileocecal junction. In one case medially and too near the ileocecal junction [Picture 4.1].

In six cases (40 %) the cecal mass was anterior, and in two cases (13.3%) the cecal mass was located laterally.

In two cases it was located posteriorly as a posterior abscess.

Two of 15 patients (13.3 %) had a perforation of their diverticulum.

Nr	Sex	Age	Sympt length	WBC	Diagnose	Incision	Operative findings	Surgery	Length of stay	Pathology
1	M	24	3 days	12300	IO	McBurney	2-3 cm Anterior inflamed cecal mass	Div.ect + IncApp	3	Norm app.
2	M	54	4 days	15200	IO	McBurney	2 cm anteriorly perforated diverticulum	Div.ect + IncApp	4	Norm app.
3	F	63	6 days	10500	IO	McBurney converted to Median Inferior	3*3 necrotized cecal diverticulum near cecal valve	Right h.colectomy + IC anast	5	Div.
4	M	32	6 days	17700	CT+POP	Median Inferior	Generalized peritonitis, diverticular perforation	Ileocecal resection + IC anast	6	Div.
5	M	65	5 days	14300	IO	Median Inferior	Generalized peritonitis, diverticular perforation	Right h.colectomy + IC anast	6	Div.
6	M	38	4 days	11600	IO	McBurney	2 cm lateral diverticular cecal mass	Div.ect + IncApp	3	Norm app.
7	F	70	7 days	8600	CT+POP	Median Inferior	Perforated posterior ganrenous cecal diverticulum	Right h.colectomy + IC anast	8	Div.
8	F	46	4 days	13800	IO	McBurney	Pericecal mass, anterior inflamed diverticulum	Div.ect + IncApp	5	Norm app.
9	M	48	3 days	9700	IO	McBurney	Anterolateral abscess, perforated diverticulum	Div.ect + IncApp	4	Norm app.
10	F	88	7 days	11600	CT (post app) POP	Median Inferior	Generalized peritonitis ex perforated cecal diverticulum	Right h.colectomy + IC anast	7	Div.
11	M	30	6 days	10700	IO	McBurney converted to Median Inferior	Retrocecal abscess, perforated cecal diverticulum	Right h.colectomy + IC anast	5	Div.
12	M	47	3 days	9700	IO	Pararectal	Anteromedial cecal	Div.ect + IncApp	4	Norm app.

							diverticular mass			
13	F	56	4 days	10400	IO	McBurney	2cm medially to caecum inflamed diverticulum	Div.ect + IncApp	3	Norm app.
14	M	67	5 days	15700	CT (post app) POP	Median Inferior	Generalized peritonitis ex perforated cecal diverticulum	Right h.colectomy + IC anast	6	Div.
15	M	57	3 days	9200	IO	McBurney	Inflamed diverticulum anteriorly to cecum	Div.ect + IncApp	3	Norm app.

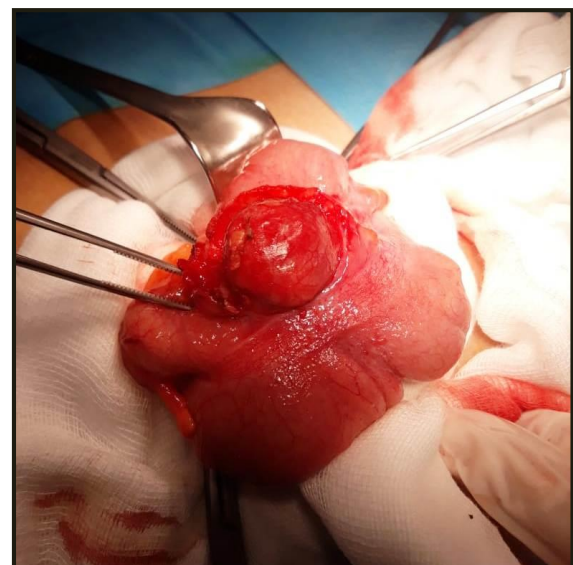Table 4.2: Database of patients with confirmed SCD. (Post app=Post appendectomy; POP=Postoperative; Div.ect=Diverticulectomy; IncApp=Incidental appendectomy; H.colectomy=Hemicolectomy; IC anast= Ileocolic anastomosis; Div=Diverticulitis; Norm app= Normal appendix).

From 15 patients operated we found: An inflamed diverticulum in 4 cases, an inflamed cecal mass in two patients, and while in the other four patients was found an abscess retroceally, or in a pericecal location.

In five patients a pelvic/generalised peritonitis due to free perforation was found. In two cases the diverticulum was found medially and too near the ileocecal junction, in six cases (40 %) the cecal mass was anteriorly, and in two cases (13.3 %) the cecal mass was located laterally, in two cases it was located posteriorly as a posterior abscess.

Regarding the surgical technique performed, in eight of fifteen patients a diverticulectomy and appendectomy was done (n=8, 53.3%), in six of them a right hemicolectomy was performed (n=6, 40%), and in only one of them (n=1, 6.7%), ileocecal resection was the

chosen procedure. [Table 4.2; Chart 4.2].



Picture 4.1: Intraoperative picture of a solitary cecal diverticulum too near the ileocecal valve.

Post-operatively, all patients were continued on intravenous antibiotics until their symptoms resolved (mean time of three days). The intravenous antibiotics regimen consisted of

Cefazolin 1 g, every six hours, Metronidazole 500 mg, every eight hours, and in some of them an adjusted dose of Gentamycin (80 mg twice daily). Patients with a Penicillin allergy (n = 1) received a regimen of Ciprofloxacin.

All patients, regardless of treatment modality, were also given a course of oral antibiotics on discharge from hospital for 5 days.

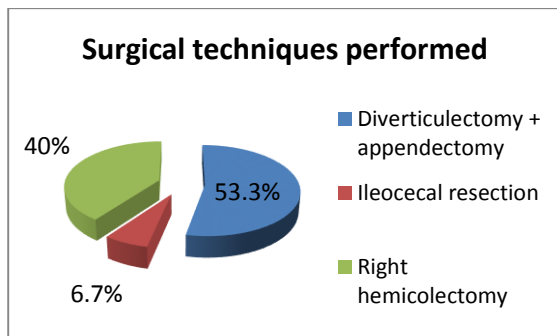


Chart 4.2: Surgical techniques performed in patients confirmed with SCD intraoperatively.

The hospital stay varied from 3 to 8 days. Five patients had postoperative complications: one had urinary retention, three others had a wound infection and one had a postoperative haemorrhage.

The histopathologic examinations of all seven resected ileocecal specimens were reported as solitary cecal diverticulitis.

All patients, regardless of treatment modality, were also given a course of oral antibiotics on discharge from hospital for 5 days.

Discussion

It is presumed that a single cecal diverticulum is in fact a congenital one that appears in the 6th week of embryonic development[3]. Like other congenital diverticula, the cecal diverticula remain asymptomatic until the onset of complications: perforation, inflammation, or malignancy[6][10]. Clinically, patients with SCD present with a long history of right lower quadrant abdominal pain, with the absence of systemic toxic signs and of nausea/vomiting [11]. Unlike in appendicitis, the pain remains in the right lower quadrant instead of migrating from the epigastrium [12].

Differential diagnosis is initially done with acute appendicitis, then with right kidney colic, pelvic inflammatory disease, ureteral calculi, cecal perforation due to foreign body intake and Crohn's disease. There are certain signs that may point the surgeons attention to the diagnosis of cecal diverticulum, the most important being the duration of pain, which does not have periods of lull, and absence of toxic signs, nausea and vomiting[13].

Preoperative diagnosis is often extremely difficult, certain investigations being necessary for a right diagnosis. Barium enema was considered in the past to be sufficient for the diagnosis of cecal diverticulosis, but according to literature, its interpretation may often be erroneous or inconclusive.

Abdominal ultrasound may reveal free fluid in the right iliac fossa and a

thickened lumen of a formation that belongs to the cecal wall, but it is hard to distinguish from the appendix. Colonoscopy remains the “gold standard” for the diagnosis of cecal diverticula. Colonoscopy will not be performed in acute cases of diverticulosis or when the diverticula are perforated[14].

Currently, CT scan, ultrasound (US), and magnetic resonance (MR) imaging have all been described as effective modalities to preoperatively differentiate right-sided diverticulitis from other intra-abdominal pathology. Findings on CT scan consistent with a diagnosis of right colon diverticulitis are similar to those appreciated with left-sided disease. Findings include colonic wall thickening, presence of extraluminal mass, haziness and stranding of adjacent pericolic fat, and

thickening of nearby fascial planes[15][17]. Though CT scan has a documented diagnostic accuracy rate of 90% to 95%, right-sided diverticulitis may still be radiographically mistaken for appendicitis with abscess, Crohn's disease, omental infarction, or colon cancer[15][16].

There are four grades of diverticulitis according to the management guidelines (ACS recommendations). Grade I: inflamed diverticulum; Grade II: inflamed mass. Grade III: localized abscess/fistula. Grade IV: perforation/ruptured abscess with generalized peritonitis;[21].

Table 5.1 lists all treatment possibilities and associated advantages and disadvantages depending on the disease status.

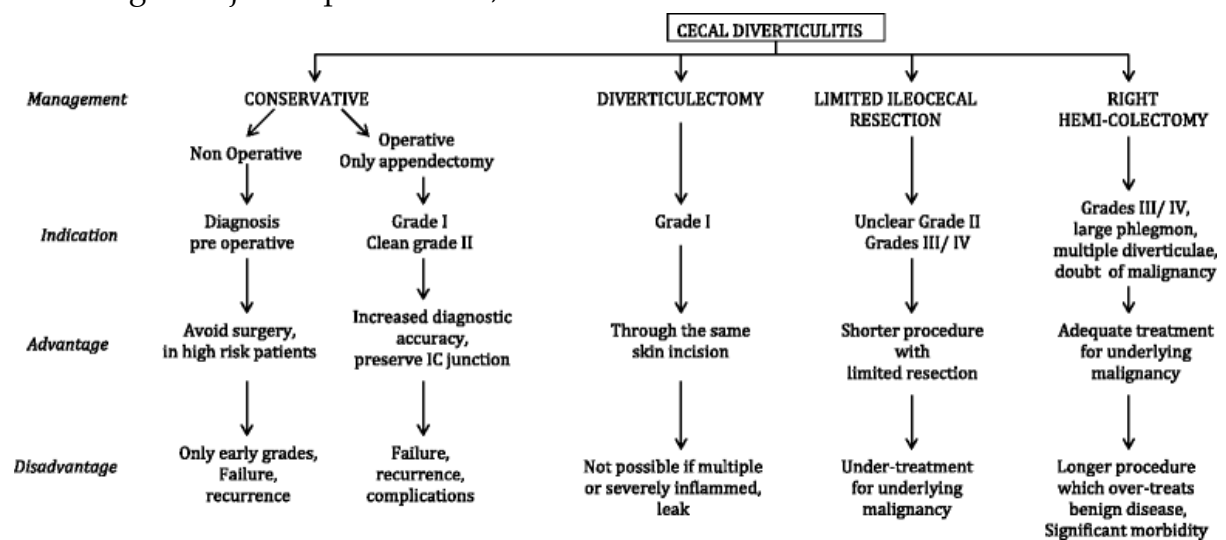


Table 5.1: Treatments and associated advantages and disadvantages for different grades of solitary cecum diverticulum (ACS recommendations).

Conservative treatment with intravenous antibiotics can be

considered if a definitive diagnosis is established pre-operatively[18].

If a SCD is clearly identified intraoperatively, a simple diverticulectomy or invagination of the diverticulum combined with appendicectomy have been advocated for uncomplicated diverticulitis [6][18].

Limited ileocecal resections or right hemicolectomy should be considered in patients with marked inflammatory changes or if a complication such as perforation or torsion has occurred.[10][18][19].

A right hemicolectomy is also mandatory if a diverticulum is macroscopically indistinguishable from a tumour especially if the SCD is retroperitoneally located on the posterior wall of the caecum[20].

Conclusions

Preoperative diagnosis of SCD is challenging since the signs and symptoms are similar to acute appendicitis.

Patients with imaging diagnosed or clinical suspicion of uncomplicated cecal diverticulitis can be managed conservatively using intravenous antibiotic regimens.

CT scan should be reserved for exclusion of bowel perforation or malignancy, appendicitis, or if ultrasound scans are non-diagnostic.

Diverticulectomy and incidental appendectomy are the preferred

method of treatment in uncomplicated cases.

Right hemicolectomy is a recommended treatment option in complicated patients or those suspicious for malignancy during surgery.

References

1. Stollman N, Raskin JB. Diverticular disease of the colon. *Lancet*. 2004;363:631-9.
2. Malek L, Sultan A, Abbas M, Al-Awadhi N. Perforated cecal diverticulitis mimicking an acute appendicitis: a case report. *Cases J*. 2009;2:7901.
3. Connolly D, McGookin RR, Gidwani A, Brown MG. Inflamed solitary cecal diverticulum - it is not appendicitis, what should I do? *Ann R Coll Surg Engl*. 2006;88:672-4.
4. Cole M, Ayantunde AA, Payne J. Cecal diverticulitis presenting as acute appendicitis: a case report. *World J Emerg Surg*. 2009;4:29.
5. Kumar S, Fitzmaurice GJ, O'Donnell ME, Brown R. Acute right iliac fossa pain: not always appendicitis or a cecal tumour: two case reports. *Cases J*. 2009;2:88.
6. Abogunrin FA, Arya N, Somerville JE, Refsum S. Solitary cecal diverticulitis - a rare cause of right iliac fossa pain. *Ulster Med J*. 2005;74:132-3.

7. Cole M, Ayantunde AA, Payne J. Cecal diverticulitis presenting as acute appendicitis: a case report. *World J Emerg Surg.* 2009;4:29.
8. Portier F. Diverticulite et appendicite. *Bull Mem Soc Anat Paris.* 1912;37:29-31.
- 9 Telem DA, Buch KE, Nguyen SQ, Chin EH, Weber KJ, Divino CM. Current recommendations on diagnosis and management of right-sided diverticulitis. *Gastroenterol Res Pract.* 2009;2009:359485.
10. Papapolychroniadis C, Kaimakis D, Fotiadis P, Karamanlis E, Stefopoulou M, Kouskouras K, Dimitriadis A, Harlaftis N: Perforated diverticulum of the caecum. A difficult preoperative diagnosis. Report of 2 cases and review of the literature. *Tech Coloproctol.* 2004, 8 (Suppl 1): s116-118. 10.1007/s10151-004-0129-6.
11. Chiu JH, Lin JT, Lin JK, Leu SY, Liang CL, Wang FM. Diverticular disease of the colon. *J Surg Asso.* 1987;20:102-8.
12. Birnbaum BA, Wilson SR. Appendicitis at the millennium. *Radiology.* 2000;215:337-48.
13. Sauerland S, Lefering R, Neugebauer EAM. Laparoscopic versus open surgery for suspected appendicitis. *Cochrane Database Syst Rev.* 2004;4:CD001546.
14. Li JCM, Ng SSM, Lee JFY et al. Emergency laparoscopic-assisted versus open right hemicolectomy for complicated cecal diverticulitis: a comparative study. *Journal of Laparoendoscopic and Advanced Surgical Techniques,* 2009, 19(4):479-483.
15. Oudenhoven LF, Koumans RK, Puylaert JB. Right colonic diverticulitis: US and CT findings—new insights about frequency and natural history. *Radiology.* 1998;208(3):611-618.
- 16 Jang H-J, Lim HK, Lee SJ, Choi SH, Lee MH, Choi MH. Acute diverticulitis of the cecum and ascending colon: thin-section helical CT findings. *American Journal of Roentgenology.* 1999;172(3):601-604.
17. Jang H-J, Lim HK, Lee SJ, Lee WJ, Kim EY, Kim SH. Acute diverticulitis of the cecum and ascending colon: the value of thin-section helical CT findings in excluding colonic carcinoma. *American Journal of Roentgenology.* 2000;174(5):1397-1402.
18. Ruiz-Tovar J, Reguero-Callejas ME, González Palacios F: Inflammation and perforation of a solitary diverticulum of the caecum. A report of 5 cases and literature review. *Rev Esp Enferm Dig.* 2006, 98 (11): 875-880.
19. Lane JS, Sarkar R, Schmit PJ, Chandler CF, Thompson JE: Surgical approach to cecal diverticulitis. *J Am Coll Surg.* 1999, 188 (6): 629-34. 10.1016/S1072-7515(99)00043-5.

20. Peltokallio P, Tykkä H, Myllärniemi H: Solitary diverticulum of the caecum and its complications. *Ann Chir Gynaecol Suppl.* 1977, 66 (5): 230-233.

21. Hall J, Hammerich K, Roberts P. New paradigms in the management of diverticular disease. *Curr Probl Surg.* 2010;47:680-735.

Abbreviations

CD: cecal diverticulitis, SCD: solitary cecal diverticulitis, RIF: right iliac fossa, Io intraoperative