

Buccal One-Stage Mucosal Graft Urethroplasty for Urethral Stricture. Results of 10 Years of Experience.

Gëzim Galiqi¹, Artan Koni¹, Flamur Tartari², Albert Pesha³, Shpëtim Ymeri¹, Luan Bajri¹, Shkëlqim Ferko⁴, Anton Ndoj⁴

Abstract

Aim: To represent our data regarding use of buccal mucosa for treatment of recurrent urethral stricture. Evaluating effectiveness of buccal graft for reconstruction of urethral segment both penile and bulbar urethra.

Materials and methods: We repaired 95 urethral strictures with buccal mucosa grafts from 2004 to 2015. Mean patient age was 39 years. The etiology of stricture was unknown in 54% of cases in other cases ischemia, trauma, instrumentation were the reason. 96% had undergone previous urethrotomy or dilation. The buccal mucosa graft was harvested from lower lip mostly. Mean graft length was 3.8 cm. The graft was placed on the ventral and dorsal bulbar urethral surface in 61 and 34 cases, respectively. In pendulous urethra we routinely use the dorsal graft the Asopa inlay graft or Barbagli onlay graft. Clinical outcome was considered a success or failure at the time that any postoperative procedure was needed, including dilation. Mean follow-up was 36 months (range 16 to 62).

Results: We had a success rate of 77% with dorsal inlay or onlay flap for pendulous urethra inferior than ventral graft used for bulbar urethra which was 81% success rate.

Conclusions: In our experience the placement of buccal mucosa grafts into the ventral or dorsal surface of the bulbar urethra showed an acceptable success rates 81% and 77% respectively. Longer times of follow up is need to see if the results deteriorated more.

Key words: urethral stricture, urethroplasty, buccal mucosa, buccal graft,

***Corresponding Author:** Gëzim Galilqi

✉ **Email:** gezimgaliqi@yahoo.com

¹Regional Hospital of Shkoder, Albania

²University Urologic Clinic, Tirana, Albania

³Regional Hospital of Fier, Albania

⁴Regional Hospital of Durres, Albania

Full Text

Introduction

Buccal mucosa graft (BMG) was first described for urethral reconstruction by Humby in 1941. (1). Most urologists commonly perform graft urethroplasty for strictures >2 cm. Buccal mucosa represents the first choice of ventral graft in the bulbar urethroplasty for strictures longer than 2 cm. The dorsal graft

placement can be performed by the Barbagli tecnic or the Asopa ones. The first consists in dissecting the urethra from the corpora cavernosa and its rotation of 180°; the exposed dorsal urethral surface is opened and augmented with the graft splayed on the corpora (*Figures 1,2*).

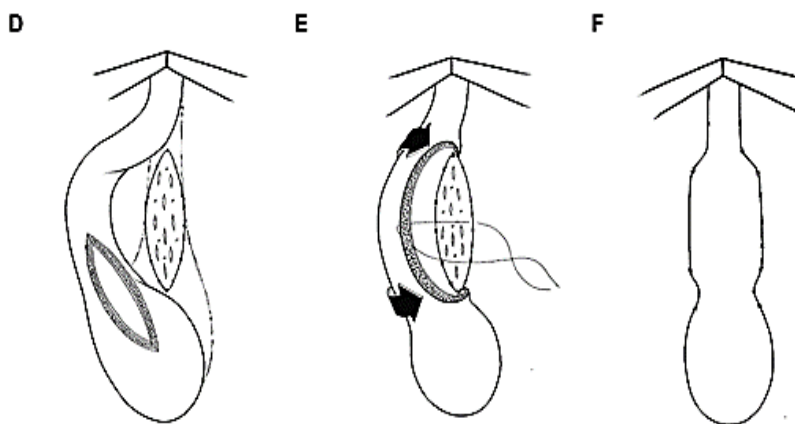


Figure 1

In the Asopa procedure the urethra is approached by a ventral-sagittal opening; subsequently, the dorsal urethra is medially incised to create an elliptical area over the corpora where the graft is placed. This approach is easy to

perform because the scarred urethra with marked spongiofibrosis is not mobilized and thereby the blood supply is guaranteed by the saved circumflex and perforating arteries (Figures 2, 3), [3].

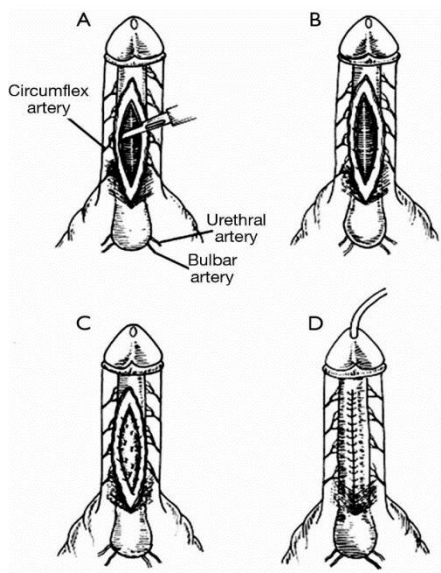


Figure 2

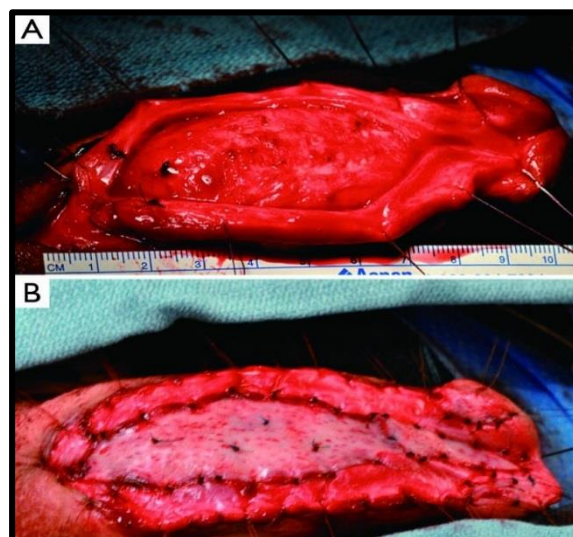


Figure 3

In 1996, Morey and McAninch fully described the ventral onlay buccal mucosa grafting urethroplasty[4], which we prefer for dorsal strictures.

Prior to the use of oral mucosa, penile skin was the preferred tissue-transfer material for urethroplasty. But oral mucosa is far superior from skin because it has some specific qualities (Figure 4).

- Buccal Mucosa Graft**

 - Easy to harvest
 - Easy to handle
 - Thick
 - Panlaminar vascular plexus – good take
 - Waterproof
 - Antibacterial
 - Resists skin diseases

Figure 4

Patients and methods

We repaired 95 urethral strictures with buccal mucosa grafts from 2004 to 2015

as a one-stage procedure. Initial patient work-up of the stricture includes a

urinary symptom review, uroflowmetry, and post-void residual measurement. Urinalysis to rule out infection was done routinely. Once strongly suspected, the most useful information comes from a retrograde urethrogram (RUG). This study, when performed correctly, i.e. penis on stretch and with oblique views, effectively identifies the location, number, and length of the stricture.

The other alternative procedure we did, was flexible cystoscopy.

Mean patient age was 39 years. The etiology of stricture was unknown in 54% of cases in other cases ischemia, trauma, instrumentation was the reason. 96% had undergone previous urethrotomy or dilation (*Table 1*).

Causes of strictures	Number of patients
Unknown	52 patient
Traumatic	16 patient
Ischiemic	7 patient
Catheterisation	14 patients
Infection	6 patients

Table 1

The lithotomy position with a mild head down tilt was used. All the patients had general anesthesia with endotracheal intubation following which prophylactic antibiotic was given.

The skin, subcutaneous tissue, and fats were dissected off the corpus spongiosus muscle on either side of the incision. A perineal ring retractor was then

positioned to maximize exposure. A midline incision similar to that of the skin was made on the corpus spongiosus muscle which was then dissected away from the underlying urethra and the retractor repositioned deeply. The buccal mucosa graft was harvested from lower lip mostly (*Figure 5*). Mean graft length was 3.8 cm.

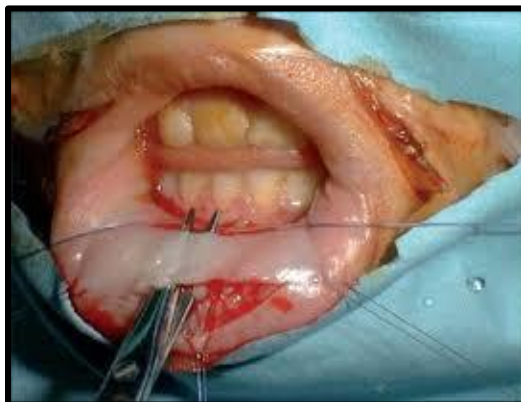

Figure 5

The graft was placed on the ventral and dorsal bulbar urethral surface in 61 and 34 cases, respectively. We used the ventral placement of buccal graft in bulbar urethra which represented the

vast majority of cases. While in penile urethra and meatal stenoses we used dorsal graft. We preferred the Barbagli dorsal approach in 25 cases. In 19 cases we used the Asopa inlay graft (*Table 2*).

Types of buccal graft procedures	Number of patients
Ventral onlay	61 patients
Asopa procedure	19 patient
Dorsal Barbagli onlay	25 patient

Table 2

We preferred to use the inlay graft when we saw that extensive fibrosis and fistula was present. We had two cases of fistula in penile urethra: one because of failed previous repair by end to end anastomosis, the other because of rupture of penile urethra due to motor

accident and subsequent trauma with fistula formation of penile urethra. In two meatal stenosis after previously failed dilatations, we used the inlay graft also.

In 61 cases ventral onlay graft was used in bulbar urethra. We did make much of

preparation laterally trying to open midline the strictured urethra after placement of guide-wire with cystoscopy and injection of blu-metilene to identify the urethra. Much of care was given placement of first stich deep in prostatic urethra to introduce well the buccal graft inside prostatic urethra.

Postoperatively, intravenous fluid, antibiotics as quinolones, and wet gauze pressure packing of the oral wound were continued. The antibiotic was continued orally for 14 days. Hexetidine mouth wash was resumed 24 h postoperative and was done following each meal. A silicone catheter was left in urethra for 21 days. A cystogram was done on 21-th postoperative day and if there was no extravasation the catheter was removed. Clinical outcome was considered a success or failure at the time that any postoperative procedure was needed, including dilation. Mean follow-up was 36 months (range 16 to 62).

Uroflowmetry was done routinely after 3 months and cystoscopy in 6 months. In cases of failure aurethrotomy was done and in 4 cases a second redo urethroplaty was performed.

Results

95 patients with mean age of 39 years underwent buccal mucosal graft urethroplasty. The etiology of the urethral stricture was unknown in 52 (54.7%), trauma in 16 (16.9%), ischemic in

7(7.4%), catheterization in 14 (14.7%), infection in 6 (6.3%). The strictures were located in penile urethra in 34 patients (35.8%), bulbar urethra in 61 (64.2%). The mean length of strictures was 3.8 cm. The previous treatments done for the patients included the following: urethrotomy in 78 (82.10%), dilatation in 8 (8.42 %), and urethroplasty in 9 (9.48%). 36 patients (37.9%) had at least 2 unsuccessful urethrotomies performed.

With mean follow-up time of 36 range (16 to 62) months, overall success rate was near 80% . We had a success rate of 77% with dorsal inlay or onlay flap for pendulous urethra inferior than ventral graft used for bulbar urethra which is 81%.

Overall postoperative complications were wound infection in 6 (6.31%), ring stenosis resulting in urethrotomy in 12 (12.63%) meatal stenosis in 4 (4.21%), and mild chordee in 3 (3.1%). There were no erectile dysfunction or urinary incontinence. Three patients (3.1%) experienced paresthesia in their lower extremities after the operation, which resolved during the hospitalization period. Minor buccal discomfort occurred in 18 patients (18.9%) after surgery but all of them became symptom-free during their follow up. We did not meet any major bleeding during the procedure and we did not need any blood transfusion during the procedure and in postoperative period.

Discussion

In our experience in 54% of cases there was no obvious cause of stricture and it may be higher in special locations as Barbagli reported 65.3% of bulbar strictures with unknown etiology (5). Other causes such as catheterisation, postinflammatory and trauma are less frequent. We did not include in our series lichen sclerosus and hypospadias which represent another challenge to be faced with. Dilation and urethrotomy continue to be the most commonly used techniques, but their failure rates are high with recurrence in 47.6% of patients and many patients progress to surgical repair. Moreover, repeated dilation or urethrotomy exacerbates scar formation, thus adding to stricture length and predisposing to a more difficult definitive open repair and a lower success rate (6, 7). We face this problem in our experience. More than 40% of cases had two or more than two internal urethrotomies, which we think represent a real challenge for grafting and long-term results due to extensive spongiofibrosis. A recent survey showed that 57.8% of urologists do not perform urethroplasty, whereas 31-33% would continue to manage the stricture by minimally invasive means, despite predictable failure, and most of them believed that the literature supports the use of urethroplasty only after repeated endoscopic failure (8).

Open urethroplasty using buccal graft is the gold standard treatment for urethral strictures. Buccal mucosa is hairless with a thick elastin-rich epithelium and a thin and highly vascular lamina propria; also its use avoids cosmetic disadvantages and consequences caused by the use of genital skin (5). The surgical technique for penile urethral reconstruction is basically selected according to the etiology of the urethral stricture disease and to stricture length. BMG urethroplasty is the most widespread method for the repair of long strictures in the bulbar urethra, but the location of the graft on the urethra surface (dorsal versus ventral) has become a contentious issue. In Barbagli's experience, the placement of the grafts on the ventral, dorsal, or lateral surface of the bulbar urethra provided the same success rates (83% to 85%) and stricture recurrence was uniformly distributed in all patients (9). In our experience the success rate dropped to 77% due to extensive fibrosis and inflammation but in most cases a later internal urethrotomy was needed. Only in 4 cases we redo the buccal graft again.

Conclusions

In our experience the placement of buccal mucosa grafts into the ventral or dorsal surface of the bulbar urethra showed an acceptable success rates 81% and 77% respectively. Treatment of failure can be done by internal

urethrotomy in majority of cases. In 4 cases we needed to redo the graft procedure. For bulbar stricture the ventral graft is a good alternative, while for penile urethra dorsal Barbagli or inlay Asopa remains the preferred procedure in our experience. Longer times of follow up is need to see if the results deteriorated more.

References

1. Humby G. A one-stage operation for hyposadius repair. *Br J Surg.* 1941;29:84-92.
2. Barbagli, G., Palminteri, E., Guazzoni, G. et al. Bulbar urethroplasty using buccal mucosa grafts placed on the ventral, dorsal or lateral surface of the urethra: are results affected by the surgical technique? *J Urol.* 2005; 174: 955-958.
3. Asopa, H.S., Garg, M., Singhal, G.G., Singh, L., Asopa, J., and Nischal, A. Dorsal free graft urethroplasty for urethral stricture by ventral sagittal urethrotomy approach. *Urology.* 2001; 58: 657-659.
4. Morey, A.F. and McAninch, J.W. When and how to use buccal mucosal grafts in adult bulbar urethroplasty. *Urology.* 1996; 48: 194-198.
5. Barbagli G., Sansalone S., Djinovic R., Romano G., Lazzeri M. Current controversies in reconstructive surgery of the anterior urethra: a clinical overview. *International Brazilian Journal of Urology.* 2012;38 (3):307-316.
6. Peterson A. C., Webster G. D. Management of urethral stricture disease: developing options for surgical intervention. *International Brazilian Journal of Urology.* 2004;94(7):971-976.
7. Greenwell T. J., Castle C., Andrich D. E., MacDonald J. T., Nicol D. L., Mundy A. R. Repeat urethrotomy and dilation for the treatment of urethral stricture are neither clinically effective nor cost-effective. *Journal of Urology.* 2004;172(1):275-277.
8. Bullock T. L., Brandes S. B. Adult anterior urethral strictures: a national practice patterns survey of board certified urologists in the United States. *Journal of Urology.* 2007;177(2):685-690.
9. Barbagli G., Palminteri E., Guazzoni G., Montorsi F., Turini D., Lazzeri M. Bulbar urethroplasty using buccal mucosa grafts placed on the ventral, dorsal or lateral surface of the urethra: are results affected by the surgical technique? *Journal of Urology.* 2005;174(3):955-957.