

Original Article

Asian Pacific Journal of Tropical Biomedicine

journal homepage: www.apjtb.org



doi: 10.4103/2221-1691.271722

Impact factor: 1.59

Kelulut honey ameliorates glucocorticoid induced osteoporosis *via* its antioxidant activity in ratsMohd Amir Kamaruzzaman¹, Amardev Thanu¹, Mohd Rafizul Yusof¹, Ima Nirwana Soelaiman², Elvy Suhana Ramli¹✉¹Department of Anatomy, Faculty of Medicine, UKM Medical Centre, Canselor Tuanku Mukhriz Hospital, Jalan Yaacob Latiff, 56000, Cheras, Kuala Lumpur, Malaysia²Department of Pharmacology, Faculty of Medicine, UKM Medical Centre, Canselor Tuanku Mukhriz Hospital, Jalan Yaacob Latiff, 56000, Cheras, Kuala Lumpur, Malaysia

ARTICLE INFO

Article history:

Received 12 June 2019

Revision 11 July 2019

Accepted 10 November 2019

Available online 11 December 2019

Keywords:

Kelulut honey

Glucocorticoid-induced osteoporosis

Oxidative stress

Antioxidant

Bone structure

Histomorphometry

Male rats

ABSTRACT

Objective: To explore the effects of kelulut honey on bone structure and histomorphometry against glucocorticoid-induced osteoporosis.**Methods:** Thirty-five male rats were used ($n = 7$). Twenty-eight adrenalectomized rats were divided into four groups; each group was given normal saline 0.9% (negative control), calcium water (positive control), kelulut honey (200 mg/kg/day and 400 mg/kg/day, respectively) treatment, respectively. All of them were administered with intramuscular injection of dexamethasone (120 µg/kg/day) to induce osteoporosis. Seven sham operated rats were given vehicle palm olein 0.05 mL/100 g/day by intramuscular injection and 0.1 mL/kg/day orally. All the treatments were given daily for 2 month. Lipid peroxidation and oxidative stress enzymes were measured. In addition, bone structural and histomorphometry analyses were also conducted.**Results:** Two-month glucocorticoid treatment increased the level of malondialdehyde and decreased superoxide dismutase significantly. No significant changes were found in the activities of catalase and glutathion peroxidase. Bone volume/tissue volume and trabecular number were significantly reduced while trabecular separation of the femoral bones was increased which corresponded to the decreased number of osteoblast surface after two months of receiving glucocorticoid treatment. Kelulut honey treatment restored the level of superoxide dismutase and reduced malondialdehyde significantly ($P < 0.05$). Moreover, kelulut honey increased bone volume/tissue volume, trabecular number and decreased trabecular separation significantly ($P < 0.05$), which were further confirmed by increased osteoblast surface and decreased osteoclast surface number ($P < 0.05$).**Conclusions:** Kelulut honey may have potential bone protective effect, and may be a prophylaxis against glucocorticoid-induced osteoporosis.

1. Introduction

Glucocorticoid induced osteoporosis is the most frequently reported secondary osteoporosis[1], characterized by decreased bone formation and with an early but transient increase in bone re-sorption by directly affecting osteoblast, osteocytes and osteoclast

involving in bone remodelling[2]. Cumulation of chronic use of glucocorticoid on bone cells causes a reduction in bone formation and increase in bone re-sorption therefore prompting deterioration in bone strength[3]. Over time, trabecular bone loss including

This is an open access journal, and articles are distributed under the terms of the Creative Commons Attribution-Non Commercial-ShareAlike 4.0 License, which allows others to remix, tweak, and build upon the work non-commercially, as long as appropriate credit is given and the new creations are licensed under the identical terms.

For reprints contact: reprints@medknow.com

©2019 Asian Pacific Journal of Tropical Biomedicine Produced by Wolters Kluwer-Medknow. All rights reserved.

How to cite this article: Kamaruzzaman MA, Thanu A, Yusof MR, Soelaiman IN, Ramli ES. Kelulut honey ameliorates glucocorticoid induced osteoporosis *via* its antioxidant activity in rats. Asian Pac J Trop Biomed 2019; 9(12): 493-500.

✉Corresponding author: Elvy Suhana Mohd Ramli, Department of Anatomy, Faculty of Medicine, UKM Medical Centre, Canselor Tuanku Mukhriz Hospital, Jalan Yaacob Latiff, 56000, Cheras, Kuala Lumpur, Malaysia.
Tel: +60391458605
Fax: +60391458607

E-mail: elvysuhana@ukm.edu.my

Funding: This work was supported by Universiti Kebangsaan Malaysia, Malaysia through grant FF-2017-447.

vertebral and femoral neck is most often affected with subsequent risk of osteoporotic fracture[4]. The consequence of osteoporotic fragility fracture is one of the worst side effects involving 30%-50% of patients taking long-term systemic glucocorticoids[5].

Oxidative stress may play an important role in the pathogenesis of age-related bone loss[6]. However, increase in oxidative stress is accelerated by the increase in the duration of glucocorticoid treatment[7]. Glucocorticoid promotes inflammatory cytokines like tumour necrosis factor alpha[8], increased rate of bone loss and risk of fracture[9] by exerting direct effect on signaling molecules of bone remodelling mediated largely through up-regulation of peroxisome proliferator-activated receptor gamma receptor 2[10]; suppression of Wnt/ β catenin signaling pathway in osteoblast[11]; induction of apoptosis in osteocyte[12]; stimulation of macrophage colony stimulating factor and receptor activator of nuclear factor kappa-B ligand in osteoclast[13].

Honey contains phenolic compound which acts as a natural antioxidant and becomes increasingly interesting because of its high potential in contributing to the health benefits[14]. Due to the high content of antioxidants, many studies have been conducted by researchers to uncover the benefits of honey[15]. Despite several studies regarding honey related antioxidant property on bone metabolism have been done, further evaluation of bone structure and histomorphometry after prolonged glucocorticoid is not well established.

Kelulut honey is a name known by Malaysian and some Asian region which is referring to the stingless bee honey. It is produced by bees without a sting from the species of *Trigona*. Kelulut honey is more liquid than other honey and it has a slightly sour taste with a distinctive odour[16]. Given the high antioxidant properties, the opportunity of kelulut honey to be used as a protective agent is very encouraging[17]. Previous study proved antibacterial and antioxidant properties of kelulut honey, suggesting its potential to be used as a treatment and as a supplement[18]. This study was aimed at determining the potential effect of kelulut honey in protecting bone from osteoporosis at cellular and microstructure levels and against oxidative stress induced by two-month glucocorticoid treatment *via* its antioxidant activity.

2. Materials and methods

2.1. Materials

Dexamethasone sodium phosphate (Dexamethasone[®]), a glucocorticoid agent used in this study was supplied by Sigma Chemical Company (USA). Kelulut honey was taken from kelulut honey Farm (Gombak, Malaysia).

2.2. Experimental design

The study protocol was approved by The Universiti Kebangsaan Malaysia Animal Ethics Committee (UKMAEC) in 2017 (Approval no. ANAT/PP/2017/ELVY/27-SEPT./870-OCT.-2017-SEPT.-2018) in accordance with the guidelines established by the Institutional Animal Care and Use Committee (IACUC). A total of 35 three-month-old male Sprague-Dawley rats weighing 220-250 g were obtained from the Animal House, Universiti Kebangsaan Malaysia, Malaysia. Rats were given rat chow obtained from Gold Coin Pte. Ltd (Singapore). Normal saline drink was given for adrenalectomized rats. After acclimatization for two weeks, the rats were divided into five groups ($n = 7$). After being anesthetized, adrenalectomy (removal of adrenal

gland) procedure was done by incision of the dorsal midline skin and bilateral flank muscle to visualize the adrenal glands. Rats underwent adrenalectomy to avoid false endogenous stimulation of glucocorticoid. Both adrenal glands were identified and vessels supplying them were ligated to secure the bleeding before they were removed. Every bleeding area was checked and stopped by ligation before wound closure. The incisions were sutured at muscular layer followed by skin layer and then cleaned with normal saline. The wound was cleaned daily for five d by applying povidone iodine (Povidern[®]) Cream (Hoe Pharmaceuticals, Malaysia) to prevent infection. Enrofloxacin (Baytril[®] 5%) (Bayer Health Care, Thailand) is an antibiotic, and was given *via* intramuscular injection for 5 d to the rats as a prophylaxis against infection[19]. The glands were examined histologically for confirmation. The sham-operated rats underwent a similar procedure except that the adrenal glands were left *in-situ*.

One group was sham-operated (sham group) and was given vehicle *via* oral gavage 0.1 mL/kg/day and olein vehicle intramuscularly 0.05 mL/100 g/day. The four adrenalectomized treatment groups received 0.1 mL/100 g of normal saline 0.9% (negative control group), 200 and 400 mg/kg/day of kelulut honey, respectively *via* oral gavage, and 2% of calcium water (positive control group) *via* supplemental drink. All adrenalectomized treatment groups were administered with dexamethasone 120 μ g/kg/day intramuscularly. The treatment continued for 8 weeks with one day break in the weekend according to Elvy Suhana *et al*[19]. The adrenalectomy and sham operation procedures were conducted under anaesthesia using 90 mg/kg ketamine (Ketalar[®]) (Troy Laboratories, Pty Ltd, Australia) and 10 mg/kg xylazine HCL (Xylazil-100[®]) (Troy Laboratories, Pty Ltd, Australia). The rats were sacrificed 24 hours after the last dose of treatment under excess ketamine anaesthesia (100 mg/kg).

2.3. Sample collection

Both femurs were cleared from soft tissues. The right femurs were wrapped in gauze soaked with phosphate buffered saline and frozen at -80 °C until use for structural analysis by micro-CT imaging. The left femurs were cut at the mid-shaft with a rotary blade (Black & Decker) to separate the proximal and distal halves. The proximal half was used for analysing oxidative stress enzymes while the distal half was cut longitudinally to separate the bones into medial and lateral sections for histomorphometry analysis.

2.4. Lipid peroxidation and oxidative stress enzyme

Oxidative stress enzymes were measured using bone homogenates which were homogenized and then processed according to the procedures given by the manufactures. Oxidative stress enzymes including superoxide dismutase (SOD), catalase (CAT) and glutathione peroxidase (GPx) were analysed using ELISA kits (Cayman Chemical Company, USA). Malondialdehyde (MDA) was measured for lipid peroxidation activity by using the ELISA kit (BioVision Incorporated, USA)[20].

2.5. Bone structural analysis (micro-CT)

For the measurements of the structural bone parameter, the undecalcified samples were sent for imaging using micro-CT scanner machine produced by Bruker Corporation, USA. The images of each bone sample were captured for evaluation of the structure at the area of

metaphyseal region of distal femur. The structural parameters included tissue volume, bone volume/tissue volume (BV/TV), trabecular bone thickness (Tb.Th), trabecular bone number (Tb.N), and trabecular bone separation (Tb.Sp)[21]. Images were reconstructed using installed NRecon™ software followed by the analysis to obtain quantitative information on the bone structure with CTAn™ software (Bruker, Belgium).

2.6. Histomorphometric analysis

Distal sections of longitudinally cut left femurs were first fixed in 10% formalin. After that, they were decalcified by emersion in 10% ethylenediaminetetraacetic acid solution for two months. The decalcified bone samples were embedded in paraffin wax, sectioned longitudinally into a thickness of 5–6 µm using microtome (Leica RM2235, Nussloch, Germany), and stained using haematoxylin and eosin. The sections were visualized under a light microscope (Nikon Eclipse 80i, Tokyo, Japan)[21]. The static histomorphometric parameters including osteoblast surface (Ob.S/BS) and osteoclast surface (Oc.S/BS) were measured using the Weibel technique using M42 grid adjusted on the captured image and calculated. The number of hit points ('hits') and the total number of lines cut ('intercepts') were also calculated and compared to that of references *i.e.* total volume or tissue surface[22].

Measurement of both structural and histomorphometric parameters of bone was randomly performed at the metaphyseal region, which was located 3–7 mm from the lowest point of the growth plate and 1 mm from the lateral cortex, excluding the endocortical region. The

selected area which was rich in trabecular bone was the secondary spongiosa area[23].

2.7. Statistical analysis

Statistical analysis was performed using the Statistical Package for Social Sciences (SPSS) version 20 (IBM, Armonk, NY, USA). The dependent variables were normally distributed based on the Shapiro-Wilk test ($P > 0.05$) along with skewness and kurtosis z-values. This allowed for the comparison of all parameters among the study groups to be performed using one-way analysis of variance (ANOVA) with Tukey's HSD *post hoc* test, followed by the independent sample *t* test to measure statistical difference between the means of the two groups. All data were presented as mean ± SD. A *P*-value less than 0.05 was considered statistically significant.

3. Results

3.1. Lipid peroxidation and oxidative stress

Two-months of dexamethasone treatment significantly reduced the SOD activity in the femur ($P = 0.000$). However, CAT and GPx activities had no significant difference compared with sham group. There was an increase in lipid peroxidation as shown by a significant increase in MDA level in the bone ($P = 0.023$). The groups treated with 200 and 400 mg/kg of kelulut honey had significantly higher SOD activity ($P = 0.005$ and $P = 0.001$, respectively) and lower

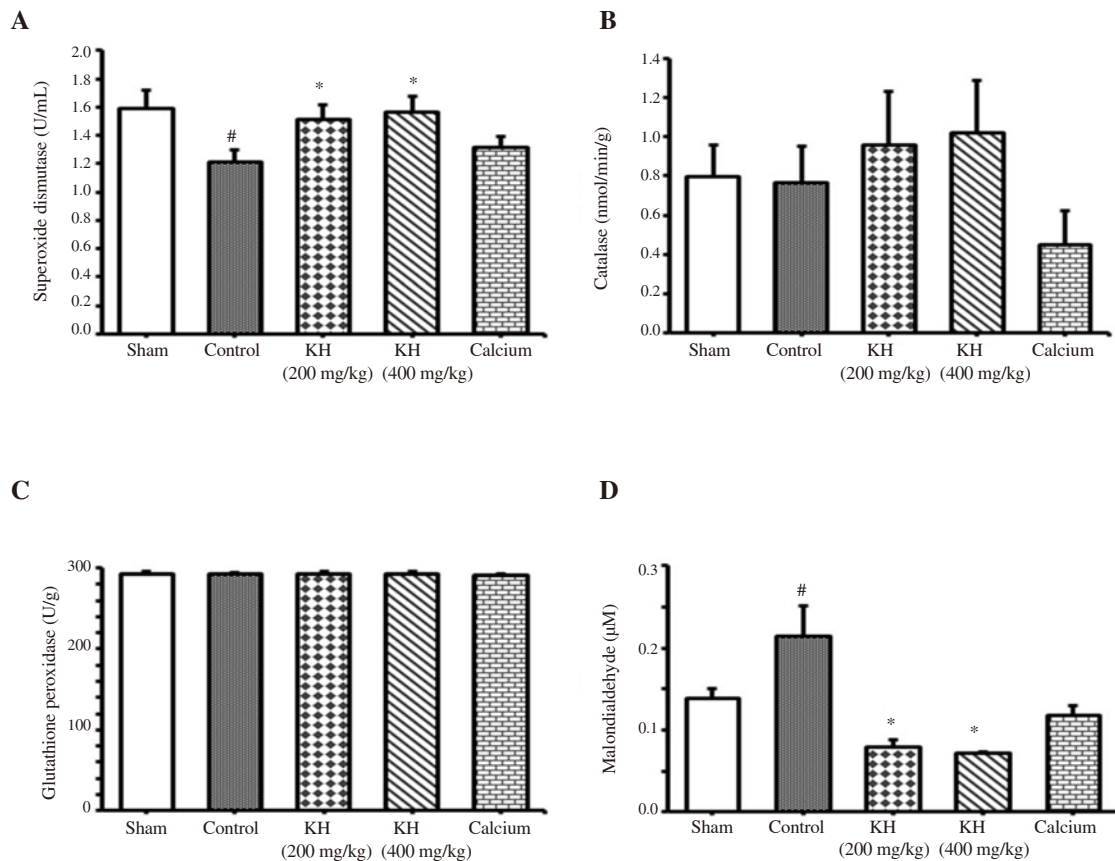


Figure 1. Activities of superoxide dismutase (A), catalase (B), glutathione peroxidase (C) and malondialdehyde (D) in homogenized bones of all experimental groups. Data were expressed as mean ± SD ($n = 7$); # $P < 0.05$ vs. the sham group; * $P < 0.05$ vs. the control group. KH: kelulut honey.

MDA activity ($P = 0.000$) compared to the control group, whereas the treatment did not change CAT and GPx activities significantly (Figure 1).

3.2. Bone structural parameter (micro-CT)

Figure 2 presents the bone structural values. The BV/TV ($P = 0.000$) and Tb.N ($P = 0.03$) were significantly reduced and the Tb.Sp was significantly increased ($P = 0.01$) after 2 months in the control group compared to sham group. However, Tb.Th did not show any significant changes. By comparing with the control group, the groups treated with 200 and 400 mg/kg of kelulut honey significantly increased the BV/TV and decreased Tb.Sp. A significant increase was found in Tb.N in the group which received 400 mg/kg of kelulut honey ($P = 0.02$) while in Tb.Th with 200 mg/kg of kelulut honey treatment ($P = 0.04$). The changes in bone structural parameters were further evidenced by qualitatively evaluating the images of bone when comparing the kelulut honey-treated and the control groups by

micro-CT (Figure 3).

3.3. Bone histomorphometry

Dexamethasone caused a significant decrease in the Ob.S/BS ($P = 0.015$), but with no significant change in the Oc.S/BS compared to the sham group. Both kelulut honey treatment groups significantly increased the Ob.S/BS ($P = 0.000$) and decreased the Oc.S/BS ($P = 0.016$ and $P = 0.028$, respectively) compared to the control group. In addition, there was no significant difference in the Ob.S/BS and the Oc.S/BS of both kelulut honey groups compared to the sham group (Figure 4). The histological images of bone were captured (Figure 5). Dexamethasone limited the number of bone-forming cells which were replaced by the fatty tissues. However, kelulut honey was able to preserve bone cellularity upon bone remodelling by maintaining the density and the number of osteoblasts with the greater distribution of the bone matrix.

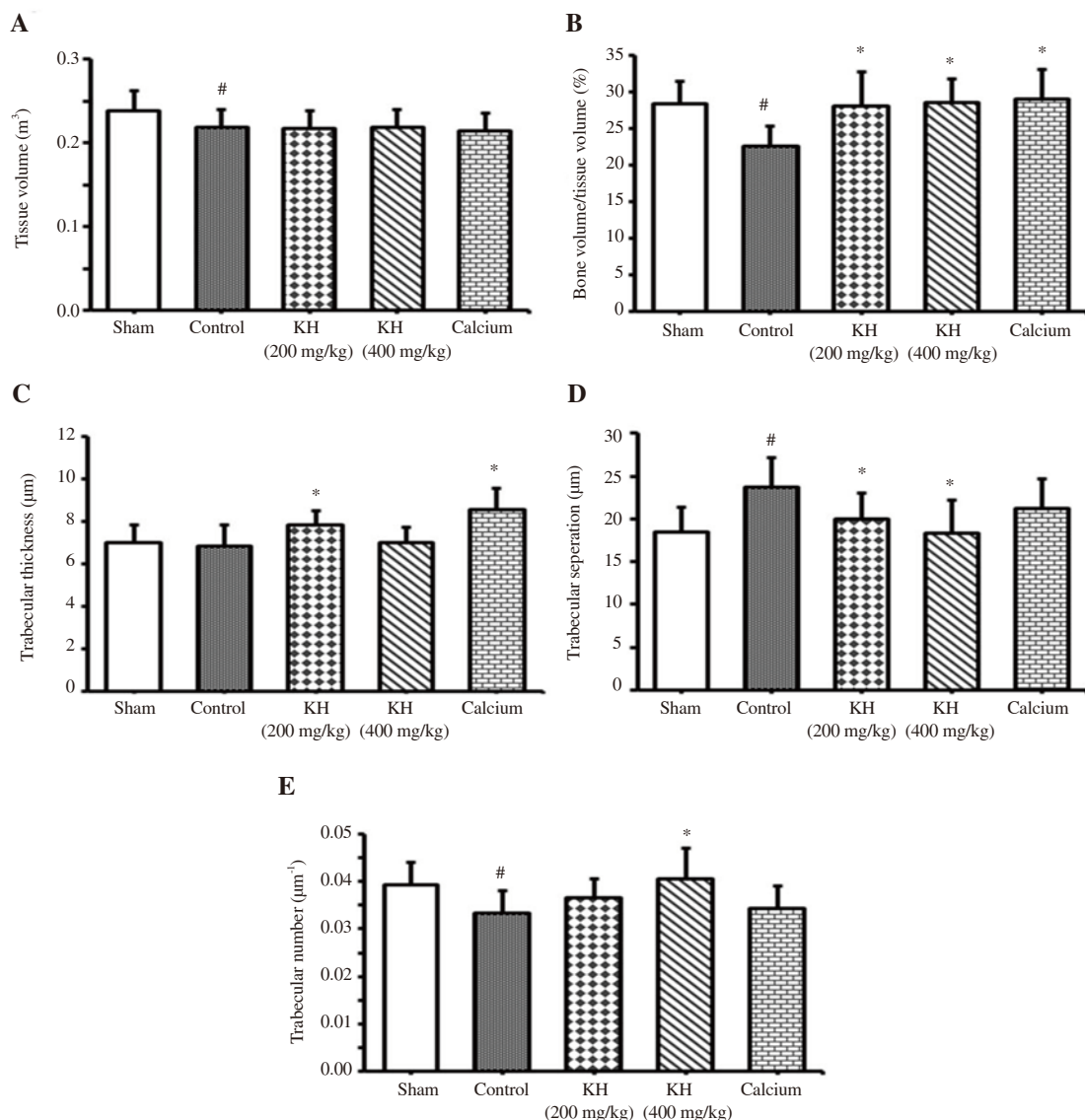


Figure 2. Bone structural parameters in all experimental groups. (A) Tissue volume; (B) bone volume/tissue volume; (C) trabecular thickness; (D) trabecular separation; (E) trabecular number. The region of interest was performed at the metaphyseal region. Data were expressed as mean \pm SD ($n = 7$); [#] $P < 0.05$ vs. the sham group; ^{*} $P < 0.05$ vs. the control group. KH: kelulut honey.

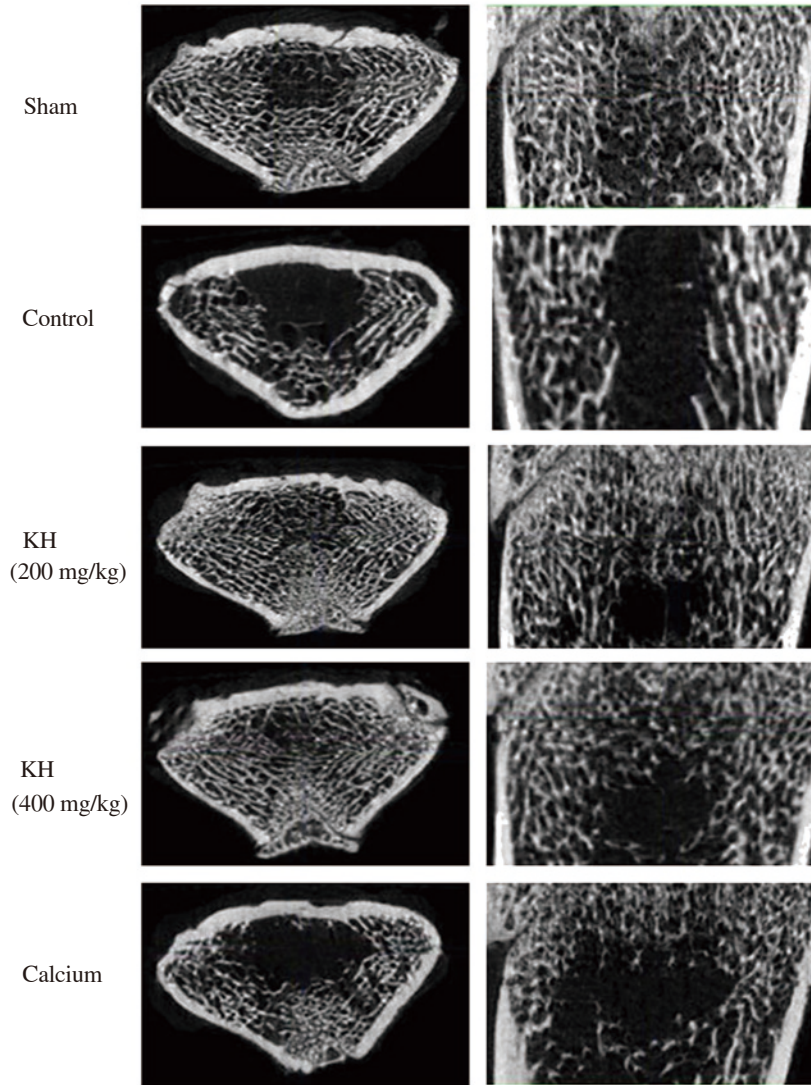


Figure 3. Bone structure in the metaphysis of distal femur in all experimental groups. Images captured by micro-CT in the left column are presented in transverse section while in the right column are in coronal section. Compared with the sham group, the trabeculae in the metaphysis of distal femur becomes sparse in the control group, whereas it becomes dense in groups treated with kelulut honey (KH).

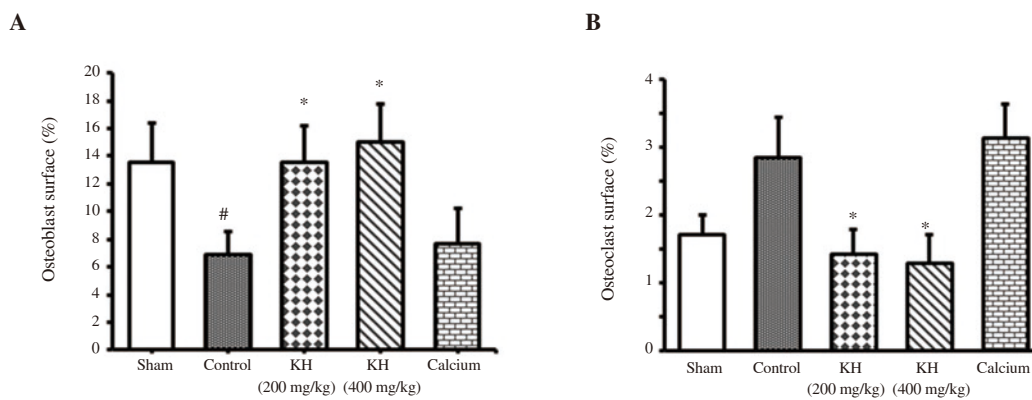


Figure 4. Osteoblast surface (A) and osteoclast surface (B) in all experimental groups. Data were expressed as mean \pm SD ($n = 7$); * $P < 0.05$ vs. the sham group; # $P < 0.05$ vs. the control group. KH: kelulut honey.

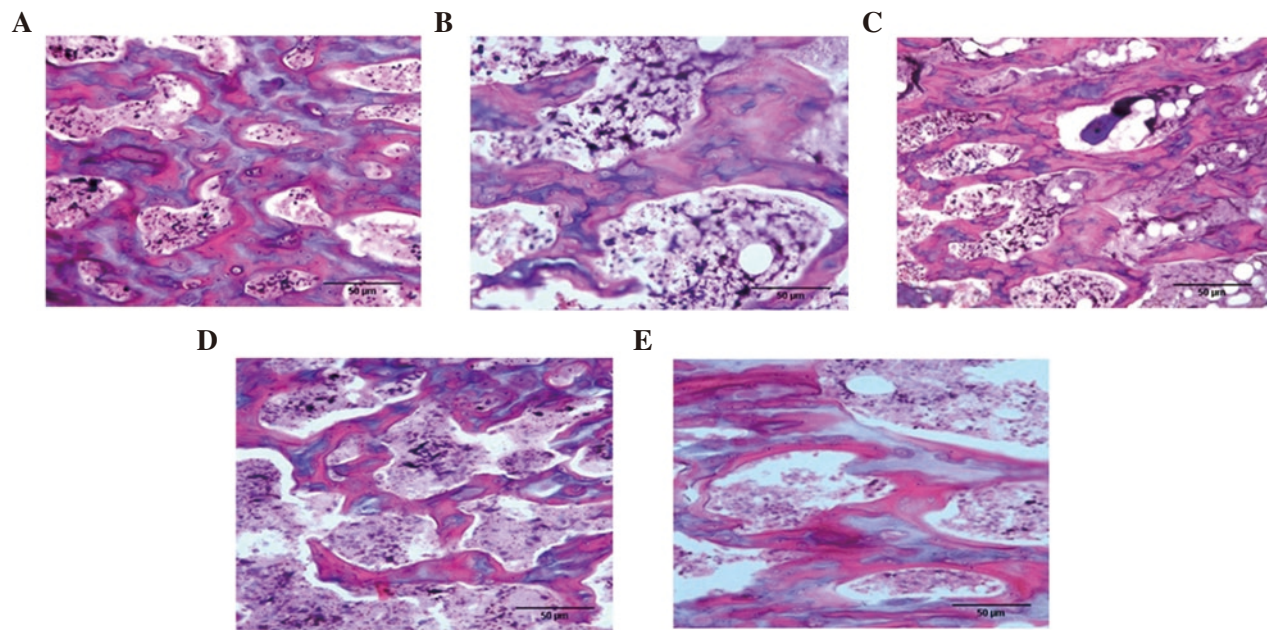


Figure 5. Decalcified bone with haematoxylin and eosin staining under $\times 100$ magnification with 50-micron bar scale in the metaphysis of distal femur in all experimental groups by static bone histomorphometry. The control group (Figure 5E) has less osteoblast number but more in osteoid compared to the sham group (Figure 5B). Number of bone cells on the bone surfaces in rats receiving kelulut honey treatment is similar to that of the sham group (Figure 5A, 5C).

4. Discussion

The decreased SOD activity in this study suggested the deleterious component of two-month dexamethasone exposure which may cause excessive superoxide radicals demonstrated by the increased lipid peroxidation process shown by an increase in MDA. Together, a low SOD activity and a high level of MDA might have increased oxidative stress level, exposing the bone to oxidative damage. The findings were consistent with the other previous comparable studies in human with osteoporosis. Sontakke & Tare reported an increase in MDA and a decrease in SOD's antioxidant enzyme in parallel with most studies linking osteoporosis with increased lipid-peroxidation[24]. It was found that women with osteoporosis had high MDA levels and low GPx and CAT activities compared to non-porotic controls[25]. SOD was found to be significantly lower in postmenopausal women without hormone replacement therapy[26]. In the animal study, decreased SOD, as well as increased GPx and MDA activities were found in glucocorticoid-induced osteoporotic bone of adrenalectomized rats[27].

Dexamethasone resulted in significant bone loss and bone structural changes by a decrease in BV/TV and Tb.N, as well as an increase in Tb.Sp. The findings in this study are in line with the study reported by Soelaiman *et al.*[20]. Elvy Suhana *et al.*, found a greater impact of dexamethasone suppression which caused a reduction not only on BV/TV and Tb.N but also on Tb.Th parameters[19]. In other animal study, dexamethasone caused damages to the microstructure of the proximal femoral bone by decreasing Tb.Th, Tb.N, BV/TV, Conn D, and increasing Tb.Sp and structure model index[28]. Significant deleterious changes were observed in BV/TV, Tb.N and Tb.Sp in Pb exposure group in a study that combined the effect of stress and lead (Pb) on bone quality associated with alterations in glucocorticoid signaling. Interestingly, the co-exposure of stress and Pb amplified the adverse effect in those bone parameters similar to the glucocorticoid treatment group, suggesting that bone loss associated with steroid-induced

osteoporosis is a consequence of sclerostin-mediated restriction of Wnt signaling[29]. In the postmenopausal women treated with 3 months of oral glucocorticoid, trabecular microarchitecture was deteriorated in radial bone, with lower trabecular number and thickness as well as greater separation compared with the control subject[30].

An increase in the Oc.S/BS and a decrease in the Ob.S/BS after two-month glucocorticoid exposure are consistent with the results in the study by Soelaiman *et al.*[20]. Different susceptibilities to glucocorticoid-induced oxidative stress had increased osteoclast activity and endurance, whereas osteoblasts decreased in lifetime and apoptosis[31]. Other studies have found that excessive endogenous and exogenous glucocorticoid levels increase the number of osteoclasts and reduce the number of osteoblasts. Osteoblast apoptosis[32], by downregulating the expression of osteogenic genes like runt-related transcription factor 2 (Runx2) and osterix (Osx)[33] had caused the reduction of osteoblast precursors.

Kelulut honey treatment in rats receiving two-month dexamethasone caused a decrease in MDA activity in the rat's bones, indicating the reduction of lipid peroxidation. Increased SOD activity after kelulut honey treatment may have increased superoxide conversion into hydrogen peroxide which reduces superoxide anion levels to protect bone from free radicals and bone loss. The loss of bone mass may be overcome by ameliorating redox homeostasis to prevent osteoblast and osteocytes apoptosis while reducing osteoclast production[34]. These results are in agreement with previous study on the effect of honey on oxidative stress in ovariectomized rats[35], but inconsistent with the study on postmenopausal women[36]. Antioxidant protection on osteoblast cells by polyphenol (apigenin) may be achieved through the enhancement of PI3K molecular pathways, Akt and ERK2 and increased expression of antioxidant enzymes such as SOD-1, SOD-2 and GPx[37].

The administration of 400 mg/kg kelulut honey reversed the changes induced by dexamethasone in BV/TV, Tb.N, and Tb.Sp. In this study,

the bone structural parameters in the kelulut honey treatment group might have provided antioxidant effects on bone microarchitecture. It was evidenced in previous animal study using Tualang honey that showed bone protective effects[23]. It was probably due to the osteo-anabolic effect with enhanced osteoblast activity. The reduction in osteoblast apoptosis may be due to reduced TNF- α and IL-6 mediated by nitric oxide, carbon monoxide and hydrogen sulphide[38]. The decreased Tb.Sp may also be caused by the NF- κ B signaling barrier that causes hindrance of the osteoclast differentiation process and decreases the bone re-sorption process[39]. The desired positive effect of kelulut honey may help to conserve bones by improving and maintaining bone microarchitecture against the negative effects of oxidative stress.

Kelulut honey treatment groups showed improvement in the number of Oc.S/BS and Ob.S/BS. The ability of antioxidant agents to prevent the occurrence of osteoblast apoptosis reinforces the underlying mechanism of osteoporosis by oxidative stress[40]. The increase in the number of Ob.S in this study may be due to the role of kelulut honey containing polyphenols as an antioxidant that can increase the differentiation of mesenchymal cells to the osteoblast and plays a role in cross-talk of signaling pathways such as Wnt, bone morphogenic protein, Forkhead box protein O3, Runx2, and Osx that stimulate bone development[41]. Some types of polyphenols were found to have target against the Wnt pathway in the bone by promoting the osteoblast differentiation[42], and preventing the function and differentiation of osteoclasts[43]. In general, various active metabolites of polyphenol may be present in the honey. Quercetin for example promoted the differentiation of osteoblasts by restoring mRNA and protein expression levels of osteoblast-specific genes such as Osx, Runx2, alkaline phosphatase and osteocalcin[44] while kaempferol inhibited autophagy and promoted apoptotic cell death and inhibited osteoclastogenesis in the RAW 264.7 cells[45].

Calcium supplementation in this study showed no significant difference in lipid peroxidation and oxidative stress compared with the control group. In bone structural analysis, calcium supplementation did not show any promising effect except for Tb.Th and BV/TV parameter. Furthermore, the effect of calcium was comparable to that of the control in static histomorphometry. This probably revealed the oxidative stress induced by dexamethasone could not be improved alone by regular calcium intake containing no antioxidants to offset the progress of osteoporosis.

Despite the favourable findings on kelulut honey above, further studies should be conducted regarding parameters such as bone forming and re-sorptive markers, dynamic histomorphometry, bone DEXA scan and bone biomechanical strength which will further validate the result of this study. Those parameters were not done due to limitation of samples and will be included in future study. Furthermore, in view of the sweetness of honey, rat's blood sugar level should have been measured pre and post treatment for any possibility of diabetes type II developed from the persistent kelulut honey intake.

In conclusion, we found that kelulut honey reduced oxidative stress by reducing lipid peroxidation and increasing SOD in this study. It also maintained bone structure, increased osteoblast and reduced osteoclast number. Therefore, kelulut honey could be used as a prophylactic agent to prevent glucocorticoid-induced osteoporosis.

Conflict of interest statement

We declare that there is no conflict of interest.

Acknowledgments

We thanks to all staffs in the Department of Anatomy and Department of Pharmacology, Faculty of Medicine, University Kebangsaan Malaysia for their kindness in cooperation to make this work successful. This study was supported by a grant funded by Universiti Kebangsaan Malaysia, Malaysia.

Funding

This work was supported by Universiti Kebangsaan Malaysia, Malaysia through grant FF-2017-447.

Authors' contributions

ESR conceived and planned the experiments. MAK carried out the experiments and contributed to sample preparation assisted by MRY and AST. MAK and ESR contributed to the interpretation of the results. MAK took the lead in writing the manuscript assisted by MRY and AST. During the manuscript writing, it was consulted with ESR and supervised by INS.

References

- [1] Briot K, Roux C. Glucocorticoid-induced osteoporosis. *Rheum Musculoskelet Dis* 2015; **1**(1). Doi: 10.1136/rmdopen-2014-000014.
- [2] Hardy RS, Zhou H, Seibel MJ, Cooper MS. Glucocorticoids and bone: Consequences of endogenous and exogenous excess and replacement therapy. *Endocr Rev* 2018; **39**(5): 519–548. Doi: 10.1210/er.2018-00097.
- [3] Sato AY, Peacock M, Bellido T. Glucocorticoid excess in bone and muscle. *Clin Rev Bone Miner Metab* 2018; **16**(1): 33–47. Doi: 10.1007/s12018-018-9242-3.
- [4] Saag K, Adler RA. Glucocorticoid-induced osteoporosis. In: JP Bilezikian (ed.) *Primer on the metabolic bone diseases disorder of mineral metabolism*. 9th Ed. New Jersey, USA: Wiley; 2018, pp. 467–473.
- [5] Buehring B, Viswanathan R, Binkley N, Busse W. Glucocorticoid-induced osteoporosis: An update on effects and management. *J Allergy Clin Immunol* 2013; **132**(5): 1019–1030. Doi: 10.1016/j.jaci.2013.08.040.
- [6] Zhang YB, Zhong ZM, Hou G, Jiang H, Chen JT. Involvement of oxidative stress in age-related bone loss. *J Surg Res* 2011; **169**(1): e37–42. Doi: 10.1016/j.jss.2011.02.033.
- [7] Costantini D, Marasco V, Møller AP. A meta-analysis of glucocorticoids as modulators of oxidative stress in vertebrates. *J Comp Physiol B* 2011; **181**(4): 447–456. Doi: 10.1007/s00360-011-0566-2.
- [8] Yang N, Baban B, Isaacs CM, Shi X. Role of glucocorticoid-induced leucine zipper (GILZ) in inflammatory bone loss. *PLoS One* 2017; **12**(8): 1–14. Doi: 10.1371/journal.pone.0181133.
- [9] Almeida M, Han L, Ambrogini E, Weinstein RS, Manolagas SC. Glucocorticoids and tumor necrosis factor α increase oxidative stress and suppress Wnt protein signaling in osteoblasts. *J Biol Chem* 2011; **286**(52): 44326–44335. Doi: 10.1074/jbc.M111.283481.
- [10] Shi XM, Chutkan N, Hamrick MW, Isaacs CM. Mechanism of glucocorticoid-induced osteoporosis: An Update. In: Qian XX (ed.) *Glucocorticoids—New recognition of our familiar friend*. Croatia: InTech; 2012.
- [11] Komori T. Glucocorticoid signaling and bone biology. *Horm Metab Res* 2016; **48**(11): 755–763. Doi: 10.1055/s-0042-110571.

- [12] Yao N, Dai WW, Jiang JX, Lane NE. Glucocorticoids and osteocyte autophagy. *Bone* 2013; **54**(2): 279–284. Doi: 10.1038/mp.2011.182.
- [13] Hachemi Y, Rapp AE, Hachemi Y, Rapp AE, Picke A, Weidinger G, et al. Molecular mechanisms of glucocorticoids on skeleton and bone regeneration after fracture. *J Mol Endocrinol* 2018; **61**(1): 75–90. Doi: 10.1530/JME-18-0024.
- [14] Parker P, Byrne RC, Hemsworth B. Relationships between polyphenols and antioxidant activity of honey produced by *Apis mellifera* and stingless bees (Meliponini). *Int J Med Plant Res* 2016; **5**(4): 234–243.
- [15] Khalil MI, Sulaiman SA, Boukraa L. Antioxidant properties of honey and its role in preventing health disorder. *Open Nutraceut J* 2010; **3**: 6–16.
- [16] Biluca FC, Braghini F, Gonzaga LV, Costa ACO, Fett R. Physicochemical profiles, minerals and bioactive compounds of stingless bee honey (Meliponinae). *J Food Compos Anal* 2016; **50**: 61–69. Doi: 10.1016/j.jfca.2016.05.007.
- [17] Saiful Yazan L, Muhamad Zali MF, Mohd Ali R, Zainal NA, Esa N, Sapuan S, et al. Chemopreventive properties and toxicity of Kelulut honey in sprague dawley rats induced with azoxymethane. *Biomed Res Int* 2016; **2016**: 4036926. Doi: 10.1155/2016/4036926.
- [18] Suntiropapop K, Prapaipong P, Chantawannakul P. Chemical and biological properties of honey from Thai stingless bee (*Tetragonula leaviceps*). *J Apic Res* 2012; **51**(1): 45–52. Doi: 10.3896/IBRA.1.51.1.06.
- [19] Elvy Suhana MR, Fariyah HS, Faizah O, Nazrun AS, Norazlina M, Norliza M, et al. P-HSD I dehydrogenase effect of glucocorticoid-induced osteoporotic male sprague-dawley rats. *Singapore Med J* 2011; **52**(11): 786–793.
- [20] Soelaiman IN, Mohd Ramli ES, Suhaimi F, Ahmad F. Potential benefits of annatto tocotrienol in glucocorticoid induced osteoporosis: An animal study. *J Osteoporos Phys Act* 2017; **5**(2): 1–10. Doi: 10.4172/2329-9509.1000203.
- [21] Wong SK, Chin KY, Suhaimi FH, Ahmad F, Ima-Nirwana S. Effects of metabolic syndrome on bone mineral density, histomorphometry and remodelling markers in male rats. *PLoS One* 2018; **13**(2): 1–15. Doi: 10.1371/journal.pone.0192416.
- [22] Soelaiman IN. Quantification of bone histomorphometric parameters using the weibel technique in animals. *Med Health* 2016; **11**(2): 278–288. Doi: 10.17576/mh.2016.1102.16.
- [23] Zaid SSM, Sulaiman SA, Othman NH, Soelaiman IN, Shuid AN, Mohamad N, et al. Protective effects of Tualang honey on bone structure in experimental postmenopausal rats. *Clinics* 2012; **67**(7): 779–784. Doi: 10.6061/clinics/2012(07)13.
- [24] Sontakke AN, Tare RS. A duality in the roles of reactive oxygen species with respect to bone metabolism. *Clin Chim Acta* 2002; **318**(1-2): 145–148. Doi: 10.1016/S0009-8981(01)00766-5.
- [25] Ozgocmen S, Kaya H, Fadillioglu E, Aydogan R, Yilmaz Z. Role of antioxidant systems, lipid peroxidation, and nitric oxide in postmenopausal osteoporosis. *Mol Cell Biochem* 2007; **295**(1-2): 45–52. Doi: 10.1007/s11010-006-9270-z.
- [26] Unfer TC, Conterato GMM, da Silva JCN, Duarte MMMF, Emanuelli T. Influence of hormone replacement therapy on blood antioxidant enzymes in menopausal women. *Clin Chim Acta* 2006; **369**(1): 73–77. Doi: 10.1016/j.cca.2006.01.006.
- [27] Mohd Ramli ES. Protective effects of palm tocotrienol against glucocorticoid induced osteoporosis via regulation of gene expressions. *Med Health* 2018; **13**(1): 175–197. Doi: 10.17576/mh.2018.1301.17.
- [28] Liu S, Yang L, Mu S, Fu Q. Epigallocatechin-3-gallate ameliorates glucocorticoid-induced osteoporosis of rats *in vivo* and *in vitro*. *Front Pharmacol* 2018; **9**: 447. Doi: 10.3389/fphar.2018.00447.
- [29] Beier EE, Sheu TJ, Resseguie EA, Takahata M, Awad HA, Cory-Slechta DA, et al. Sclerostin activity plays a key role in the negative effect of glucocorticoid signaling on osteoblast function in mice. *Bone Res* 2017; **5**: 17013. Doi: 10.1038/boneres.2017.13.
- [30] Sutter S, Nishiyama KK, Kepley A, Zhou B, Wang J, McMahon DJ, et al. Abnormalities in cortical bone, trabecular plates, and stiffness in postmenopausal women treated with glucocorticoids. *J Clin Endocrinol Metab* 2014; **99**(11): 4231–4240. Doi: 10.1210/nc.2014-2177.
- [31] Chen YH, Peng SY, Cheng MT, Hsu YP, Huang ZX, Cheng WK, et al. Different susceptibilities of osteoclasts and osteoblasts to glucocorticoid-induced oxidative stress and mitochondrial alterations. *Chin J Physiol* 2019; **62**(2): 70. Doi: 10.4103/cjp.cjp_7_19.
- [32] Seibel MJ, Cooper MS, Zhou H. Glucocorticoid-induced osteoporosis: Mechanisms, management, and future perspectives. *Lancet Diabetes Endocrinol* 2013; **1**(1): 59–70. Doi: 10.1016/S2213-8587(13)70045-7.
- [33] Morimoto E, Li M, Khalid AB, Krum SA, Ching NO, Frenkel B. Glucocorticoids hijack Runx2 to stimulate Wif1 for suppression of osteoblast growth and differentiation. *J Cell Physiol* 2017; **232**(1): 145–153. Doi: 10.1002/jcp.25399.
- [34] Domazetovic V. Oxidative stress in bone remodeling: Role of antioxidants. *Clin Cases Miner Bone Metab* 2017; **14**(2): 209–216. Doi: 10.11138/cmbm/2017.14.1.209.
- [35] Al-Rahbi B, Zakaria R, Othman Z, Hassan A, Ahmad AH. Protective effects of Tualang Honey against oxidative stress and anxiety-like behaviour in stressed ovariectomized rats. *Int Sch Res Notices* 2014; **2014**: 521065. Doi: 10.1155/2014/521065.
- [36] Shafin N, Othman Z, Zakaria R, Nik Hussain NH. Tualang Honey supplementation reduces blood oxidative stress levels / activities in postmenopausal women. *ISRN Oxidative Med* 2014; **2014**: 364836. Doi: 10.1155/2014/364836.
- [37] Jung WW. Protective effect of apigenin against oxidative stress-induced damage in osteoblastic cells. *Int J Mol Med* 2014; **33**(5): 1327–1334. Doi: 10.3892/ijmm.2014.1666.
- [38] Undurti N. Catechins and osteoporosis. *Nutrition* 2013; **29**: 697–699. Doi: 10.1016/j.nut.2012.11.002.
- [39] Moon HJ, Ko WK, Han SW, Kim DS, Hwang YS, Park HK, et al. Antioxidants, like coenzyme Q10, selenite, and curcumin, inhibited osteoclast differentiation by suppressing reactive oxygen species generation. *Biochem Biophys Res Commun* 2012; **418**(2): 247–253. Doi: 10.1016/j.bbrc.2012.01.005.
- [40] Sheweita SA, Khoshhal KI, Baghdadi HH. Osteoporosis and oxidative stress - roles of antioxidants. In: Laher I (ed.) *Systems biology of free radicals and antioxidants*. Springer-Verlag Berlin Heidelberg; 2014, p. 2973–2995.
- [41] Guntur AR, Rosen CJ. The skeleton: A multi-functional complex organ. New insights into osteoblasts and their role in bone formation: The central role of PI3Kinase. *J Endocrinol* 2011; **211**(2): 123–130. Doi: 10.1530/JOE-11-0175.
- [42] Chen JR, Lazarenko OP, Wu X, Kang J, Blackburn ML, Shankar K, et al. Dietary-induced serum phenolic acids promote bone growth via p38 MAPK/β-catenin canonical Wnt signaling. *J Bone Miner Res* 2010; **25**(11): 2399–2411. Doi: 10.1002/jbmr.137.
- [43] Guo AJY, Choi RY, Cheung AWH, Chen VP, Xu SL, Dong TTX, et al. Baicalin, a flavone, induces the differentiation of cultured osteoblasts: An action via the Wnt/β-catenin signaling pathway. *J Biol Chem* 2011; **286**(32): 27882–27893. Doi: 10.1074/jbc.M111.236281.
- [44] Guo C, Yang RJ, Jang K, Zhou XL, Liu YZ. Protective effects of pretreatment with quercetin against lipopolysaccharide-induced apoptosis and the inhibition of osteoblast differentiation via the MAPK and Wnt/β-catenin pathways in MC3T3-E1 cells. *Cell Physiol Biochem* 2017; **43**(4): 1547–1561. Doi: 10.1159/000481978.
- [45] Kim CJ, Shin SH, Kim BJ, Kim CH, Kim JH, Kang HM, et al. The effects of kaempferol-inhibited autophagy on osteoclast formation. *Int J Mol Sci* 2018; **19**(1): 125. Doi: 10.3390/ijms19010125.