Heal Talk

Untying the Tongue Tie With Diode Laser: A Case Series

Dr. Monalisa Panda[1], Dr. Md. Jalaluddin[2]

PG Student[1], Professor[2], Department of Periodontics, Kalinga Institute of Dental Sciences, Bhubaneswar, Odisha

Abstract

Tongue tie or Ankyloglossia is a condition where the tongue is fused to the floor of the mouth. The lingual frenulum is short and thick, with slight impairment of tongue mobility. This is a developmental anomaly that affects oral hygiene maintenance, speech etc. Surgical intervention is a need here with care should be taken not to injure the salivary gland duct at the floor of the mouth and other vital structures. Hence, LASERs have been widely used in various soft tissue surgeries and have simplified such procedures with a better outcome. Our case series aims at the use of 810nm diode laser in management of ankyloglossia in five patients with optimum results.

Keywords: Ankyloglossia, lingual frenectomy, diode laser

How to cite this Article: Panda M, Jalaluddin M.Untying the Tongue Tie With Diode Laser: A Case Series.HTAJOCD.2019

Introduction

Ankyloglossia, is also known as tongue-tie, a congenital deformity of a short, thickened or abnormally tight lingual frenulum. It causes reduced tongue mobility, difficulty in swallowing, speech articulation problems, improper cleansing of the oral cavity, malocclusion, gingival recession and psychosocial stress.[1, 2] In 1960s, Wallace[3] termed ankyloglossia as a condition of a short frenulum linguae, in which the tip of the tongue cannot be extended beyond the lower incisor teeth or oral cavity. Approximately, 0.2% to 5% is the incidence rate of the tongue tie according to various studies. Males are more commonly affected than females. Though congenital, however the exact etiopathogenesis of tongue-tie is unknown. It may or may not be associated with various syndromes viz cleft lip and palate. Pronunciation of alphabets such as "s, z, t, d, l, j, zh, ch, th, dg," won't be accurate and difficulty to roll an "r".[2,4]

According to Kotlow,[5] ankyloglossia can be classified based on the length of the free tongue:

* Normal range of free tongue > 16mm
* Class I: mild ankyloglossia = 12-16mm
* Class II: moderate ankyloglossia = 8-11mm
* Class III: severe ankyloglossia = 3-7mm
* Class IV: complete ankyloglossia < 3mm

Surgical techniques for management of tongue tie can be frenectomy (complete excision of frenulum), frenotomy (simple cutting of frenulum), frenuloplasty (release the tongue tie and correct its anatomic position).[2] Frenectomy is a safe, effective, and practical approach for tongue tie treatment.[6] Frenectomy with diode laser technique has benefits of reduced bleeding during surgery with consequent reduced operating time, less pain, and rapid postoperative hemostasis, thus eliminating the need for sutures. Least requirement of anesthetics and sutures, with well improved postoperative comfort and healing, make this technique very patient friendly especially for young patients.[2,4,7,8] The aim and objective of the case series is to evaluate the post operative tongue elevation and mobility after the management of tongue tie.

Methodology

Five adult patients of 20-25 years age reported to the Department of Periodontics and Oral Implantology, Kalinga Institute of Dental Sciences with the chief complaint of difficulty in elocution, tongue movement and maintaining oral hygiene. Out of five, three were male and two were female. No relevant medical and family history of any patients. However, on intraoral examination, we noticed restricted tongue movement due to the presence of fused lingual frenum in all cases. That apart, the patients were unable to brush properly on the lingual aspect of the mandibular anterior teeth due to the unusual position of the frenum. To evaluate the oral hygiene of the patient, Oral Hygiene Index Simplified was taken before phase I therapy, after 1month of phase I therapy and post frenectomy. According to Kotlow's classification, three out of five patients were Class II moderate type of ankyloglossia (Figure 1) and the other two patients had Class III severe type of ankyloglossia (Figure 1.1). Tongue mobility was examined by using Hazelbaker Assessment Tool for Lingual Frenulum Function (HATLFF).[9] Only three functions i.e. lateralization, lift of tongue, extension of tongue were examined before and post 1month of frenectomy.

After initial phase I periodontal therapy, the management of tongue tie was planned by lingual frenectomy by 810nm diode laser in all such individuals as the patients were apprehensive for the conventional lingual frenectomy procedure where surgical intervention is done using scalpel. Moreover the floor of the mouth is highly vascular area. Hence to manage the bleeding and release patient's stress diode laser was selected as the mode of the treatment to achieve better haemostatis and also to make the procedure more comfortable for the patients.

Operative Technique

Informed consent was obtained for the procedure from all patients in the language best known to them. Local anesthesia with adrenaline was administered at the frenum region. After achieveing adequate anesthesia in the area, the frenum was engaged with haemostat as close to the base as possible (Figure 2) or tension was applied on the frenum with the help of sutures. The diode laser (Figure 3) which was activated as 2W in continuous mode was applied using initiated tip of 300µm in contact mode in a brushing stroke to incise the tissue on the upper surface extending beyond the tip of the haemostat. Similar incisions were made along the under surface of haemostat to remove the triangular resected portion of the frenum along with the haemostat. The underlying brush like fibrous attachment was excised by giving horizontal strokes separating the fibers (Figure 4). No bleeding was observed throughout the procedure and it went uneventful. The ablated tissue was mopped continuously with the help of wet gauze piece to prevent excessive thermal damage to the tissues. No sutures were placed. They were reviewed after 7days (Figure 5), 15 days (Figure 6), 3 months (Figure 7). All the patients were advised for speech therapy.

Results

Wound healing was satisfactory without any complication. After 3 months evaluation following surgery, all patients had adequate upward (Figure 7), forward (Figure 8) and lateral tongue extensions (Figure 9) (Table 1) and were able to maintain oral hygiene on lingual area efficiently (Table 2).

	Pre op	Post op (after 3 months)
Lateralization		
1	1	2
2	0	2
3	1	2
4	0	2
5	2	2
Lift of tongue		
1	1	2
2	0	2
3	1	2
4	0	2
5	2	2
Extension of tongue		
1	1	2
2	0	2
3	1	2
4	0	2
5	2	2

Table 1: Tongue mobility assessment by Hazelbaker Assessment Tool for Lingual Frenulum Function (HATLFF) pre-operatively and 3 months post-operatively

	Before phase I therapy	After 4 weeks of phase I therapy	After 12 weeks of frenectomy
1	2.1	1.5	1.0
2	2.8	1.3	1.2
3	1.7	1.2	0.5
4	2.6	1.4	0.7
5	1.9	1.3	0.4

Table 2: OHI-S Score before and after phase I therapy and 12 weeks after frenectomy

Fig 1: Class II Moderate Type of Ankyloglossia

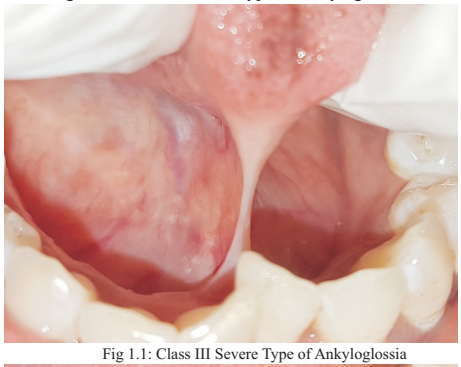

Fig 1.1: Class III Severe Type of Ankyloglossia

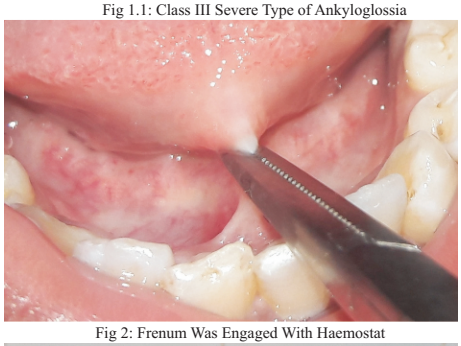

Fig 2: Frenum Was Engaged With Haemostat

Fig 3: Diode Laser with 300µm of Tip

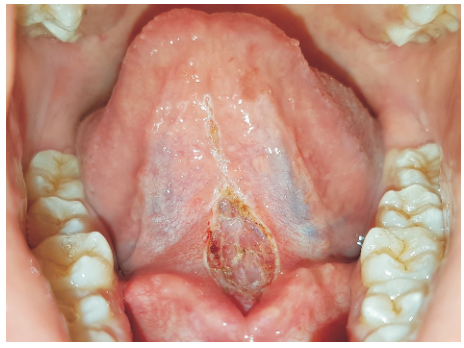

Fig 4: Frenum Resected & Underlying Brush Like Fibrous Attachment Was Excised

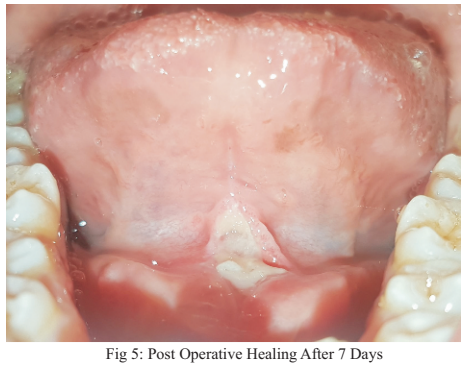

Fig 5: Post Operative Healing After 7 Days

Fig 6: Post Operative Healing After 15 Days

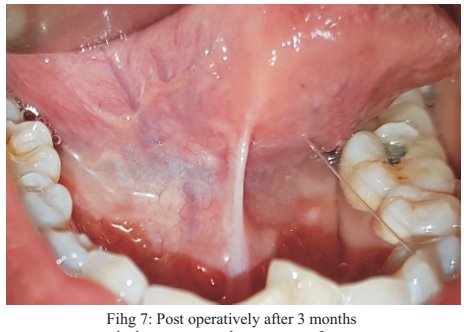

Fihg 7: Post operatively after 3 months and adequate upward movement of tongue

Fig 8: Improved Forward Tongue Movements After 3 Months

Fig 9: Improved Lateral Tongue Movements After 3 Months

Discussion

In severe/complete ankyloglossia of a child or an adult, there is usually an obvious limitation of the tongue protrusion and elevation. The associated discomfort and restrictions are primarily subjective in nature[2]. Optimal management of tongue tie including timely and appropriate surgical intervention followed by speech therapy, post operative exercises to improve muscle movements, cleaning of oral cavity when indicated, delivers pleasing results, often in a shorter time than expected[4]. Various surgical techniques has been employed i.e. frenectomy, frenotomy, frenulotomy for the treatment of ankyloglossia, which can be achieved by scalpel, electrocautery or lasers [4, 6]. An In-vitro study conducted by Gokharkey etal on 'Effects on Oral Soft Tissue Produced by a Diode Laser' concluded that the use of diode laser enhances thermocoagulation to achieve hemostasis and provides a bloodless surgical field and the desired results can be achieved with least risk of unwanted thermal damage with short pulses at the highest power density for the shortest time possible. Even CO_2 lasers cause no greater damage to lateral tissues with the constant wave mode at higher power levels also, no charring of bone underlying 0.8-mm-thick soft tissue. They had also observed that in comparison to Nd:YAG, diode laser had greater absorption and a smaller penetration depth especially in blood-rich tissue. This causes not only a better incision performance but also an excellent coagulation of tissue. It's simple use also allows very good modeling of the gingiva.[13] In our study, laser application has proved to be advantageous as it is relatively bloodless, has the ability to coagulate, vaporize, or cut tissues, sterilization of wound tissue, minimal swelling and scarring, no requirement of sutures little mechanical trauma, reduced surgical time, decreased post-surgical pain and high patient acceptance. We have used the 810 nm wavelength diode laser that transverses the epithelium and penetrates 2- 6 mm into the tissue. When comparing other soft tissue lasers, the Nd:YAG (1064 nm) and diode lasers (805 nm, 810 nm), the mentioned wavelengths have a similarly high absorption in soft tissue which translates into excellent incision performance and coagulation of tissue.[11]

When laser cutting is in progress, small blood and lymphatic vessels are sealed due to the generated heat, thereby reducing or eliminating bleeding and edema. The fiber is then used in light contact, sweeping mode to

cover the entire soft tissue lining. Damage to vital anatomical sites can also be avoided. The heat buildup also allows for the sealing of small lymphatic vessels which results in a reduced postoperative edema. Suturing is usually not necessary also due to the surface coagulum.[10,11]

Conclusion

With the use of diode laser, treatment of tongue tie can be very safe, effective, atraumatic with better patient compliance. 810nm diode lasers can be used extensively in various periodontal soft tissue surgeries as well considering the operating mode and power output to achieve minimum thermal damage. With our study we infer that Lasers have been proven to be a new advanced treatment modality in management of tongue tie and may be used more frequently by all periodontists in near future.

References

1. R. Crippa , M. Paglia, F. Ferrante, A. Ottonello, F. Angiero. Tongue-tie assessment: clinical aspects and a new diode laser technique for its management. European Journal of Paediatric Dentistry vol. 17/3-2016.
2. Vale´rie G.A. Suter and Michael M. Bornstein. Ankyloglossia: Facts and Myths in Diagnosis and Treatment. J Periodontol 2009; 80:1204-1219.
3. Wallace AF. Tongue tie. Lancet 1963;2:377-378.
4. H.E. Darshan, P.M. Pavithra. Tongue Tie: From Confusion to Clarity-A Review. International journal of dental clinics 2011:3(1): 48-51
5. Kotlow LA. Ankyloglossia (tongue-tie): A diagnostic and treatment quandary. Quintessence Int 1999;30:259-62.
6. Lauren M. Segal, Randolph Stephenson, Martin Dawes, Perle Feldman. Prevalence, diagnosis, and treatment of ankyloglossia. Vol 53: June 2007 Canadian Family Physician Le Médecin de famille canadien.
7. Mohammad Arif Khan, Mohd. Kamran Farooqui, Charanjeet Singh Saimbi, Sunil Kumar Yadav, Anurag Saxena. Untangle the lingual aberrant frenum by diode laser: A case report with review of literature. Journal of Dental Lasers, July - December 2016,Issue 2, Vol 10.
8. Vijayendra Kumar Jain, Gagan R. Jaiswal. Diode laser: An alternative treatment modality for ankyloglossia. Journal of Dental Lasers,July - December 2015,Issue 2,Vol 9.
9. Hazelbaker AK: The assessment tool for lingual frenulum function (ATLFF): Us in a lactation consultant private practice. Pasadena, California, Pacific Oaks College; 1993.
10. Sugumari Elavarasu, Devisree Naveen, and Arthiie Thangavelu. Lasers in periodontics. J Pharm Bioallied Sci. 2012 Aug; 4(Suppl 2): S260–S263.
11. Mahitab M. Soliman, Youssef Al Thomali, Ammar Al Shammrani, Hanaa El Gazaerly. The Use of Soft Tissue Diode Laser in the Treatment of Oral Hyper Pigmentation. International Journal of Health Sciences, Qassim University, Vol. 8, No. 2 (April 2014)
12. Andrey V. Belikov Alexei V. Skrypnik Ksenia V. Shatilova. Comparison of diode laser in soft tissue surgery using continuous wave and pulsed modes in vitro. J frontiers of optoelectrics June 2015, Volume 8, Issue 2, pp 212–219
13. K. Goharkhay, A. Moritz, P. Wilder-Smith, U. Schoop, W. Kluger, MD, S. Jakolitsch, and W. Sperr. Effects on Oral Soft Tissue Produced by a Diode Laser In Vitro. Lasers in Surgery and Medicine 25:401–406 (1999)