

# Treatment of Unstable Trochanteric / Subtrochanteric Fractures with PFN, First Cases at University Hospital of Trauma & American Hospital. Results and Complications.

Ledian Fezollari<sup>1</sup>, Gjergj Caushi<sup>1</sup>, Vilson Ruci<sup>1</sup>, Artid Duni<sup>1</sup>, Agron Dogjani<sup>2</sup>, Edvin Selmani<sup>1</sup>, Zamir Demiraj<sup>1</sup>, Guido Bassi<sup>3</sup>

<https://doi.org/10.32391/ajtes.v4i1.86>

## Abstract

**Aims and objectives:** This study was done to evaluate the functional and radiographic outcome of PFN in treatment of proximal femoral fracture and more common technical, mechanical complications and intraoperative difficulties during the implant implementation.

**Materials & Methods:** We conducted a retrospective study with ten cases of proximal femoral fractures treated between September 2017 and September 2018, which were accepted at the Department of Orthopedics, the University Hospital of Trauma and the American Hospital in Tirana. Fractures are classified according to classification AO and Boyd-Griffin. The age range of patients taking the study was 20-90 years. Ten cases were followed at regular intervals and the final assessment was made at the end of the 6 month period. In the result, functional clinical assessment according to Harris hip score was done .

**Results:** In our study, mean age was 66 y.o, 7 male and 3 females. Mean of hospitalization time 6 days, mean operation time 120 min. In our study at 6 months follow up, union was achieved in 9 cases, open reduction was performed in 3 cases (10 cases). Technical and mechanical complications were noted in one case. Reoperation rate was 10 % (one case). According Harris hip scoring system excellent results were seen 40 % of cases (4 cases), good results in 50 % cases (5 cases), and poor results in 10% cases (1 case).

**Conclusions:** In our study, in spite of low experience in proximal femoral nailing in cases with unstable trochanteric / subtrochanteric fractures, it was found that PFN is an attractive implant and suitable for proximal femoral fractures and its use in unstable trochanteric / subtrochanteric fractures is very encouraging. This study has also shown that this device can safely be used by an average surgeon to handle common but sometimes tough fractures. Operation is technically not difficult, but gradual learning and great patience is needed to make this method really minimal invasive.

**\*Corresponding Author:** Ledian Fezollari

✉ E-mail: [ledifezollari@gmail.com](mailto:ledifezollari@gmail.com)

<sup>1</sup>Department of Orthopedics, University Hospital of Trauma, Tirana, Albania

<sup>2</sup>General Surgery Department, University Hospital of Trauma, Tirana, Albania

<sup>3</sup>Department of Orthopedics, American Hospital, Tirana, Albania

## Full text

### Introduction

Extracapsular fractures (intertrochanteric and subtrochanteric fractures) mainly involve cortical and compact bone.<sup>1</sup> For the treatment of unstable proximal femoral fractures with lack of medial support and intertrochanteric fractures, there are three main options. Cephalomedular nail, PFLCP plate or DHS plate.<sup>1</sup> From the biomechanical point of view of using an intramedullary PFN type plaque seems to be the most appropriate technique.<sup>2</sup> This study was undertaken to evaluate the functional and radiological outcome of the PFN system in the treatment of proximal femoral fractures and the most common technical, mechanical complications, and ally the Harris hip score was used in functional clinical assessment.

Patients were placed in supine position on the fracture table under spinal or general anesthesia according to the patient's condition. The fracture was reduced by longitudinal traction and the inferior extremity was placed in light adduction to facilitate insertion of the nail through the major trochanter. Longitudinal incision 5 cm up to the trochanter major was performed. A 2.8 mm threaded K-W guide was inserted the apex of trochanter major under the control of the C-arm. Where standard

intraoperative difficulties during the implementation of this implant. A comprehensive review of the literature on the use of the PFN system is also presented.

### Methods

We conducted a retrospective study on cases of proximal femoral fractures treated between September 2017 to September 2018, who were admitted to the Department of Orthopedics, University Hospital of Trauma, and American Hospital, Tirana. Fractures were classified according to AO and Boyd-Griffin classification. The age range of patients in the study 20-90 years. The most common cause of injury was home trauma with minimal trauma. Ten cases were followed at regular intervals and a final evaluation was performed at the end of 6 months.

PFN was used, the proximal part of the femur was reamerated with a 14 mm reamer for a distance of approximately 7 cm; whereas while using the long PFN, it was started with increasing diameters of flexible reamer up to 11 mm.

After putting the size-appropriate PFN insertion system on the insertion device, the nail was manually inserted into the femoral shaft. The hip pin is inserted first, and then the main neck screws of the correct size are

## **Surgical technique**

### **Patient position**

The patient is positioned on the supine position on the operating table. The foot is placed in the traction in such a way that it will allow good radiological evaluation and better manipulation of the foot with the application of the traction. The body is positioned at an angle of 15 degrees to the normal side. The normal limb is placed in a gynecological-flexion position, external rotation, and abduction to provide sufficient space, helping to position the C-arm. <sup>6</sup> The affected extremity is held in traction via the foot.

Reduction is achieved by traction and internal rotation while maintaining traction and confirmed with C-arm. If the deposition cannot be achieved by closed methods the fracture site should be opened using a lateral approach, open anatomic reduction is performed using bone clamp, K-W, forceps, etc.

### **Approach**

A 3-5 cm incision made from the tip of the trochanter major in light flexion dorsally. Subcutaneous tissue and fascia along the incision line cutis is incised. Gluteus maximus is dissected. <sup>6</sup> Palpate the trochanter major to determine the entry point. This is accomplished in the event of a closed reduction. In cases of open reduction, especially in subtrochanteric fractures, lateral

visualization is used to perform open reduction.

### **Entry point**

Fracture reduction is an essential prerequisite for determining the entry point. Once bone fracture reduced with the help of the C-arm, the entry point is determined.<sup>7</sup> The entry point is at the tip of the trochanter major or easily medially of the trochanteric tip, if the reduction is not accomplished via traction and internal rotation then use K-W and Steinman pin. Confirming the AP entry point and lateral view, the AWL is pushed to the level of trochanter minor.

### **Guide wire insertion and reaming**

A 3.2mm guide wire is inserted through the access point and pushed distally. Proximal reaming is done with the aid of a 15mm cannulated awl passing along the guide wire to accommodate the proximal part which is wider when compared to its distal portion. Reaming is done consistently 1mm longer than the desired diameter of the couple. Protecting sleeves can be used during reaming to prevent soft tissue injury. After crossing the guide wire, check the position of the guide wire underneath c-arm fluoroscopic guidance in order to ensure that the position of the guide wire is central, this will avoid unnecessary reaming. The guide wire is inserted up to 5mm subcondral to the femoral head.

**Insertion of the proximal femoral nail**

PFN mounted to the insert assembly. Advances manually with rotations during insertion. It can be easily hit with a hammer. Check with the C-arm that the position of the neck screws corresponds to the central part of the femoral neck

**Proximal targeting**

Before insertion the PFN, it has to be checked at the insertion assembly, proximal and distal targeting.

Through a mini-incision on the lateral side of the femur, the drill sleeve is then inserted into the lateral cortex of the femur using the proximal targeting guide.

Guide wires are inserted for the central neck screw and the anti-rotation screw in the drill sleeve and advanced up to 5 mm subcondral to femoral head, controlling it with the c-arm.

The position of the guide wire is controlled under the fluoroscopic guidance, the guide wire should be inferior to the femoral neck in AP view and central position in lateral view.

Drill and measure proximal femoral neck screws. The length of the derotation screw should be 10 to 15 mm shorter than the center screw (lag) to avoid the 'Z' effect.

**Distal targeting**

Distal targeting is accomplished through the distal guidance system, advanced by

drill sleeve placement using 4 mm drill bits. Screw length is checked with c-arm

**Post-op management**

Postoperative patients were managed with first-generation Cephalosporin, Cefazolin 1 g 4x1. Oral antibiotics were started from the first day to 7-th postop. The analgesics were given for the first 2 days thereafter depending on the patient's level of pain tolerance. The drain was removed on the second day. Exercises and physiotherapy to strengthen quadriceps muscle began on day 2. The weightless walk began on the third day with walkers or crutches. The sutures were removed on the 12th postoperative day. Radiological evaluation is done at week 8 and then every month until fracture consolidation. Rehabilitation, total weight bearing of patients was decided based on radiological evidence of callus formation and consolidation. Patients were assessed with a Harris Hip score at the end of 6 months.

**Discharge**

Patients were discharged from the hospital with good general condition, problem-free wounds, walking independently of crutches or walkers.

**Results**

*Age*

The patients in our study were mostly over 60 years old. With an average age of 66 years.

Age (years)	Nr of patients	%
20-40	1 (10 %)	10 %
41-50	1 (10 %)	10 %
51-60	2 (20 %)	20 %
61-90	6 (60 %)	60 %

*Table 1: Age*

### Sex

Due to the small number of cases in the study, unlike the literature data, we had male predominance. 7 male and 3 female cases.

Sex	Nr of patient	%
Male	7	70
Female	3	30

*Table 2: Sex*

### Mechanism of injury

Domestic falldown dominated, height falling and a car accident.

Mechanism of injury	Nr of patients	%
Domestic falldown	8	80
Car accident	1	10
Fall from height	1	10

*Table 3: Mechanism of injury*

### Side of injury

Left side predominates

Side of injury	Nr of patients	%
Dexter	3	30

Sinister	7	70
----------	---	----

*Table 4: Side of injury*

### Length of hospital stay

The average hospital stay was 6 days. Patients have been rehabilitated for the second day postop. One patient stayed 18 days due to concomitant injuries (thoracic trauma). Full weighting was started from week 6.

Hospitalization time	Nr of patients	%
<10 days	8	80
11-15 days	1	10
> 15 days	1	10

*Table 5: Length of hospital stay*

### Complications of osteosynthesis

In 10 cases in our study, one nonunion patient complained of implant failure, leg shortening, hip varus deformity. Case managed with revision intervention, removal of material plus PFLCP plate synthesis with iliac graft.

Osteosynthesis complications	Nr of Patients
Implant failure/plate breakage	1
Breakge of screw	1
Leg shortening	1
Varus deformity	1
'Z' effect	0
Reverse 'Z' effect	0
Hip motions rigidity	0

*Table 6: Osteosynthesis complications*

Intraoperative details	Nr. of patients (10)
Duration of surgery	120 min
Open Reduction	3
Closed Reduction	7
Intra-op hemorrhage	135 ml

*Table 7: Intraoperative variables*

#### *Functional result by harris hip score*

Points	ROM	Nr of patients
90-100	Excellent	4 (40 %)
80-89	Good	5 (50 %)
70-79	Fair	0
<70	Poor	1 (10 %)

*Table 8: Harris Hip Score*

#### *Consolidation rate*

In 10 cases, 9 cases were consolidated within 16 weeks. One case was not consolidated, complicated by implant insufficiency, which was resolved with revision intervention

#### **Discussion**

Unstable fractures of the proximal femur present a significant challenge for the orthopedic surgeon. Surgical fixation is often technically difficult and classical surgical techniques can lead to primary synthesis failure.<sup>8,9</sup> The best treatment for these fractures remains controversial. DHS fixation is widely preferred, but fixation / synthesis failure accounts for up to 20% of cases.<sup>1</sup> Common causes of fixation failure include fracture

instability, osteoporosis, lack of anatomical reduction, implant failure, and incorrect screw placement in the femoral head (leading to 'cut-out' of the screw).<sup>10</sup>

In unstable trochanteric fractures, axial telescope control and rotational stability are essential. Intramedullary implants inserted in a less invasive manner are better tolerated by the elderly.<sup>12</sup> A new device was developed by AO / ASIF: (PFN), with an additional antirotation pin for preventing rotation and collapse of the head-neck fragment and a special upper together with a smaller distal end diameter resulting in less stress concentration at tip<sup>13</sup>. Velasco and Comfort found that 63% of subtrochanteric fractures occurred in patients from 51 and over 70 years of age and 24% of patients 17 to 50 years old.<sup>14</sup> In a study by Babst et al in 1998 on intertrochanteric fractures, the median age was 79.7 years (range 39-98 years).<sup>15</sup> According to Klinger et al in 2005, the median age was 74 years, ranging from (27 to 98 years) in patients who were treated with either DHS or proximal femoral shaft.<sup>16</sup> Alyassari et al studied seventy patients and the mean age was 84 years trokanterike shows that fractures are more common in the age group avancuar.<sup>17</sup> In our study 6 patients (60%) were over 60 years old. The median age of unstable intertrochanteric fractures was 66 years

with a range of 20 years to 90 years, which is slightly toward the older age group, mainly due to osteoporosis.

Simmermacher in their study median duration of surgery was 68.7 min (range 25–240 min) .1 Pajarinan et al in their comparative study of DHS and PFN in proximal femoral fractures, median time of surgery in DHS was 45 min (rate 20–105 min) and in PFN was 55 min (35–200 min).<sup>18</sup> Wang in their study, mean operation time was 90 min (range 60–155 min).<sup>19</sup> The duration of surgery in our study was longer during the mid 120 min

(100-180 min rate), this is due to the lack of experience in the technique as both clinics studied orthopedic surgeons are more familiar with the DHS plate and PFLCP plate technique. With the more frequent use of proximal femoral augmentation surgery, in recent cases the operative time has been shorter. Fogagnolo et al reported 46 patients with an average rate of technical or mechanical intra-operative complications of 23.4%, mainly problems with distal suture screw targeting and major trochanter lateral wall fracture.<sup>20</sup>

Variables	Ekstrom et al <sup>24</sup>	Boldin et al <sup>23</sup>	Lei-Shang et al <sup>26</sup>	Menzes et al <sup>25</sup>	Chopra et al <sup>27</sup>	Our study
Nr of Patients	105	55	99	155	125	10
Surgery duration	105	68	46	76	88	120
Consolidation %	100	100	98	99	98.4	90
Synthesis failure	11	0	0	2	2	1
Open reduction	-	10	34	1.3	11	3
Repaeted surgery	9	10	0	12	4	1

**Table 8:** Comparison of Variables

Kamboj et al studied 30 cases, in one case with a trochanteric fracture extending to the femoral diaphysis, which was managed with the placement of the sarcolemma. One patient had fractured intra-operative femoral diaphysis of the femur, three patients had poor screw placement. Closed repositioning was tried in all cases and was achieved in 17 patients, in the remaining 13 cases open repositioning was performed. In their study, due to the smaller diameter of the femoral neck, they were not able to cross the coxofemoral anti-rotating pin in four patients.<sup>21</sup> Alyassari et al in their study, two cases required open repo, targeting and distal screw placement was difficult in three cases, insertion of the suture was difficult in one patient.<sup>17</sup> In our study, there was one case that we had to place a suture over the femoral suture. In three patients, it was not possible to obtain a closed repository, so an open repository was performed. In two patients, there was a fracture of the guide wire, reaming over the guide wire in the femoral neck. Pajarinan et al in their study of 83 patients, there was a case of heterotopic ossification corresponding to grade 4 according to Brooker, where PFN was used.<sup>118</sup> Werner et al were the first to introduce the term Z-effect, detected in five patients (7.1 % of 70 cases). The incidence of 'cut-out' of the neck screws in this study was 8.6%. The Z-effect phenomenon is referred to as a characteristic sliding of the proximal

screw in opposite directions during the postoperative period of weighing.<sup>22</sup> The adverse Z effect described by Boldin et al occurred with the lateral antirrotation screw (hip pin), which required removal its early. In their prospective study of 55 patients with unstable intertrochanteric or subtrochanteric fractures, they had three cases with Z-effect and two with opposite effect Z.<sup>23</sup>

Fogagnolo et al, who reported 46 patients with an average intraoperative mechanical or mechanical complication rate of 23.4%. They also reported two implant failures and a fracture below the tip of the suture. They also reported heterotopic ossification in two patients assigned to PFN.<sup>20</sup> Simmermacher et al in a multicenter clinical trial, reported PFN technical failures after poor repo, misuse, or incorrect screw selection in 5% of cases. Central neck screw cut-out occurred at 0.6% .<sup>1</sup> In our study we had a shortening of the bias in one patient. There were cases of implant failure, with fractures at the junction level with central screws and distal screw fractures, no cases with 'Z Effect' and 'Z reverse effect'. In this case revision surgery, implant resection and PFLCP plaque synthesis and iliac graft were performed with implant insufficiency. In two patients, coxofemoral articulation stiffening was present.

According to the Harris hip score score system in our study, excellent results were seen in 4 cases, good in 5 straight



cases in 16 cases, and poor results in one case treated with proximal femoral nail (PFN)

## Conclusion

In our study, despite the limited experience in proximal femoral articulation in cases of unstable trochanteric / subtrochanteric fractures, it was found that PFN is an attractive and suitable implant for proximal femoral fractures and its use in unstable trochanteric / subtrochanteric fractures very encouraging. This study has also shown that this device can be safely used by the average/young surgeon to treat common but sometimes difficult fractures. The operation is technically not difficult, but gradual learning and great patience are needed to make this method truly minimally invasive. Most of the complications of PFN are surgical and instrument-related, which can be reduced by proper patient selection and good planning before surgery.

## References

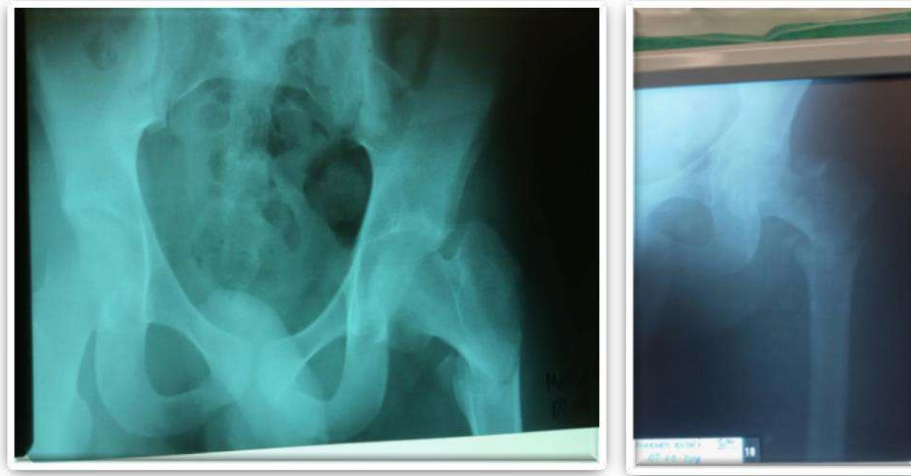1. Simmermacher RK, Bosch AM, Van der Werken C. The AO/ASIF-proximal femoral nail (PFN): A new device for the treatment of unstable proximal femoral fractures. *Injury*. 1999;30:327-32.
2. Rins S, etsch R, Bu scher D. ammanagel und Classic-nagel intramedulla re Stabilisierung versus DHS (extramedulla re Stabilisierung bei proximalen Femurfracturen. *Hefte Unfallchir*. 1996;262:14.
3. Simmermacher RK, Bosch AM, Van der Werken C. The AO/ASIF-proximal femoral nail (PFN): a new device for the treatment of unstable proximal femoral fractures. *Injury* [Internet]. 1999 Jun [cited 2017 Oct 13];30(5):327-32
4. Ynthes. PFN - Proximal Femoral Nail. Image (Rochester, NY). 2006;
5. Banan H, Al-Sabti A, Jimulia T, Hart AJ. The treatment of unstable, extracapsular hip fractures with the AO/ASIF proximal femoral nail (PFN)--our first 60 cases. *Injury* [Internet]. 2002 Jun [cited 2017 Oct 13];33(5):401-5
6. Of AS, Of M, Fracture S, By F, Nailing P, To DS. a Study of Management of Subtrochanteric Fracture Femur by Proximalfemoral Nailing Dissertation Submitted To. 2011;(December):1-85.
7. Bridle SH, Patel AD, Bircher M, Calvert PT. Fixation of intertrochanteric fractures of the femur. *J Bone Joint Surg*. 1991;73:330-4.
8. Baumgaertner MR, Curtin SL, Lindskog DM, Keggi JM. The value of the tip-apex distance in

- predicting failure of fixation of peritrochanteric fractures of the hip. *J Bone Joint Surg* 1995;77:1058-64.
9. Sierra RJ, Cabanela ME. Conversion of failed hip hemiarthroplasties after femoral neck fractures. *Clin Orthop Relat Res*. 2002;399:129-39.
  10. Simpson AH, Varty K, Dodd CA. Sliding hip screws: modes of failure. *Injury*. 1989;20:227-31.
  11. Moein CM, Verhofstad MH, Bley RL, van der Werken C. Soft tissue injury related to choice of entry point in antegrade femoral nailing: piriform fossa or greater trochanter tip. *Injury*. 2005;36:1337-4.
  12. Baumgaertner MR, Curtin SL, Lindskog DM. Intramedullary versus extramedullary fixation for the treatment of intertrochanteric hip fractures. *Clin Orthop Relat Res*. 1998;348:87-94.
  13. Euler E, Huber St, Heining S, Schweiberer L. Spannungsoptische Untersuchung unterschiedlicher Stabilisierungsverfahren bei pertrochantaren Femurfracturen. *Hefte Unfallchir*. 1996;262:2.
  14. Velasco RU, Comfort TH. Analysis of treatment problems in subtrochanteric fractures of the femur. *J Trauma*. 1978;18(7):513-23.
  15. Babst R, Renner N, Bieder MM, Rosso R, Heberer M, Harder F, Regazzoni P. Clinical results using the trochanteric stabilizing plate: the modular extension of the dynamic hip screw for internal fixation of intertrochanteric fractures. *J Orthop Trauma*. 1998;12(6):392-99.
  16. Klinger HM, Baums HM, Eckert M, Neugebauer R. A comparative study of unstable per and intertrochanteric femoral fractures with DHS and PFN and TSP. *Zentralbl Chir*. 2005;130(4):301-6.
  17. Al-yassari G, Langstaff RJ, Jones JW, Al-Lami M. The AO/ASIF proximal femoral nail (PFN) for the treatment of unstable trochanteric femoral fracture. *Injury*. 2002;33(5):395-9.
  18. Pajarinen J, Lindahl J, Michelsson O, Savolainen V, Hirvensalo E. Peritrochanteric femoral fractures treated with a dynamic hip screw or a proximal femoral nail. A randomised study comparing post-operative rehabilitation. *J Bone Joint Surg Br*. 2005;87(1):76-81.
  19. Wang WY, Yang TF, Fang Y, Lei MM, Wang GL, Liu L. Treatment of subtrochanteric femoral fracture with long proximal femoral nail antirotation. *Chin J Traumatol*. 2010;13(1):37-41.

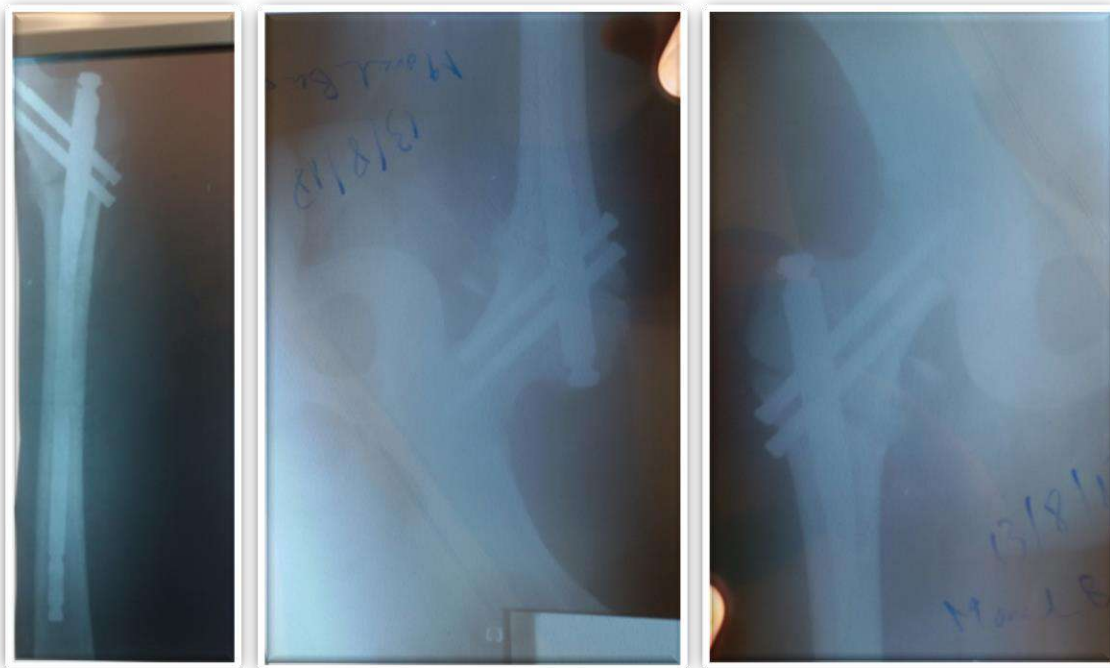20. Fogagnolo F, Kfuri M Jr, Paccola CA. Intramedullary fixation of pertrochanteric hip fractures with the short AO-ASIF proximal femoral nail. *Arch Orthop Trauma Surg.* 2004;124(1):31-7.
21. Kamboj P, Siwach RC, Kundu ZS, Sangwan S, Walecha P, Singh R. Results of modified proximal femoral nail in peritrochanteric fractures in adults. *Internet J Orthop Surg.* 2007;6:2.
22. Werner-Tutschku W, Lajtai G, Schmiedhuber G, Lang T, Pirkl C, Orthner E. Intra- and perioperative complications in the stabilization of per- and subtrochanteric femoral fractures by means of PFN. *Unfallchirurg.* 2002;105:881-5.
23. Boldin C, Seibert FJ, Fankhauser F, Peicha G, Grechenig W, Szyszkowitz R. The proximal femoral nail (PFN)--a minimal invasive treatment of unstable proximal femoral fractures: a prospective study of 55 patients with a follow-up of 15 months. *Acta Orthop Scand.* 2003;74(1):53-8.
24. Ekström W, Karlsson-Thur C, Larsson S, Ragnarsson B, Alberts KA. Functional outcome in treatment of unstable trochanteric and subtrochanteric fractures with the proximal femoral nail and the Medoff sliding plate. *J Orthop Trauma.* 2007;21(1):18-25.
25. Menezes DF, Gamulin A, Noesberger B. Is the proximal femoral nail a suitable implant for treatment of all trochanteric fractures? *Clin Orthop Relat Res.* 2005;439:221-7.
26. Jiang LS, Shen L, Dai LY. Intra medullary Fixation of subtrochanteric fractures with Long proximal femoral nail or Long Gamma Nail; Technical Notes and Preliminary Results. *Ann Acad Med Singapore.* 2007;36(10):821-6.
27. Chopra BL, Kumar K, Khajotia BL, Bhambu R, Bhatiwala S, Shekhawat V. Proximal femoral nail- outcome and complications: a prospective study of 125 cases of proximal femoral fractures. *Int J Res Orthop* 2017;3:973-8.
28. Chakraborty M, Thapa P. Fixation of subtrochanteric fracture of the femur: Our experience. *J Clin Diagnostic Res.* 2012;6(1):76-80.
29. Hak DJ, Wu H, Dou C, Mauffrey C, Stahel PF. Challenges in Subtrochanteric Femur Fracture Management. Vol. 38, *Orthopedics.* 2015. p. 498-502.

## Case series

### Case 1

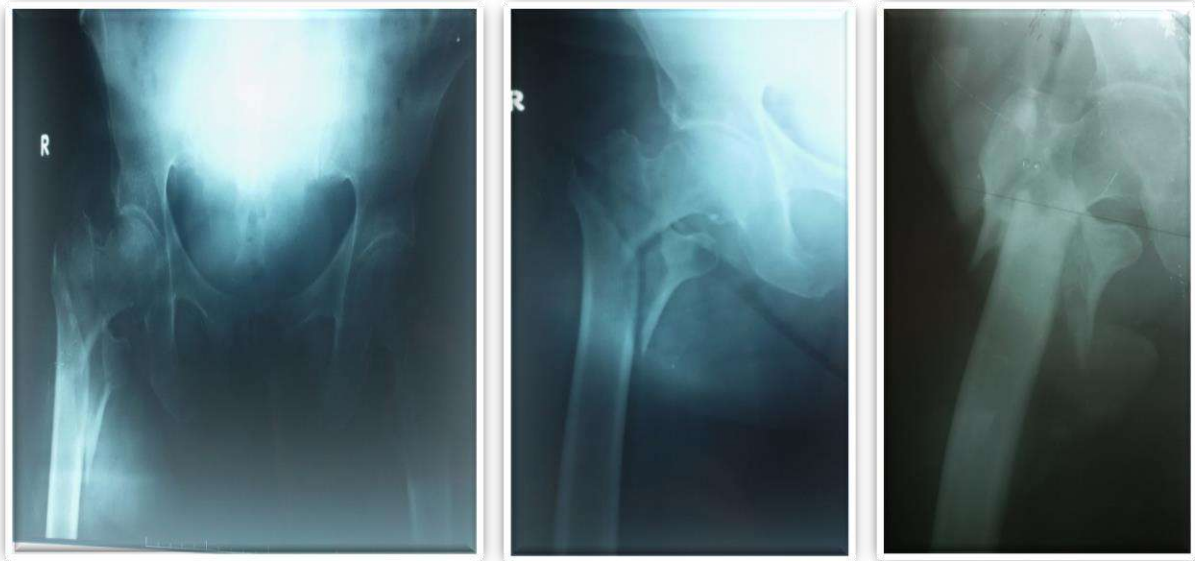

Pre-Op.

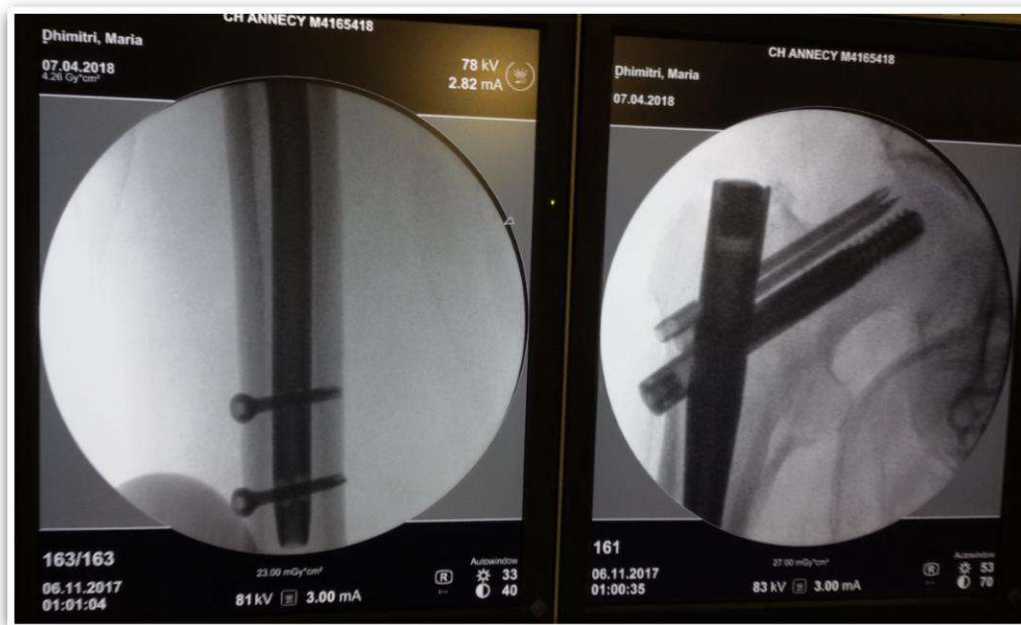

Post-Op.

## Case 2

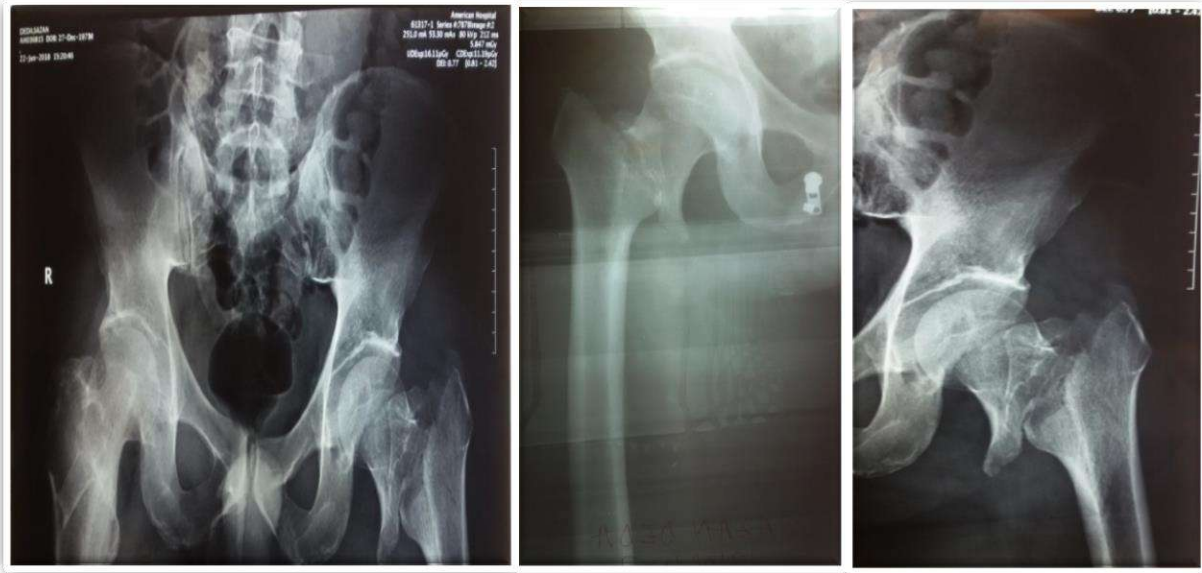

### Pre-Op.

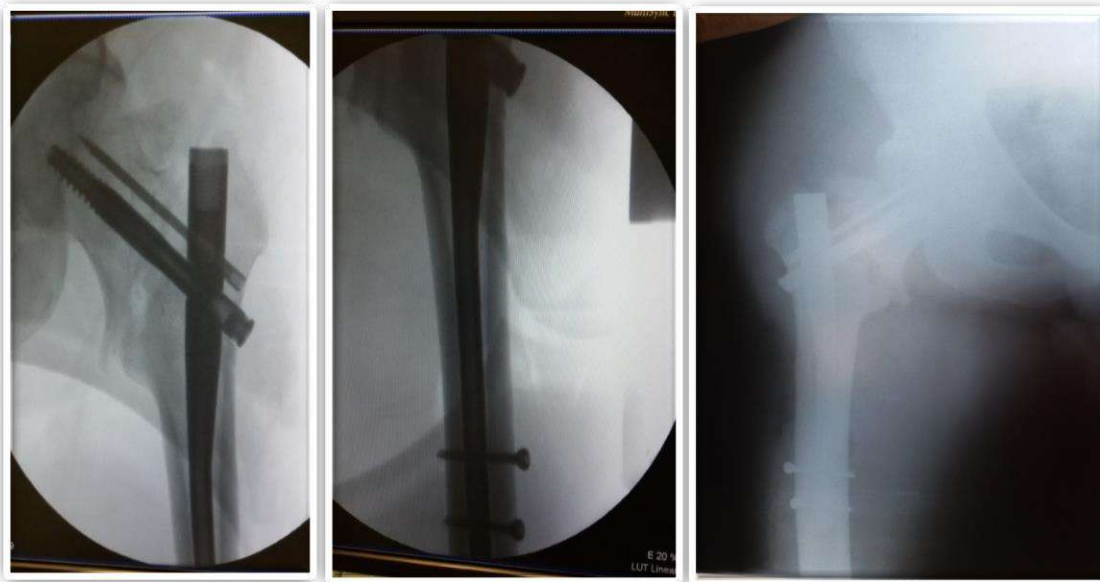

### Post-Op.

### Case 3



Pre-Op.

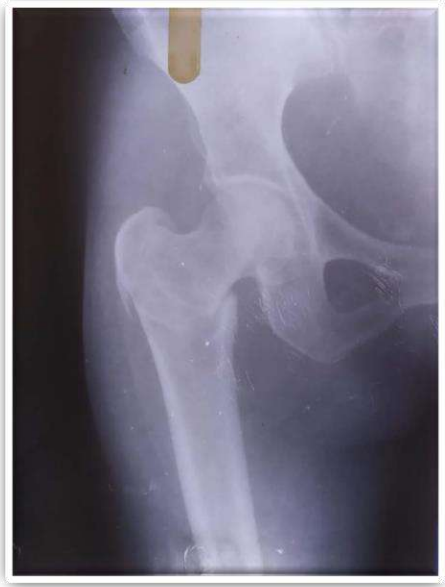

Post-Op.

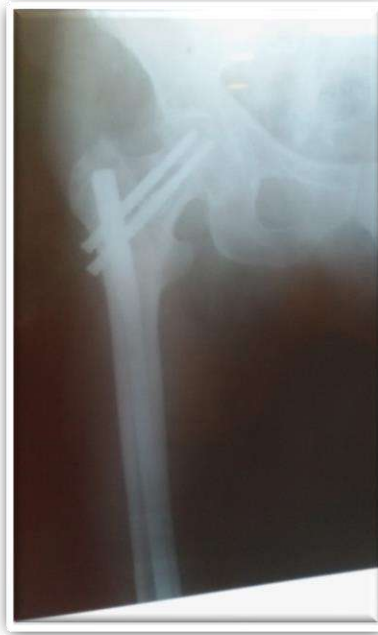16 weeks



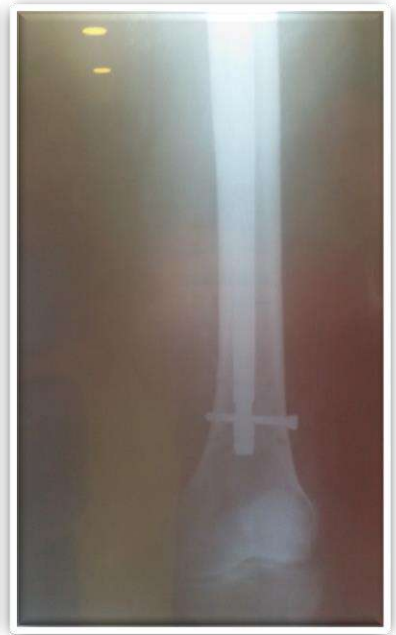### Case 4



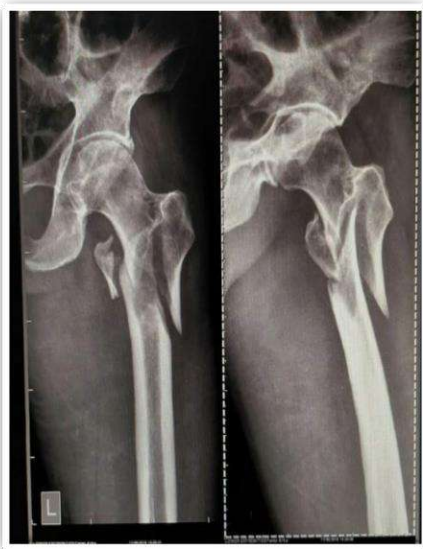Pre-Op.



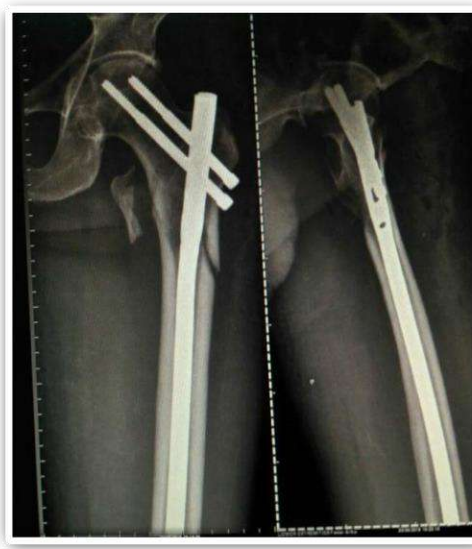Post-Op.



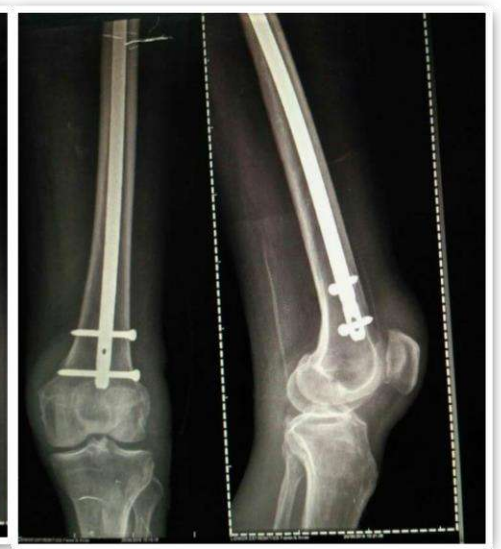### Case 5



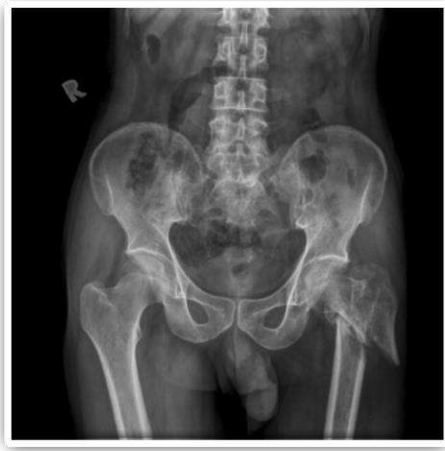Pre-Op.



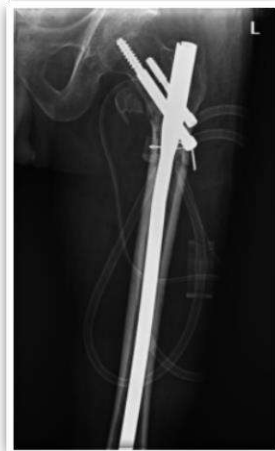Post-Op.



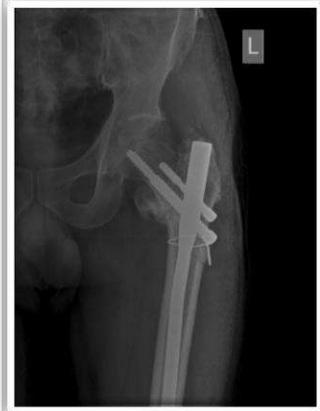## Case 6



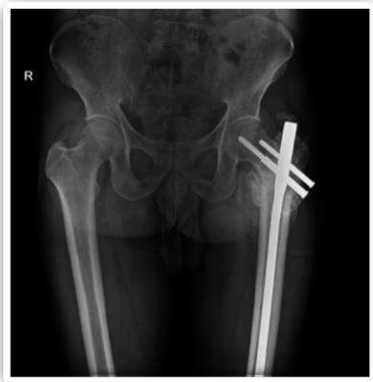Pre-Op.



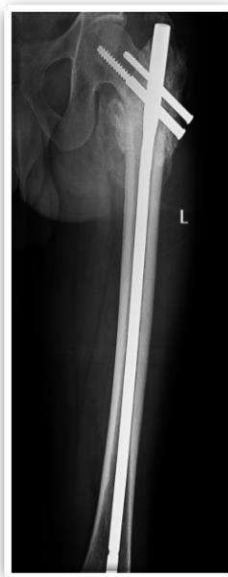Post-Op.



16 weeks



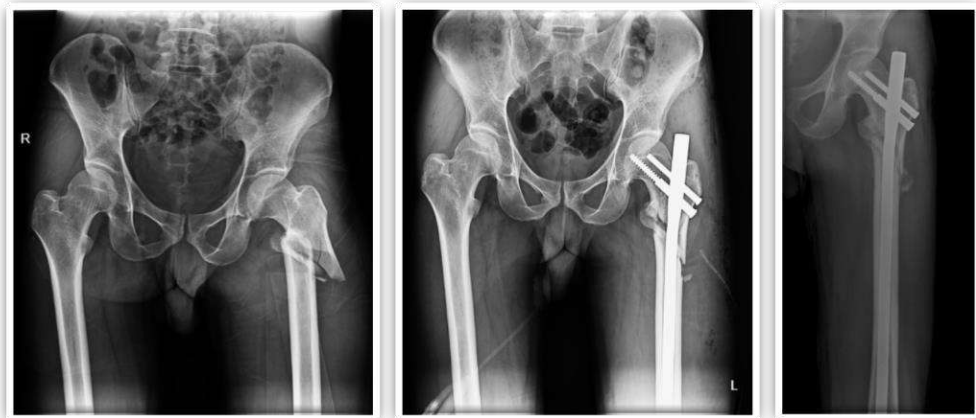6 months



12 months



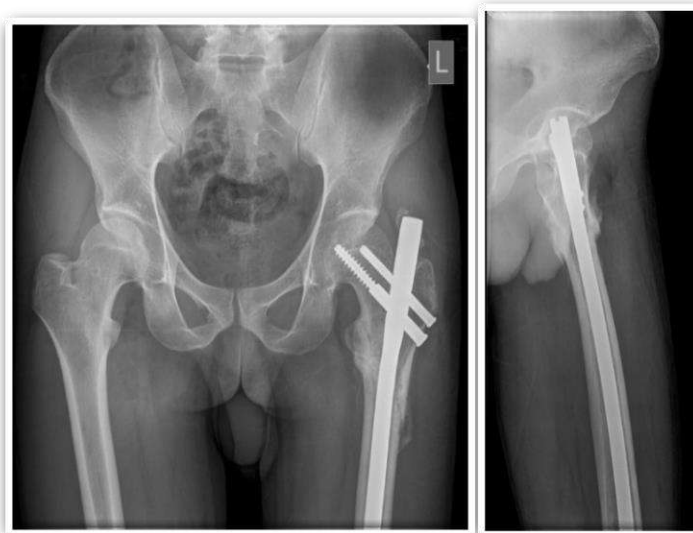
## Case 7



*Pre-Op*

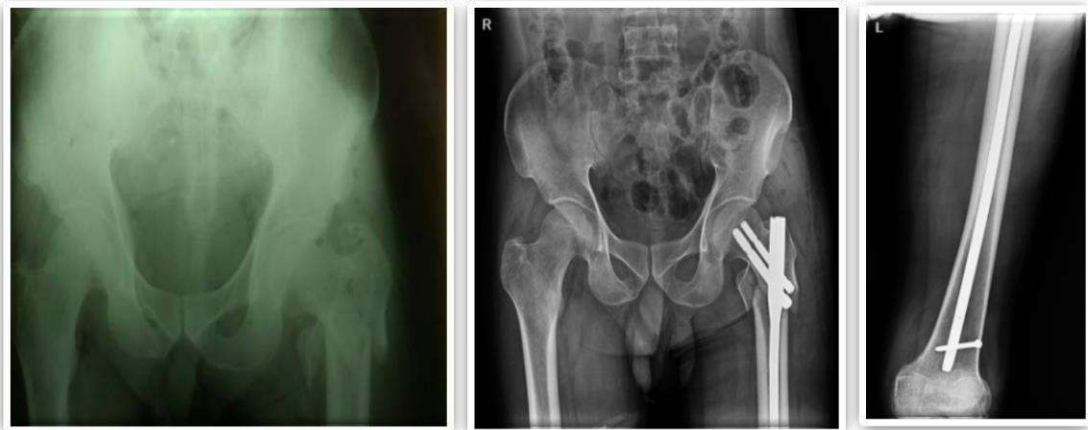*Post-Op.*

*8 weeks*



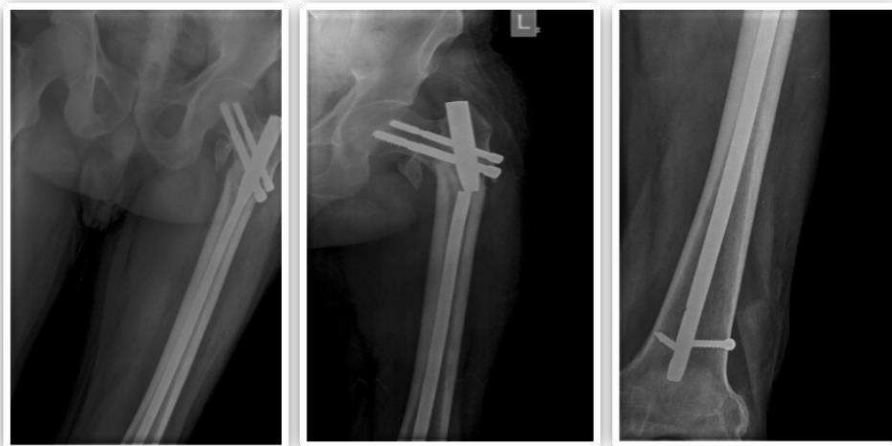*12 weeks*

## Case 8



*Pre-Op.*

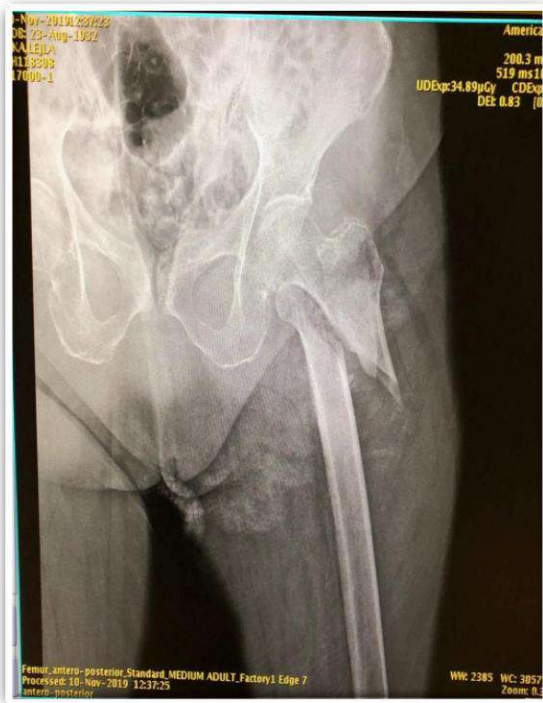
*Post-Op.*



*6 months*

*8 months*

## Case 9



*Pre-Op. & Post-Op.*

